

## Arthroscopic repair of complete tear of rotator cuff

Hamid Reza Aslani,<sup>1</sup>MD., Hamed Vahedi<sup>2</sup>, MD., Zohreh Zafarani<sup>3</sup>, MD.

*Department of Orthopedic Surgery, Shahid Beheshti University of Medical Sciences, Tehran, Iran.*

### Abstract

**Background:** Rotator cuff tear is one of the most common causes of shoulder complaints in the elderly. Based on the severity and patient's condition, a variety of methods applies to manage the tear and surgery is an important method, which could be done by open or arthroscopic technique. The current study aimed to investigate and report short-term results of arthroscopic repair of complete rotator cuff tears.

**Methods:** This was a cross-sectional study on 183 patients who underwent arthroscopic surgery to repair rotator cuff tear in three different hospitals of Tehran between January 2003 and August 2006. Of all patients, 107 cases included in our study, which had a complete rotator cuff tear, and at least one-year follow up record. 89 patients (56 male and 33 female) attended assessment sessions and were evaluated by UCLA (University of California, Los Angeles) Shoulder and Elbow Scoring System, pre- and post-operatively, and acromioplasty was performed in 83 patients.

**Results:** With a mean age of  $53.2 \pm 15.8$  (32-71) years, the average UCLA score was 11.3 before the surgery and 31.4 post-operatively. There were 11 patients with excellent scores, 62 good, 11 fair, and 5 poor scores. 9 out of 11 cases with excellent score and 34 out of 62 with good score were younger than 55 years; however, 13 cases were older than 60 years amongst 16 fair or poor scores.

**Conclusions:** Arthroscopic repair of complete rotator cuff tear would cause a significant improvement in a short-term period and results are better in younger patients, through the UCLA scoring system.

### Keywords

rotator cuff, arthroscopy, shoulder.

### Introduction

The rotator cuff is made up of four muscles, the supraspinatus, the infraspinatus, the subscapularis, and the teres minor which play an important role in shoulder's movement and its stabilization. Tearing and insufficiency in this complex may occur because of various causes and induces symptoms like pain, limited motion and arthropathy in long term. Most of pa-

tients with rotator cuff tearing complain of a gradual progressive shoulder pain radiating to deltoid region, which usually continues during night. Since tearing occurs in elderly most of the times, patients usually do not remember the onset of the problem and it usually alters to a chronic pattern [1].

There are various classifications of rotator cuff tearing, such as acute and chronic, traumatic and degenerative, complete and incomplete. It is usually recommended that non-surgical

1. **Corresponding author,** Assistant Professor of Orthopedic Surgery, Shahid Beheshti University of Medical Sciences. Orthopedic Department, Taleghani Hospital, Velenjak, Tehran, Iran. Tel: +9821 8864-2572. Email: hraslani@yahoo.com.

2. Orthopedic Surgeon and Medical Researcher.

3. General Practitioner and medical researcher.

treatment like palliative and physical therapy take place first; therefore, surgical methods are performed in non-responsive cases whose pain limited the movements or muscular weakness persists. Surgical operations carry out by open or arthroscopic techniques and recently with an increasing tendency is seen towards arthroscopic repair. Method of treatment is chosen by considering patient's age, activity, and type and extension of tearing. Debridement and decompression are performed in an extensive tear, which is not repairable [1].

Several articles reported that outcome of the surgical method has been satisfactory, especially in cases with limited tearing (2-3 cm), whereas there is no significant difference between open and arthroscopic repairs in long term results. An investigation by Ellman et al on arthroscopic management of rotator cuff tear with a follow up period of 1 to 5 years revealed that UCLA (University of California, Los Angeles) Shoulder Score and range of motion improved by 86% and 88%, respectively after the surgery; and also, strength of shoulder was not statistically increased [2].

Severud et al compared open (29 cases) and arthroscopic (35 cases) approaches to rotator cuff tearing and reported that long-term results were almost the same in the two groups, while lower ankylosis and fibrosis rates as well as earlier improvement in the range of motion were seen in arthroscopic repair [3]. Ide et al compared 50 cases of arthroscopic repair on the one hand and 50 cases of open repair on the other hand. The follow up period was at least 18 months and UCLA scoring system was applied. In small to moderate tear (less than 3 cm), there was 97% repair by arthroscopic technique and 94% by open procedure, whereas in extensive tear (more than 3 cm), 82.4% repaired by arthroscopic method and 76.9% by open surgery. In general, the difference between the two techniques was not significant; but the results of arthroscopic repair were satisfactory [1]. Lee et al reported that the arthroscopic repair of ro-

tator cuff tear could considerably improve the pain score and range of motion [5]. In a study by Ozbaydar et al, there was a significant improvement in UCLA score after the arthroscopic repair of rotator cuff tear. The mean for UCLA scores before and after the surgery was 11.7 and 30.4, respectively [6]. Finally, The surgical approach is recommended for patients with complete tearing of rotator cuff, active patients who need to be highly functional and patients who do not respond to non-surgical treatments to achieve pain relief, increasing range of motion and shoulder function [7,8].

In Iran, the arthroscopic repair of rotator cuff tear is a relatively new procedure whose outcome has not been studied yet. In this study, the arthroscopic repair of complete tearing of rotator cuff was investigated in a short-term follow up period of at least one year.

### Methods

This was a cross-sectional study on 183 patients who underwent arthroscopic surgery to repair rotator cuff tear in three different hospitals of Tehran (Taleghani, Milad, and Pars hospitals) between January 2003 and August 2006. Of the patients, 107 studied cases had a complete rotator cuff tear, and at least one-year follow up record. 89 patients (56 male and 33 female) were attended assessment sessions and evaluated by UCLA (University of California, Los Angeles) Shoulder and Elbow Scoring System to assess pain, joint strength, range of motion, and the patient satisfaction indices pre and post-operatively. In addition, all patients were studied by simple radiographs and MRI as well as regularly clinical exams follow up in at least one year after the surgery.

### *Surgical method*

Initially, diagnostic arthroscopy was performed via standard portal of arthroscopy in beach chair position. Primary evaluations of the shape and extent of tear and the range of motion were done. Acromioplasty was performed after

debriding edges of the tear. Impingement syndrome commonly takes place concurrently with rotator cuff tear; hence, acromioplasty is a necessary part of the surgical management to reduce pain and prepare an appropriate anatomic cradle for the repaired tendon. On the other hand, acromioplasty is not usually needed in young patients with traumatic tears or in cases with no disorder in subacromial space.

Some cases underwent subacromial decompression followed by tearing repair with metallic or absorbable anchor sutures, based on the shape of tears (C, L, or U shapes) (Fig. 1).

The arm was fixed in a sliding for 6 weeks after the surgery, along with the elbow, wrist, and fingers. Gentle passive forward Flexing and external rotating of the shoulder were performed as a routine in this period. We instructed the patients to actively move the joint after 6 weeks in a certain range, except for abduction, as well as strengthening the deltoid muscles and rotator cuff, along with full movement of the joint after 12 weeks.

## Results

The mean age was 53.2 years (32 - 71 years); the mean UCLA score was 11.3 before the surgery and 31.4 one year after the surgery. Out of 183 cases with an arthroscopic approach to the rotator cuff tear, 107 patients had a complete tear, and amongst them, only 89 studied cases had a regular follow up record.

MRI study was performed in all the patients before the surgery, which demonstrated complete tearing in 73 (82%) patients, incomplete tearing in 14 cases and no tearing in just 2 cases. However, there were 89 patients with complete tearing for arthroscopic evaluation and acromioplasty was done on 83 (93.2%) patients.

Based on the UCLA scoring system, the results were classified into 11 excellent, 62 good, 11 fair, and 5 poor outcomes. The ages of the patients with good result were under 55 years in 34 cases (47%) and below 60 in 63 patients

(87%). Conversely, of 16 patients with fair or poor results, 13 (84%) patients had an age of 60 years or more. Comparing the UCLA scores before and after the surgery revealed that the outcomes were good and excellent in 73 (87%) patients. The maximum pain relief was achieved in 77 (87%) patients. The least improvement belonged to forward flexion strength with the rate of 59 percent.

## Discussion

The arthroscopic repair of complete tearing of rotator cuff resulted in a considerable improvement of UCLA score in most of our patients. 82% of the patients achieved excellent and good results, which is comparable with the results of recent studies. In the study by Ellman et al, 86% of patients were satisfied with the surgery, which is similar to our results, while the number of our cases was two times theirs. Other studies showed a similar outcome [2]. To compare with Ide's report, the present study investigated more cases with less follow up period; however, the UCLA scores obtained from both of them were almost the same. In Ide's study, the difference between the results of arthroscopic and open surgeries was not significant [4]. In this study however, the comparison was not carried out, because all cases had requested an arthroscopic management.

Fair and poor results in 16 patients might be due to diverse factors like old age, extent of tearing, inadequate decompression, and tendon quality as well as background diseases like rheumatoid arthritis. Investigating these possible risk factors is an important subject in further researches. The probable reason of the remarkable undiagnosed rate of complete tearing by MRI (about 20%), might be due to the lack of experience of radiologists in this specific field. Nonetheless, these imaging studies were carried out in different centers, which resulted in various reports by different radiologists.

Compared to previous studies, the current research was performed on a larger number of

cases. Previous studies [3,4] reported that the results of open surgery and arthroscopic repair were not significantly different in a long-term evaluation. As it was mentioned, in Severud's study, lower fibrosis and ankylosis as well as earlier start for improving the range of motion were seen in the cases with arthroscopic repair [3]. Pain was the main symptom of the patients and our results found a considerable improvement in pain and the joint function along with a relatively improvement in the strength and range of forward flexion. Even the maximum pain relief was considerably higher when compared to similar studies.

It could be concluded that arthroscopic repair of complete rotator cuff tear currently achieved very good results in our country; hence, this technique is recommended in managing complete tear if the patient is elected properly and the surgeon has enough skill. It seems that with adequate expertise in performing arthroscopic repair, and considering its advantages, this procedure could be a proper substitute for open surgery of rotator cuff tear.

## References

1. Frederick M. Shoulder and elbow injuries. In: Canale ST, editor. *Campbell's Operative Orthopedics*. 10th edition. Philadelphia: Mosby 2003; p 2344-9.
2. Ellman H, Kay SP, Wirth M. Arthroscopic treatment of full-thickness rotator cuff tear: 2 to 7 years follow up study. *Arthroscopy* 1993;9(2):195-200.
3. Severud EL, Routolo C, Abbott DD, Nottage WM. All Arthroscopic versus mini-open rotator cuff repair: A long term retrospective outcome comparison. *Arthroscopy* 2003;19 (3):234-8.
4. Ide J, Maeda S, Takagi K. A comparison of arthroscopic and open rotator cuff repair. *Arthroscopy* 2005; 21(9):1090-8.
5. Lee E, Bishop JY, Braman JP, Langford J, Gelber J, Flatow EL. Outcomes after arthroscopic rotator cuff repairs. *J Shoulder Elbow Surg* 2007;16(1):1-5.
6. Ozbaydar MU, Bekmezci T, Tonbul M, Turdogiu C. The results of arthroscopic repair in partial rotator cuff

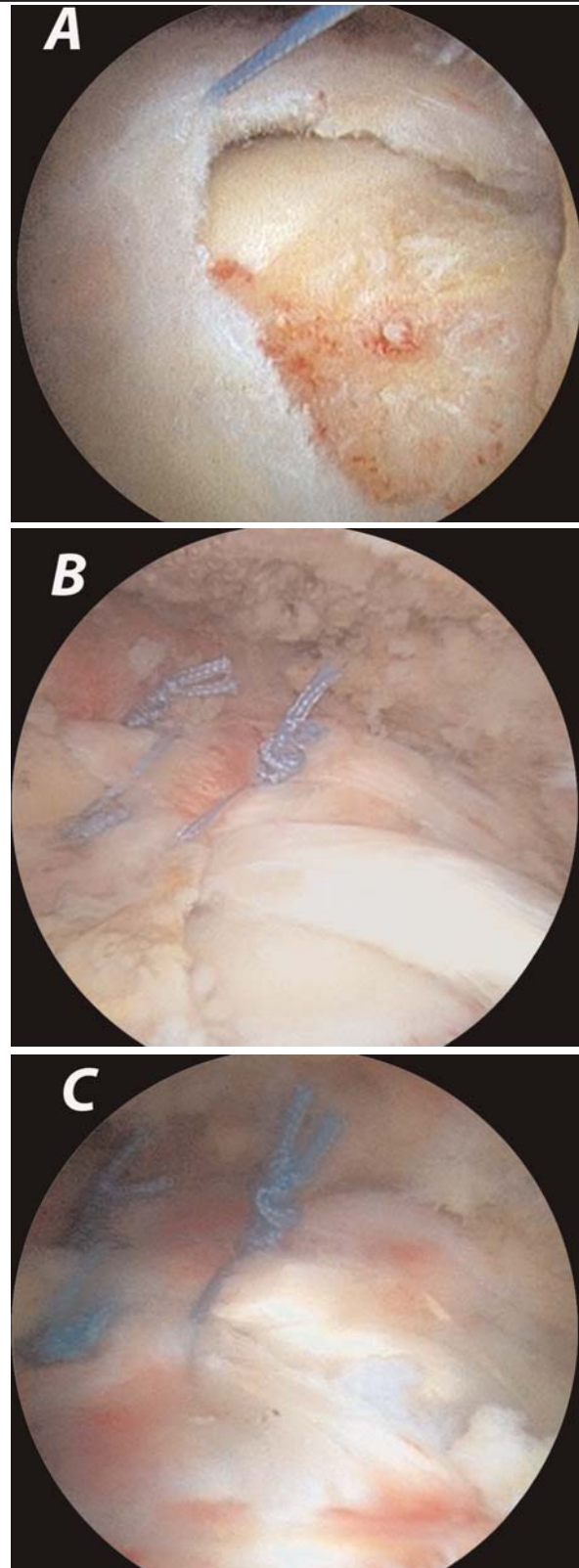


Fig.1. Arthroscopic repair of rotator cuff tear: A. before the procedure, B. after finishing the repair, and C. follow up arthroscopic evaluation.

rears. *Acta orthop Traumatol Turc* 2006; 40(1):49-55.

7. Burkhart SS, Lo IK. Arthroscopic rotator cuff repair. *J Am Acad Orthop surg* 2006; 14(6):333-46.

8. BakerCL, Whaley AL, Baker M. Arthroscopic rotator cuff tear repair. *J surg Orthop Adv* 2003;12(4):175-90.