

## A single posterior approach for vertebral column resection in adults with severe rigid kyphosis

Seyed Khodakaram Rastegar<sup>1</sup>, Maziar Azar<sup>2</sup>, Sayed Ali Ahmadi<sup>3</sup>

*Department of Neurosurgery, Tehran University of Medical Sciences and Health Services, Tehran, Iran.*

*Received: 4 May 2011*

*Revised: 11 July 2011*

*Accepted: 16 July 2011*

### Abstract

**Background:** Correction of severe kyphosis is a challenging operation in spinal surgery. A two stage operation has been commonly used: anterior release and decompression followed by posterior correction and fusion. We describe the posterior vertebral osteotomy technique for correction of severe and rigid kyphosis through posterior-only approach.

**Methods:** Twelve patients (six male and six female ) with severe and rigid kyphotic deformity of the thoracic spine were treated by posterior vertebral column resection using a single posterior approach. The apex level of kyphosis was at the upper thoracic in five patients, the lower thoracic in four patients and mid thoracic in three patients. There was old fracture in one patient, congenital deformity in six, tumor in three and neurofibromatosis in two patients. After posterior vertebral column resection, segmental posterior instrumentation was used for correction of the kyphotic deformity. Complications and radiographic findings were analyzed to evaluate clinical outcomes and radiologic changes of posterior vertebral column resection in patients with angulated kyphotic deformity.

**Results:** The major curve correction was averaged 31.66 ° (SD=15.69) (45%). The resection was performed at the involve level in every patient. Posterior segmental fusion was achieved in average 8.9 (SD=1.7) segments. Anterior reconstruction was with titanium mesh cage in two and with cancellous chip packing in other patients. There were no neurologic complications after six month. Bony fusion achieved in all patients, and there was no correction loss.

**Conclusion:** Satisfactory correction is safely performed by posterior vertebral column resection with a direct visualization of the circumferentially decompressed spinal cord. Although the performance is technically laborious, it offers good correction without jeopardizing the integrity of the spinal cord.

**Keywords:** kyphosis, posterior vertebral column resection, single posterior approach

### Introduction

Kyphosis is a deformity with fixed spinal vertebrae that does not allow traction and suspension of the spine. The lack of a mobile spine frequently results in early truncal decompensation and a large compensatory

curve, which may progress with time [1]. Rigid kyphosis in adults usually occurs with functional impairment and neurologic complications, and pain is a common symptom [2-4].

Severe kyphosis in adults remains as a big challenge for spine surgeons. Severe kypho-

1. Associate Professor of Neurosurgery, Department of Neurosurgery, Tehran University of Medical Sciences and Health Services, Tehran, Iran. dr.kh.rastegar@gmail.com

2. Associate Professor of Neurosurgery, Department of Neurosurgery, Tehran University of Medical Sciences and Health Services, Tehran, Iran. maziarazar@yahoo.com.

3. **(Corresponding author)**, Resident of Neurosurgery, Department of Neurosurgery, Tehran University of Medical Sciences and Health Services (TUMS), Tehran, Iran. Address: Rasool-e-Akram Hospital, Department of Neurosurgery, Tehran University of Medical Science, Tehran, Iran. ahmadi.sayedali@gmail.com.

sis results from many conditions, including the congenital kyphosis and kyphoscoliosis [5–6] post laminectomy kyphosis [7] trauma [8,9] granulomatous disease [10–11] bony dysplasias [12] rotational kyphosis or kyphosing scoliosis [13,14] and spinal tuberculosis has become a more common cause for severe kyphosis [15]. Neglected or untreated kyphosis curve can be severe and rigid and occasionally can result in compression of lung and abdominal structures.

Many authors have described anterior, posterior, and combined procedures in literature [9–15]. Here, we describe the posterior vertebral osteotomy technique for correction of severe and rigid kyphosis through posterior-only approach that does not deteriorate compromised lung functions and reduces the risk of neurologic injury and profuse intraoperative bleeding. The aim of this article was to introduce a new safe operative technique for severe kyphosis and to present results of our preliminary study in kyphosis.

### Methods

Between May 2007 and Jun 2008, 12 consecutive patients with rigid and severe kyphosis underwent a posterior-only PVCR by single surgeon at two institutions.

The clinical records were reviewed for demographic data, etiology of the lesion, functional improvement, and complications. Clinical outcome was measured with the SRS-24 preoperatively and at 2 years post-operation.

There were six males and six females; average age of 35.5 years (range 19–64 years). Etiologies of deformities are explained in Table 1. All patients had truncal imbalance before surgery in sagittal plane. Prior to surgery, three patients were presented with neurologic compromise, among them, two patients were presented with neurogenic claudication and one patient had radicular pain. In our patient group, there were seven patients with intractable back pain.

For spine flexibility assessment standard radiographic measurements were made from standing postero-anterior and lateral radiographs taken before surgery for assessment

flexibility of spine, 2 weeks after surgery, 2 years follow-up, and at most recent follow-up to examine deformity correction, spinal balance, complications related to the instrumentations, and any evidence of pseudarthrosis.

The sagittal balances preoperatively and at postoperative stages were measured as described by Glassman et al. [13]. Sagittal balance was measured as the distance between C7 plumb line and the posterior superior corner of S1. Kyphosis was measured by Cobb's method between the two most tilted vertebrae in the sagittal plane. The sagittal curves respectively evaluated by Cobb method. All patients undergone preoperative and 2 years follow-up VAS and SRS-24 scale test to analyze the function condition. They were also evaluated with preoperative full length spinal cord MRI for neurological abnormalities. In addition, we routinely obtained pulmonary function testing (PFT) for all patients before surgery and postoperatively.

### Surgical technique

All the surgeries were carried out by the senior author (K.R) using the method described below.

After general anesthesia, the patients were placed in prone position. The incision performed as a straight posterior midline. Following a subperiosteal dissection, the vertebrae between the uppermost and the lowest instrumented vertebrae were exposed to the tips of the transverse process. The dissection was then carried out laterally, exposing the ribs corresponding to the level of the vertebral column resection.

The facets included in the fusion levels were destroyed by inferior facetectomy and removal of the articular cartilage to promote intra-articular arthrodesis. For the ankylosed or fused posterior facet joints, no attempt was made to mobilize the joints at this stage.

Pedicle screw fixation was carried out using K-wires inserted at the presumed entry points and intraoperative radiograph controls.

Following insertion of the pedicle screws, they were connected on one side with a rod

contoured to the shaped of the deformity without any attempt at correction.

To maximize the effect of the resection, it was carried out at the apex of the deformity. The resection began with a removal of the posterior elements. Following a total laminectomy and bilateral total foraminal unroofing to expose the neural elements, the transverse process and the corresponding rib on the working side of the vertebral column (on the opposite side of the temporary rod) were removed to expose the lateral wall of the pedicle. The meticulous subperiosteal dissection was deepened following the lateral wall of the vertebral body until the anterior surface of the vertebral body was comfortably palpable. Under visual control, the pedicles and the lateral portion of the vertebral body were removed by using a small osteotome. In the thoracic spine, the rib heads were removed at this stage to allow complete resection of the lateral wall of the vertebral body and to allow untethered motion of the vertebral column. The vertebral body and the intervening discs were removed with egg shell osteotomy method that in a piecemeal fashion gradually towards the medial side and over to the other half of the vertebral body through the void created in the vertebral body, keeping a thin shell of bony posterior vertebral wall beneath the dural tube. The anterior walls were also removed in a piecemeal fashion, taking care to leave the soft tissue tube anterior to the vertebral bodies intact. Attempts were made to remove as much vertebral body and disc as possible at this stage, even across the midline, as it was safe to work with the posterior wall protecting the neural elements. When an adequate amount of vertebral body was removed, the entire posterior vertebral wall that was visible lateral to the dural tube was removed with an Epstein reverse-cutting curette and pituitary forceps. Following the resection of the posterior wall on the working side, another temporary rod, contoured to the shape of the deformity, was inserted to the working side and securely locked to the screws. Then the rod on the other side was removed to allow resection on that side. The

same procedure was carried out on the opposite side. In resection of thoracic vertebrae, the thoracic nerve root on the working side was cut to facilitate resection of the body and reconstruction of the anterior column, but the opposite-side nerve root was saved. In lumbar vertebrae, the nerve roots on both sides were kept intact. At the completion of the resection, the rod that had been removed was replaced and connected to the screws on both sides. It was followed by the final check that the canal was clear of any residual compression at the resection margins and redundant bony or disc tissue attached to the anterior side of the dura that might hinder free, untethered movement of the dural tube.

Deformity correction was carried out either by in situ rod bending or by exchanging the temporary rods with those precontoured to the desired (corrected) shape one by one, and extension of the operating table was unnecessary. The precontoured rod was advantageous in reducing the operative time and the screw failures from force concentration of a specific screw. To avoid inadvertent distraction of the neural elements, the vertebral column was initially shortened by slight compression over the resected gap without tight locking of temporary rods. The deformity was gradually corrected with the repeated additional compression and shortening of the vertebral column. The compression and shortening over the resected gap was carried out until the exposed cord looked redundant. The compression and shortening over the resected gap could be symmetrical. Then, the temporary rods were changed to precontoured final rods one by one to avoid any loss of shortening of the resected gap.

Anterior fusion or circumferential fusion across the resection gap was carried out, and posterior fusion was performed at all instrumented levels. For anterior fusion at the resected area, autogenous cancellous chip bone graft or titanium cage was used. After resection and deformity correction, the height of the anterior interbody gap was measured. If the shortest height was less than 5 mm, autogenous cancellous chip bone placed into the anterior gap. If the height

was more than 5 mm, titanium cage filled with bone chip inserted into the anterior gap, and autogenous iliac chip bone was placed around the titanium cage. Titanium cage was more convenient than autogenous tricortical strut to readjust the size of the interbody graft several times. The mesh cage was inserted from the posterolateral side, through the space between the nerve roots, to fit on the proximal and distal bone bases. The additional compression over the cage was carried out to lock it into place. Bilateral posterior bridging bone graft over the resection gap was done in the thoracic level for the circumferential fusion. To confirm the absence of impingement a final circumferential check of the exposed dura was performed and final implant security documented. Posterior decortications and autologous bone graft obtained from the vertebrectomy was placed over the instrumented levels.

After bone graft two closed suction drains were inserted at the resection site, and the surgical wound was closed layer by layer. The patients were allowed to sit up in bed for 24 hours after the surgery. Patients were allowed out of bed with a brace at the second postoperative day, and the brace was kept for 3 months.

## Results

In total, 14 vertebrae were removed from 12 patients, with 1.16 (SD=0.38) vertebrae

being removed on average in each case with fusion levels of 8.25 (SD=1.7) and (range 7–113). The mean for major curve correction was 31.66 ° (SD=15.69) (45%). The resection was performed at the upper thoracic level in five patients and at the lower thoracic level in four patients and mid thoracic level in three patients. Anterior reconstruction was done with titanium mesh cage in two and with cancellous chip packing in five patients (Table1).

The average follow-up was 26 (SD=1.8) months, ranging from a minimum of 20 months to a maximum of 27 months.

At the final follow-up, fusion appeared solid in the standing anteroposterior and lateral radiographs in all cases. Loss of correction was minimal at the 20 months follow-up (Figs.1, 2, 3).

Only one patient with severe kyphosis showed signs of neurologic injury (paraparesia) after surgery which was reversed completely within six months period. No other serious perioperation complications, such as vascular, visceral or neural injury, occurred. There was no case of post-operative wound infection, screw loosening, or implant failure.

## Discussion

Severe rigid kyphosis, congenital, traumatic, infectious conditions and other has been a persistent and perplexing problem. The operative or nonoperative treatments

Table1– Summery of the Patients Data

Patient	Gender	Age (year)	Resection segment level	Instrumented vertebrae	Pre operation cobb angle	Post operation cobb angle	Correction (%)	Additional diagnosis	Prior Surgery
1	F	27	T11-T12	T5-L3	114	64	50(44%)	NF	Yes
2	F	30	T12	T9-L4	70	35	35(50%)	congenital	No
3	M	25	T12	T8-L5	80	38	42(52.5%)	congenital	No
4	F	64	T12	T8-L5	75	42	33(44%)	Old Fx	No
5	F	19	T1	C3-T5	65	35	30(46.1%)	congenital	No
6	M	49	T6	T3-T10	60	28	37(53.3%)	Tumor	No
7	M	30	T1	C5-T4	62	35	27(43.4%)	congenital	No
8	F	24	T1-T2	C2-T6	130	40	90(69.2%)	NF	Yes
9	M	21	T12	T8-L4	72	32	40(55.5%)	Congenital diplocord	NO
10	F	22	T1	C5-T4	56	30	26(46.4%)	congenital	No
11	M	60	T6	T3-T11	75	60	15(20%)	Tumor	No
12	M	55	T9	T2-L3	85	70	15(17.6%)	Tumor	No
average		35.5	1.16	8.9			31.66 (45.1)%		

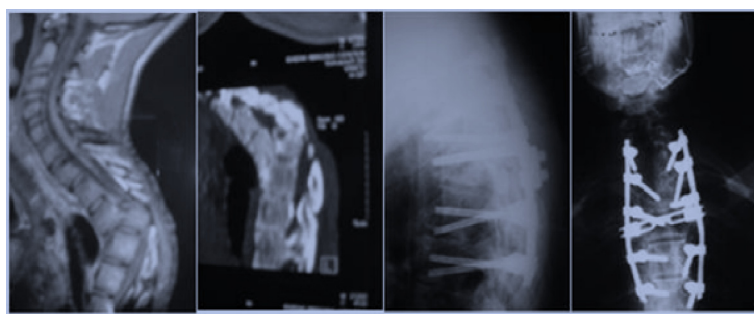


Fig. 1. Preoperation and post operation imaging of case 1.

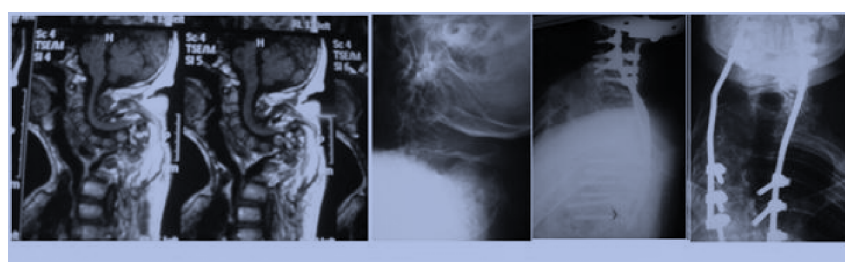


Fig. 2. Preoperation and post operation imaging of case 2.

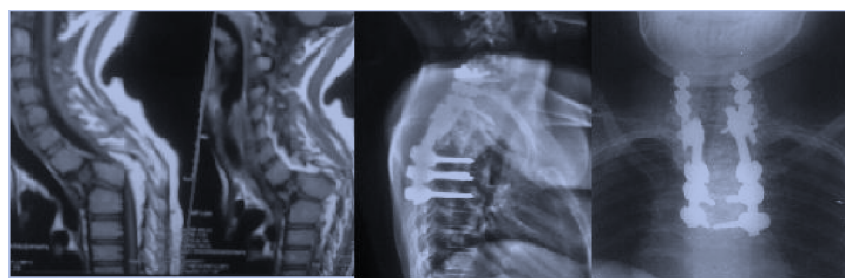


Fig. 3. Preoperation and post operation imaging of case 3.

often fail; various techniques have been described to treat the severe kyphosis treatment [16-19].

A sequential, multistage procedure has described anterior spinal osteotomy and decompression of the spinal cord, gradual spinal distraction, posterior osteotomy and fusion, additional spinal distraction, and anterior spine fusion after maximum correction [9]. Despite of the volume of surgery, there was only 28% morbidity with this technique and a 10% mortality rate. [20] Recently, a single-stage posterior osteotomy or VCR has become increasingly popular as it provides significant correction while minimizing the risk of injury to anterior vascular and visceral structures. Posterior osteotomy surgeries typically are of either the Smith-Petersen osteotomy (SPO) [5] or the pedicle subtraction osteotomy (PSO) [21]. However, a SPO

requires a mobile disc space anteriorly, and it is not frequently presented with the rigid deformity of an extremely severe kyphosis [22]. A PSO could be applied to patients with sharp, angular kyphosis and anterior column fusion [6]. Nevertheless, the excessive shortening of the area variable for the cord can be dangerous with a PSO and authors have recommended limiting the correction to 30–40° [24].

Therefore, neither the SPO nor a PSO would be suitable to correct a severe kyphotic deformity with a Cobb angle beyond 90°. Indication of VCR has emerged as popular means to correct severe, rigid kyphosis with fixed trunk translation [24]. Traditional VCR through a single-stage anterior–posterior approach is a challenging procedure, with a great risk of major complications vascular and neurological injuries. In

presence, Suk et al. developed a single posterior vertebral column resection (PVCR) aimed at reducing both operative time as well as complications [25]. The PVCR has been offered to produce correction up to 47.5° in the sagittal plane. The posterior elements were resected to remove the rib head articulation. Anterior vertebral body was subperiosteally exposed, dissected, and compressed for shortening correction by instrumentation. In their series, mean operation time was 4 h 31 min with average blood loss of 2,333 ml. The deformity correction was 45.2% in the sagittal plane or 53–55% improvement in sagittal imbalance [15,26]. Complications were encountered in 24 patients (out of 143 cases): two complete cord injuries in severe adult scoliosis and thoracic kyphosis patient who had significant preoperative cord compromise, six hematomas, four root injuries (all incomplete), five fixation failures, two infections, and five hemopneumothoraxes [25]. Since then, the PVCR method became more popular and widely accepted for correction of kyphosis deformity of spine. With this method, the resection of the vertebra was preceded from lateral to medial, working through the space created by the resection but not proceeding past the midline. Kawahara et al. [9] further modified the procedure by inserting an interbody cage through the posterior approach improving correction further. However, the remaining select situations of PVCR still cannot provide adequate correction.

Although, for severe rigid kyphosis in adults single-level PVCR often could not fulfill the task of satisfactory deformity correction. But multilevel PVCR was extensive and aggressive with longer operating time, greater amount of blood loss, and with higher risks of complications [27,28]. In the 1970s, Heinig developed the “eggshell” procedure, a technique to allow anterior decompression and posterior fusion through a posterior transpedicular approach [29]. The “eggshell” procedure is a salvage technique reserved for complex reconstructive problems in the treatment of acute trauma, de-

formity, tumor, or infection. The goal of the Heinig’s procedure [30] was to achieve similar deformity correction, neural decompression, and stabilization with fewer complications. The eggshell technique encompasses procedures ranging from simple transpedicular decompression and posterior fusion to more complex procedures, including transpedicular vertebrectomy and strut-grafting or pedicle subtraction (closing wedge) osteotomy with posterolateral fusion [31,32,23]. The key point of operation includes beginning with smaller curettes and gradual decancellation through the pedicle. Progressively larger curettes were then used, with care to preserve the medial pedicle wall and posterior wall of the vertebral body. Thus the transverse process could be removed and exposed to the lateral pedicle wall. Curettage is carried out across the midline and cephalad through the adjacent disc space. After completing decancellation, the medial pedicle wall is removed followed by the posterior wall using down-going bone tamps. Several authors have reported high success rates with the eggshell procedure for the treatment of spine deformity and trauma [31, 33, 29, 34].

A potential complication with vertebral resection is neurologic injury, either radicular or due to the spinal cord injury. Various reasons for this exist, including direct injury to the cord or dural compression from spinal canal misalignment, or possibly a vascular injury. Increased correction and shortening of the spine, dural buckling will occur and can cause injury to the canal contents. This study was not designed to investigate the effects on canal contents with closing of vertebral resection, and we therefore cannot comment on the relative risk to neurologic structures. Further study is needed to investigate the effect of these structures, but this would require whole intact spines with neural elements in a fresh environment with spinal fluid such that the behavior of the more elastic spinal cord and cauda equina is similar to that in living patients. Our study was limited somewhat by accomplishing of a relatively small group of patients, for further evalua-

tion of this techniques efficiency and improvement of technique, a study of a larger group of patients with the set of control group, such as PSO, PVCR, would be necessary. This procedure was technically demanding and should be done by an experienced team of surgeons. The risk of neurological complication should also be seriously considered, which makes it important to select the appropriate surgery candidate.

## Conclusions

The encouraging results of this study indicate that correction of kyphosis caused by a vertebral resection can be effectively corrected by a one-stage posterior resection and correction using segmental posterior instrumentation. The operation was safe, and no associated adverse complications were noticed. This procedure is best indicated for adolescent patients with a structural kyphotic deformity.

## References

1. Winter RB, Moe JH, Eilers VE Congenital scoliosis: a study of 234 patients treated and untreated. *J Bone Joint Surg Am* 1968; 50:1-47.
2. Danisa OA, Turner D, Richardson WJ Surgical correction of lumbar kyphotic deformity: posterior reduction "eggshell" osteotomy. *J Neurosurg* 2000; 92(suppl 1):50-56.
3. McMaster MJ, Ohtsuka K. The natural history of congenital scoliosis: a study of two hundred and fifty-one patients. *J Bone Joint Surg Am* 1982; 64:1128-1147.
4. McMaster MJ, Singh H Natural history of congenital kyphosis and kyphoscoliosis: a study of one hundred and twelve patients. *J Bone Joint Surg Am* 1999;81:1367-1383.
5. Smith-Peterson MN, Larsen CB, Aufranc OE. Osteotomy of the spine for correction of flexion deformity in rheumatoid arthritis. *J Bone Joint Surg Am* 1945; 27:1-11.
6. Halm H, Metz-Stavenhagen P, Zielke K. Results of surgical correction of kyphotic deformity of the spine in ankylosing spondylitis on the basis of the modified arthritis impact measurement scales. *Spine* 1995;20: 1612-9.
7. Berven SH, Deviren V, Smith JA, et al. Management of fixed sagittal plane deformity: results of the transpedicular wedge resection osteotomy. *Spine* 2001;26: 2036-43.
8. Willems KF, Slot GH, Anderson PG, et al. Spinal osteotomy in patients with ankylosing spondylitis: complications during first postoperative year. *Spine* 2005; 30:101-7.
9. Kawahara N, Tomita K, Baba H, et al. Closing-opening wedge osteotomy to correct angular kyphotic deformity by a single posterior approach. *Spine* 2001; 26:391-402.8
10. Danisa OA, Turner D, Richardson WJ Surgical correction of lumbar kyphotic deformity: posterior reduction "eggshell" osteotomy. *J Neurosurg* 2000; 92(suppl 1):50-56.
11. Lehmer SM, Keppler L, Biscup RS, et al. Posterior transvertebral osteotomy for adult thoracolumbar kyphosis. *Spine* 1994; 19:2060-7.
12. Law WA. Osteotomy of the spine. *J Bone Joint Surg Am* 1962; 44:119-26.
13. Li F, Sagi HC, Liu B, et al. Comparative evaluation of single-level closingwedge vertebral osteotomies for the correction of fixed kyphotic deformity of the lumbar spine: a cadaveric study. *Spine* 2001; 26: 2385-91.
14. Lio Cx, Xu Dy, Hang HG, Zheng ZM. Observation of the short term therapeutic effectiveness of body Gamma knife in 48 patients with advanced pancreatic carcinoma. *Chi Med J* 2005; 27(5):637-9.
15. Pappou IP, Papadopoulos EC, Swanson AN et al Pott disease in the thoracolumbar spine with marked kyphosis and progressive paraplegia necessitating posterior vertebral column resection and anterior reconstruction with a cage. *Spine* 2006; 31:E123-E127.
16. Kwon BK, Elgafy H, Keynan O, Fisher CG, Boyd MC, Paquette SJ, Dvorak MF Progressive junctional kyphosis at the caudal end of lumbar instrumented fusion: etiology, predictors, and treatment. *Spine* 2006; 31(17):1943-1951.
17. Macagno AE, O'Brien MF Thoracic and thoracolumbar kyphosis in adults. *Spine* 2006; 31(19 suppl):S161-S170.
18. Qi X, Matsumoto M, Ishii K, Nakamura M, Chiba K, Toyama YPosterior osteotomy and instrumentation for thoracolumbar kyphosis in patients with achondroplasia. *Spine* 2006; 31(17): E606-E610.
19. Yang BP, Ondra SL, Chen LA, Jung HS, Koski TR, Salehi SA Clinical and radiographic outcomes of thoracic and lumbar pedicle subtraction osteotomy for fixed sagittal imbalance. *J Neurosurg Spine* 2006; 5(1):9-17.
20. Rajasekaran S The problem of deformity in spinal tuberculosis. *Clin Orthop Relat Res* 2002; 398:85-92.
21. Thomassen E Vertebral osteotomy for correction of kyphosis in ankylosing spondylitis. *Clin Orthop Relat Res* 1985;194:142-152.
22. Jain AK, Aggarwal PK, Arora A et al. Behavior of the kyphotic angle in spinal tuberculosis. *Int Orthop* 2004; 28:110-114.
23. Bridwell KH. Decision making regarding

Smith-Petersen vs. pedicle subtraction osteotomy vs. vertebral column resection for spinal deformity. *Spine* 2006; 31:S171–S178.

24. Justin SS, Vincent YW, Christopher PA Vertebral column resection for rigid spinal deformity. *Neurosurgery* 2008; 63:A177–A182.

25. Suk S, Kim JH, Kim WJ Posterior vertebral column resection for severe spinal deformities. *Spine* 2002; 27:2374–2382.

26. Suk SI, Chung ER, Kim JH Posterior vertebral column resection for severe rigid scoliosis. *Spine* 2005; 30:1682–1687.

27. Bradford DS, Tribus CB (1997) Vertebral column resection for the treatment of rigid coronal decompensation. *Spine* 22(14):1590–1599.

28. Bridwell KH, Lewis SJ, Edwards C, Lenke LG, Iffrig TM, Berra A, Baldus C, Blanke K Complications and outcomes of pedicle subtraction osteotomies

for fixed sagittal imbalance. *Spine* 2003; 28 (18): 2093–2101.

29. Gertzbein SD, Harris MB Wedge osteotomy for the correction of posttraumatic kyphosis. *Spine* 1992;17:374–379.

30. Heinig CA Eggshell procedure. In: Luque ER (ed) *Segmental spinal instrumentation*. Slack, Thorofare, 1984; pp 221–230.

31. Baba H, Maezawa Y, Kamitani K et al. Osteoporotic vertebral collapse with late neurological complications. *Paraplegia* 1995; 33:281–289.

32. Bridwell KH Causes of sagittal spinal imbalance and assessment of the extent of needed correction. *Instr Course Lect* 2006; 55:567–575.

33. Bradford DS, Boachie-Adjei O One-stage anterior and posterior hemivertebral resection and arthrodesis for congenital scoliosis. *J Bone Joint Surg Am* 1990; 72:536–540.