



## Expression of Cytokeratin 19 in the epithelial cell of Azo-exposed buccal mucosa

Juni Handajani<sup>1\*</sup>, Lisdrianto Hanindriyo<sup>2</sup>

Received: 8 Aug 2017

Published: 16 Mar 2018

### Abstract

**Background:** Azo is a synthetic dye used in batik industries. It can be toxic to the tissue when exposed via inhalation, swallowing, or direct contact. Expression of cytokeratin will change in hyperplastic and cancer of the oral mucosa. Expression of Cytokeratin 8, 18, 19 is strong in the epithelial cells that undergo excessive hyperproliferation and oral mucosal changes in leukoplakia and squamous stratification carcinoma. The present study was conducted to analyze the expression of Cytokeratin 19 in the epithelial cells of azo-exposed buccal mucosa.

**Methods:** A total of 30 males were divided into 2 groups of azo-exposed and controls equally. Criterion for azo-exposed participants was working at batik coloring division for at least 5 years, while the controls were the ones who were not exposed to azo dyes. Exfoliative cytology using cytobrush was the method of collecting buccal mucosal epithelial cells. Expression of Cytokeratin 19 was analyzed using Cytokeratin 19 monoclonal antibody and immunohistochemical staining. Data were analyzed using independent samples t test in SPSS 13.0 software.

**Results:** There was a negative expression on the controls, while positive expression was observed in the exposed group. T test analysis showed significant differences ( $p < 0.001$ ) in the positive expression of the exposed group ( $97.600 \pm 2.063$ ) compared to controls ( $3.133 \pm 1.641$ ).

**Conclusion:** Azo dye could increase the expression of Cytokeratin 19 on buccal mucosa epithelial cells.

**Keywords:** Buccal mucosa, Cytokeratin 19, Epithelial cell, Exposed-azo dye

Copyright © Iran University of Medical Sciences

**Cite this article as:** Handajani J, Hanindriyo L. Expression of Cytokeratin 19 in the epithelial cell of Azo-exposed buccal mucosa. *Med J Islam Repub Iran.* 2018(16 Mar);32:23. <https://doi.org/10.14196/mjiri.32.23>

### Introduction

Cytokeratin (CK) is a protein that contains keratin intermediate filaments. This protein serves as a component of the cytoskeleton and the cell contact (desmosome and hemidesmosome) in epithelial tissues. The products of each gene family cytokeratin are divided into neutral or basic type II cytokeratin (numbers 1-8) and acidic type I cytokeratin (numbers 9-20). Cytokeratin is usually found in pairs, and type I has a shorter size. Cytokeratins 1 and 10 are found in suprabasal layers of masticatory mucosa.

Mucosal lining is mainly suprabasal keratinocytes stained for CK 4 and 13. In the epithelium lining, the soft palate expresses CK 7, 8, and 18 (1-2).

The role of cytokeratin is to protect the epithelial cells from the mechanical and non-mechanical pressure (stress), which result in cell death. In addition, cytokeratin also gives a signal when a cell responds to stress, apoptosis, and other specific functions. Several diseases in humans are thought to be associated with the involvement of cy-

**Corresponding author:** Dr Juni Handajani, [junihandajani@ugm.ac.id](mailto:junihandajani@ugm.ac.id)

<sup>1</sup> Department of Oral Biology, Faculty of Dentistry, Universitas Gadjah Mada, Indonesia.

<sup>2</sup> Department of Preventive and Community Dentistry, Faculty of Dentistry, Universitas Gadjah Mada, Indonesia.

#### ↑What is “already known” in this topic:

The differentiation pattern of human oral mucosa can be described by cytokeratin expression. Expression of Cytokeratin 19 was very strong in suprabasal cell layer of the epithelium; it may correlate with premalignancy or hyperproliferation in chronic inflammation. In batik industry, azo can irritate the skin, eyes, and cause harm to the respiratory system.

#### →What this article adds:

This study found that exposure to azo may affect changes in the pattern of cell differentiation in the buccal mucosa of batik workers. The expression of Cytokeratin 19 in the azo-exposed epithelial cells of the buccal mucosa can be used as an early detection indicator of a change in the pattern of cell differentiation.

keratin. Recently, cytokeratin has been widely used as a tumor marker for histodiagnosis and management of certain cancers. Expression of cytokeratin can describe the differentiation of epithelial cells (1-3).

The differentiation pattern of human oral mucosa can be described by cytokeratin expression. Cytokeratin expression of epithelial stratification is best illustrated in human oral mucosa. Cytokeratin expression varies depending on the areas of the oral mucosa, showing differences in the level of differentiation and keratinization. Normal pattern of cytokeratin expression will change in hyperplastic and cancerous lesions of the oral mucosa (2).

The pattern of expression of Cytokeratin 8, 18, and 19 are most commonly found in malignant states (4). Expression of Cytokeratin 19 is very strong in suprabasal cell layer of the epithelium, and it may correlate with premalignancy or hyperproliferation in chronic inflammation (5).

Synthetic dyes on the batik industry is made from azo compounds, which are derivative substances of benzene. Azo in the batik industry can irritate the skin, eyes, and cause harm to the respiratory system (6). Azo compound can be a source of disease in the environment due to its carcinogenic and mutagenic nature (7-8). Thus, the present study aimed at evaluating the expression of Cytokeratin 19 on the epithelial cells of the azo-exposed buccal mucosa.

## Methods

### Participants and study design

The study involved 30 males, with an age range of 18 to 40 years, who were placed into 2 groups. The score of Simplified Oral Hygiene Index (OHI-S) of the participants was good. There were 15 azo-exposed participants from Yogyakarta batik home industry coloring division, and there were 15 non-azo-exposed participants as controls. Informed consent was obtained from each participant according to Helsinki II declaration.

**Intervention and assessment:** The study procedures were approved by the ethics committee of the Faculty of Dentistry, Universitas Gadjah Mada (Ethical clearance No.: 00586/KKEP/FGK-UGM/EC/2016) on March 15, 2016. Participants were asked to rinse their mouth prior to the examination to remove debris from their oral cavity. Buccal epithelial cells were swabbed using cytobrush moistened with 0.09% NaCl. The epithelial cell of buccal mucosa was then swabbed on poly-L-lysine glass object. Fixation was done on the preparations using a solution of methanol-acetic acid (3:1) and made fresh before use. Fixation was intended to prevent autolysis as well as maintain the component of cell element. Glass object was completely dried.

**Immunohistochemical staining:** Samples were incubated for 5 minutes in 1% hydrogen peroxide diluted in methanol to quench endogenous peroxidase activity, then, they were washed with PBS 3 times, for 5 minutes each time. The procedure was then performed using 1.5% normal blocking serum with phosphate buffered for 20 minutes. Then, the samples were washed using PBS 3 times, for 5 minutes each time. Primary antibody Cytokeratin 19

(RCK108, Novus Biologicals, USA) was diluted 1:500 in PBS. Samples were incubated in primary antibody for 24 hours at 4°C, then, they were washed using PBS 3 times, for 5 minutes each time.

Samples were stained using immunohistochemical method (Mouse ABC Staining System sc-2017, ImmunoCruz, Santa Cruz Biotechnology, USA). Samples were incubated using a secondary antibody for 20 minutes in room temperature. The procedure was followed by immersion in a buffer substrate for 20 minutes in room temperature.

Diaminobenzidine (DAB) staining was used for around 20 minutes. The appearance of brown color reflects a positive result on both nuclear and cytoplasmic cells. Samples were observed using a light microscope with 600 times magnification, and a computer monitor with a magnification of 100 times. At least 100 epithelial cells were collected from each sample. Observation was done by counting the positive cells of Cytokeratin 19.

**Statistical analysis:** Data normality and homogeneity of variance were verified by the Shapiro-Wilk and the Levene's test, respectively. The data of Cytokeratin 19 expression from the epithelial buccal mucosa cells were then compared using independent samples t test analysis. In all the analysis, significance level was set at  $p < 0.05$ . Data were processed using SPSS 13.0 software for Windows (SPSS Inc; Chicago, IL, USA).

## Results

Expression of Cytokeratin 19 in the epithelial buccal mucosa cell of the control and azo-exposed groups is demonstrated in Fig. 1.

Positive expression of Cytokeratin 19 showed a brown color on the cytoplasm and nucleus. Expression of Cytokeratin 19 is displayed in Fig. 2A (control) and 2B (azo-exposed).

The expression of Cytokeratin 19 data were normally distributed according to Shapiro-Wilk test (azo-exposed:  $p = 0.138$ , and controls:  $p = 0.223$ ). The Levene's test showed  $p = 0.238$ , meaning that the data were homogeneous. Independent t test from assumed equal variances revealed a significant difference ( $p < 0.001$ ),

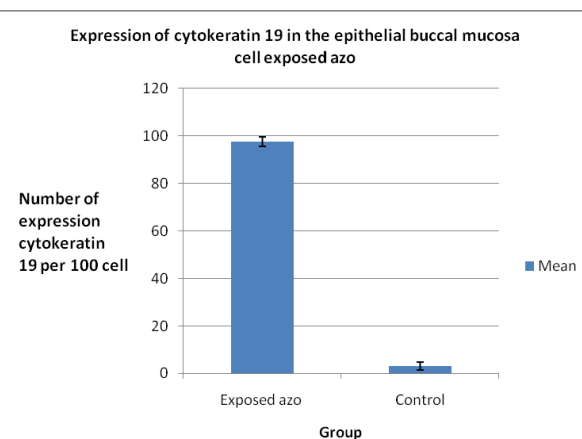


Fig. 1. Expression of Cytokeratin 19 in azo-exposed and control groups

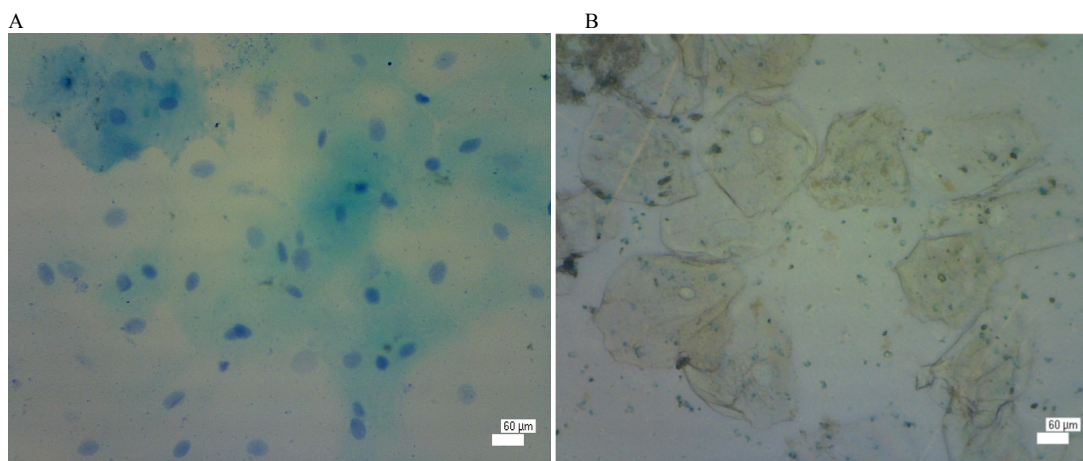


Fig. 2. Buccal epithelial mucosa control group showed a negative expression (blue) of Cytokeratin 19 (A). Positive expression was found in the cytoplasm and nucleus of the exposed azo group.

meaning that the expression of Cytokeratin 19 in azo-exposed participants was significantly higher than the controls. These results indicated that the exposure to azo significantly increased the expression of Cytokeratin 19.

### Discussion

This study used exfoliation technique to collect buccal epithelial tissue. Celik et al. (9) indicated that monitoring of the effect of genotoxic and cytotoxic, an indication of exposure to chemicals, and toxic response can be done using exfoliation techniques.

Expression of cytokeratin varies according to type of epithelial cells, expansion of differentiation, and tissue development. Expression of Cytokeratin 19 was very high in azo-exposed group (Fig. 1) and was significantly different compared to the controls ( $p < 0.001$ ). These results indicate that the exposure to azo allegedly affect the expression of Cytokeratin 19 in the buccal mucosa of batik workers.

Morton and Richard (10) suggested that epithelial cells on the buccal mucosa served as a first defense against particles that enter the body through inhalation or ingestion. The batik workers, who have been working for more than 5 years, are exposed to azo every day. Azo can lead to cell changes if it is entered and settled in the oral cavity (11).

The results support previous studies that exposure to azo dyes significantly affects the increasing frequency of micronuclei (12), karyolysis (13), piknosis (14), and expression of cytokeratin 5 (15) in the buccal mucosal epithelial cells of batik workers with the exposure duration of more than 5 years. Increased frequency of micronuclei, piknosis, karyolysis, and expression of Cytokeratin 5 was allegedly due to the high exposure of azo dyes on their bodies.

Exposure to azo may affect changes in the pattern of cell differentiation on the buccal mucosa of batik workers and can be detected by the expression of Cytokeratin 19, which is very high on the buccal mucosa. Expression of Cytokeratin 19, which is extremely high in the epithelial cells of the buccal mucosa, indicates the possibility of the

epithelial cells' excessive hyperproliferation caused by the exposure to azo. Garant (2) mentions that strong expression of Cytokeratin 8, 18, and 19 in the epithelial cells that undergo excessive hyperproliferation can change the oral mucosa into leukoplakia and squamous stratification carcinoma. The same opinion was also expressed by Cintorino et al. (5), stating that the expression of Cytokeratin 19 in suprabasal cell layer of the epithelium is strongly correlated with the premalignancy and hyperproliferation of chronic inflammation.

Exfoliative cytologic observations for the evaluation of cytokeratin are very helpful. The expression of Cytokeratin 19 on the azo-exposed epithelial cells of the buccal mucosa can be used as an early detection indicator of a change in the pattern of cell differentiation. Cytokeratin expression may indicate the possibility of a premalignant event.

### Conclusion

Exposure to azo significantly increases the expression of Cytokeratin 19 in the epithelial cells of the batik workers' buccal mucosa and may change the pattern of differentiation and maturation in the buccal mucosal epithelial cells.

### Acknowledgments

This study was supported by Fundamental Grant Contract Research (No: 015/SP2H/LT/DRPM/II/2016) on 17 February 2016 from the Ministry of Research, Technology, and Higher Education, Indonesia.

We would like to thank Dhinitya Hyta Narissi, Mufidana Azis, and Aurita Siwi Rahmawati who helped us in collecting the samples.

### Conflict of Interests

The authors declare that they have no competing interests.

### References

- Berkovitz B, Moxham B, Linden R, Sloan A. Oral Biology Master Dentistry, Vol. 3, London: Churchill Livingstone. 2011:235-238.
- Garant PR. Oral Cells and Tissues. Chicago: Quintessence. 2003:81-

<http://mjiri.iums.ac.ir>

Med J Islam Repub Iran. 2018(16 Mar); 32.23.

- 101.
3. Sawant S, Chauker D, Cruz, AR, Vaidya M. Cytokeratins as Prognostic Markers for Human Oral Cancer: Immerging Trends. *Int J Med Biol Front.* 2004;17(11):190-5.
  4. Moll R, Franke WW, Schiller DL, Geiger B, Krepler R. The catalog of human cytokeratins: patterns of expression in normal epithelia, tumors and cultured cells. *Cell.* 1982;31:11-24.
  5. Cintorino M, Petracca R, Vindigni C, Tripodi SA. Topography-related expression of individual cytokeratins in normal and pathological (non-neoplastic and neoplastic) human oral mucosa. *Virchows Archiv A Pathol Anat.* 1990;417:419-26.
  6. Lestari F. *Chemical: Sampling and measurement of contaminants in the air, Jakarta: Penerbit Buku Kedokteran EGC.* 2007:205-21.
  7. Widjajanti E, Regina TP, Prajonto UM. Zeolite adsorption pattern against azo red methyl dyes and orange, National Research Seminar, Faculty of Math and Science, Universitas Negeri Yogyakarta, Yogyakarta. 2011:1-14.
  8. Camargo-Ventura B de C, Maltempo PPP, Marin-Morales MA. The Use of the Cytogenetic to Identify Mechanisms of Action of an Azo Dye in Allium Cepa Meristematic Cells, *J Toxicology.* 2011;1(3):5-12.
  9. Celik A, Cavas T, Gozuka SE. Cytogenetic Biomonitoring in Petrol Station Attendants: Micronucleus Test in Exfoliated Buccal Cells. *Mutagenesis.* 2003;18(5):417-21.
  10. Morton W, Richard HC. *Toxic Metal Syndrome, New York: Avery Pub Group, New York.* 1995:26-31.
  11. Holland N, Claudia B, Fennech M, Stefano B, Errol Z, dan Siegfried K. The Micronucleus Assay in Human Buccal Cell as A Tool for Biomonitoring DNA Damage: The HUMN Project Perspective on Current Status and Knowledge Gaps, *Proceedings of the 5th International Conference on Environmental Mutagens in Human Populations, London: Elsevier.* 2008:16-30.
  12. Narissi DH, Handajani J, Tandelilin RTC. Analyze frequency of micronucleus on buccal mucosa of batik workers caused by azo dyes exposure, 2014. Available from: <http://etd.repository.ugm.ac.id/>
  13. Aziz M, Handajani J, Tandelilin RTC. The exposure effect of azo dyes in the increase of karyolysis nucleus in buccal mucosal epithelial cells of batik workers in Yogyakarta, 2014. Available from: <http://etd.repository.ugm.ac.id/>
  14. Rahmawati AS, Handajani J, Jonarta AL. The frequency of pyknosis cell in buccal mucosa epithelium caused by azo dyes, 2014. Available from: <http://etd.repository.ugm.ac.id/>.
  15. Handajani J, Narissi DH. Analyze the expression of cytokeratin 5 on the epithelial cells of the buccal mucosa in batik workers. *IJSR.* 2016;5(2):510-514.