

Anterior spinal surgery alone in the surgical treatment of thoracolumbar spinal tuberculosis: a prospective study

Farzad Omid-Kashani¹, Ebrahim G. Hasankhani², Mohamed H. Ebrahimzadeh³

Orthopaedic Research Center, Emam Reza Hospital, Faculty of Medicine, Mashhad University of Medical Sciences, Mashhad, Iran.

Received: 27 September 2011

Revised: 30 October 2011

Accepted: 2 November 2011

Abstract

Background: One of the important sites for extrapulmonary TB involvement is the skeleton. Tuberculous spondylitis (Pott's disease) comprises 50-70% of the skeletal tuberculosis.

Methods: In this case series study, we prospectively investigated the result of anterior surgery alone (anterior debridement, fusion and instrumentation) in the patients with spinal tuberculosis. The patients with immature skeleton, long segment disease or kyphosis more than 50° were excluded. All the cases were followed for at least 2 years (mean 31.4±6.4 months).

Results: This study comprised of 23 (13 male and 10 female) cases with a mean age of 35.8 (SD=7.8) years old. Segmental kyphosis was corrected from +11.9° (SD=13.8°) preoperatively to -3.8° (SD=8.9°) after surgery that was mainly maintained at the last follow up visit. Bony union was achieved in all cases but one.

Conclusions: Our results showed that in selected cases of tuberculous spondylitis, anterior surgery alone could be encouraging.

Keywords: Tuberculosis, Spine, Instrumentation, Fusion.

Introduction

Tuberculosis (TB) is a disease of enormous dimensions worldwide. World Health Organization estimates that approximately one third of the world's population is infected with Mycobacterium Tuberculosis and the disease is thought to cause at least 3 million deaths each year, and the annual number of new cases is now nearly 8 million [1].

About 16% of newly reported cases of tuberculosis involve extrapulmonary sites [2]. One of the important sites for extrapulmonary TB involvement is the skeleton. The incidence of this type of TB has been raised with increasing age and is equally frequent among men and women. Any bone in the

body may be involved [3, 4] even though, tuberculous spondylitis (Pott's disease) occurs most commonly and comprises 50-70% of the skeletal tuberculosis. The most commonly involved vertebrae in adults are the lower thoracic and upper lumbar whereas in children the upper thoracic spine is the most frequent site [5].

Standard chemotherapy is highly successful in skeletal TB, but surgery is occasionally a necessary adjunct [6]. There is no well-defined surgical procedure of choice, although an "all-or-none" approach has been advocated by several surgeons [7]. However nearly most of the authors agree that surgery is indicated in early neurologic findings especially in the cases with progressive neural

1. (Corresponding author) Orthopaedic Research Center, Emam Reza Hospital, Faculty of Medicine, Mashhad University of Medical Sciences, Mashhad, Iran. omidif@mums.ac.ir

2. Department of Orthopaedic, Emam Reza Hospital, Faculty of Medicine, Mashhad University of Medical Sciences, Mashhad, Iran. hasankhanie@mums.ac.ir

3. Department of Orthopaedic, Ghaem Hospital, Faculty of Medicine, Mashhad University of Medical Sciences, Mashhad, Iran. ebrahimzadehmq@mums.ac.ir

deficit [8]. In this case series study, we prospectively investigated the result of anterior surgery alone in our patient with spinal TB.

Methods

In this case series research, we prospectively studied 23 patients with active thoracolumbar spinal TB who surgically treated with one stage anterior operation. All of these patients were treated by one surgeon and by one surgical technique. Our inclusion criteria for surgery were spinal instability (figure 1), involvement of the thoracolumbar spinal region, a failure of medical treatment, neurological compromise especially in the form of progressive neurologic dysfunction, and a large soft tissue mass including a huge cold abscess. We excluded the patients with vertebral involvement of equal or more than 3 levels (long segment disease) [9,10], kyphotic deformity more than 50 degrees, those cases with less than 2-year follow-up, and the cases whose pre- or postoperative diagnosis was not compatible with TB. In patients with equal or more than 3 vertebral involvements, severe kyphosis, or in immature children, two stage surgeries (anterior debridement and fusion, and then posterior fusion and instrumentation) were performed. These patients were also not included in this study. All the participants had assigned the informed consents.

Chest x-ray was performed in all cases to reveal any concomitant pulmonary infection. Due to the endemic state, we relied on clinical and non-invasive paraclinical (blood tests and imaging) characteristics for confirmation of TB diagnosis. In no case preliminary aspiration or biopsy was performed.

Surgical technique

All the patients were operated on in right lateral decubitus position, with left thoracotomy, thoracoabdominal or anterior retroperitoneal approaches, depending on infected level. After thorough debridement and drainage, vertebral body was reconstructed either with tricortical iliac crest bone graft or mesh cage compacted inside with autogenous or allogeneous bone graft.

Finally the construct was rigidly immobilized with anterior spinal instrumentation (via ("Xia anterior" is a brand name of this system) anterior spinal implant; Stryker, figure 2). Postoperatively, the patient was mobilized on the 2nd or 3rd day after surgery while a rigid orthosis was applied. Medical treatment with anti-tuberculous drugs was continued according to standard regional protocol.

Neurologic deficit in our patients was graded according to the Impairment Scale defined by American Spinal Injury Association (ASIA), ranging from A through D for spinal cord injuries [11, 12]. Regional scoliosis or kyphosis was measured as the angle formed by intact upper and lower endplates of the infected vertebrae on standing posteroanterior and lateral views. Sagittal angles were recorded with negative or positive measures if they were applied to lordotic or kyphotic angles, respectively. At the last follow up visit, crossed bony trabeculation, absence of implant failure, loosening, and significant correction loss or pain imply to the solid fusion.

The patients were followed at 2 weeks, 2months, and 6months and then annually after the operation.

Statistical Methods

The preoperative and most recent postoperative scales were compared with use of the paired T test. The level of significance was set at $p < 0.05$. All analyses were performed with use of Statistical Package Science Software (SPSS v. 10).

Results

After inclusion and exclusion criteria came into account, we studied 23 (13 male and 10 female) cases in this research. The mean age of the patients was 35.8 (SD=7.8, ranged 23 to 50 years old). Vertebral levels involvement was depicted in Fig. 3.

16 cases (70% of the patients) were first treated by at least 2 to 3 weeks medical therapy with anti-tuberculous drugs. In reminder, due to urgent situations like acute or progressive neurologic deficit, neoadjuvant

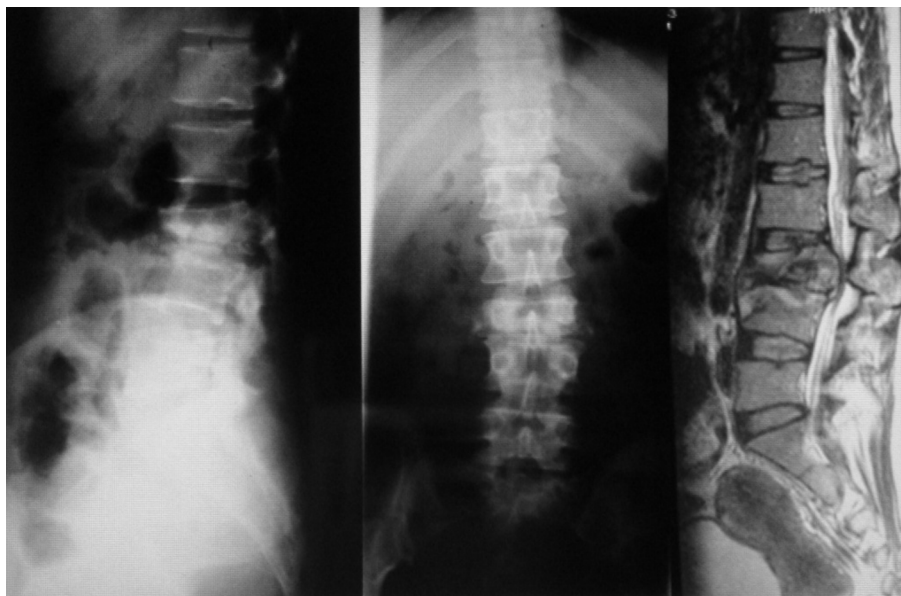


Fig. 1. An adult woman with tuberculous spondylitis. A 34 years old woman presented with a history of low back pain for about 6 months followed by inability to walk, and wheelchair bound. In imaging vertebral bodies of L3 and most of the L4 was destroyed.

therapy was not carried out.

Summary of pre- and postoperative findings in our patients was shown in Tables 1 and 2. Mean preoperative segmental kyphosis and scoliosis were $+11.9^\circ$ (SD= 13.8° , range $+35^\circ$ to -28°) and 4.8° (SD= 4.1° , range 0 to -10°), respectively. Immediate postoperative segmental kyphosis was corrected to a mean of -3.8° (SD= 8.9°). This difference between pre- and post-operative kyphosis was significant statistically ($p < 0.05$). The correction was mainly main-

tained during the healing process (with a minimal mean correction loss of about 1.8° (SD= 1.3°) at the latest following up visits that was trivial; $p = 0.12$).

Chest x-ray revealed that 7 out of 23 patients (30%) had some evidences of pulmonary involvement but active pulmonary tuberculosis was only present in 3 cases (13%). Prevalence of HIV infection in our patients was 17.3% (4 cases). The mean follow up period was 31.4 months (range; 24-52, SD=6.4).

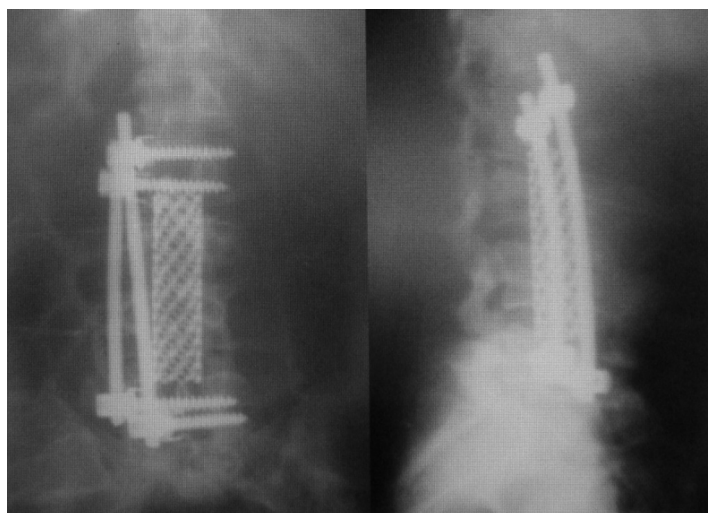

Fig.2. Postoperative radiographs. Plain anteroposterior and lateral view of the lumbar spine, postoperatively taken in the same patient depicted on figure 1. The patient was operated anteriorly by radical debridement, anterior reconstruction with mesh cage and bone graft, and rigid anterior instrumentation.

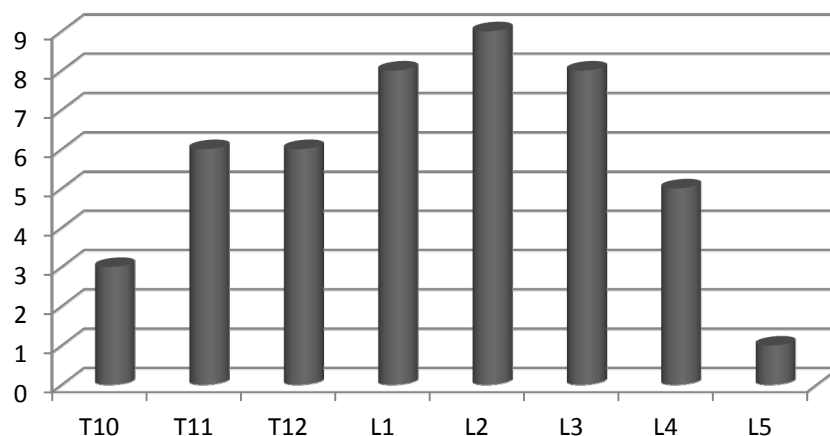


Fig. 3. Vertebral levels involvement in our patients.

We had 3 patients with significant preoperative neurologic deficit. Complete neural recovery was observed in two, and an improvement from ASIA scale B to D in the rest of them.

Bony union was achieved in all cases but one (case #8). In this patient, implant failure (screw breakage without significant displacement) was associated with refractory

pain. So he was treated with posterior spinal fusion and instrumentation. The pain was finally disappeared and bony union was occurred.

We did not have any deep wound infection but superficial infection occurred in 2 cases that responded satisfactorily to the nonoperative measures. In one case, intraoperative ureteral tearing occurred that was

Table 1. Summary of Preoperative findings.

Case No	Sex	Age	History	Level of involvement	Regional Kyphosis/ Scoliosis	Concomitant abscess	Neural compression (Imaging/Clinical)
1.BA	M	31	Lt Wrist tenosynovitis operated 3y ago	T10-11	+32/10	No	Yes/No
2.MM	M	45	IV drug, HIV+	T11-12	+18/4	No	Yes/No
3.MA	F	30	-	L4-5	-28/0	No	Yes/No
4.RS	M	28	Prisoner, L2-3 VBs	T10-11	+35/0	Yes	Yes/Yes(D*)
5.ZY	F	34	-	L3-4	+20/8	No	No/No
6.AAG	M	34	Prisoner, HIV+	L2-3	+20/8	Yes	Yes/No
7.MS	M	23	-	T12-L1	+16/4	Yes	Yes/Yes(B*)
8.ZC	F	28	-	L1-2	+8/0	No	Yes/No
9.MH	M	36	Pulmonary TB	L2-3	0/4	Yes	Yes/Yes(paresthesis)
10.AF	M	32	-	L1-2	+10/0	No	No/No
11.MA	F	47	IV drug, HIV+	L3-4	+18/10	No	Yes/No
12.AR	M	28	-	L1-2	+12/0	Yes	Yes/No
13.AG	M	29	-	L3-4	-10/8	No	Yes/Yes(dysesthesia)
14.HT	M	43	-	T11-12	+16/0	No	No/No
15.NF	F	50	Prisoner	L2-3	+8/10	No	No/No
16.SG	M	48	-	T11-12	+14/4	Yes	Yes/No
17.SR	F	29	Pulmonary TB, IV drug	L1-2	+16/0	Yes	Yes/No
18.KY	F	38	IV drug	T12-L1	+20/10	No	No/No
19.BH	F	47	-	T12-L1	+14/8	No	Yes/Yes(C*)
20.VA	M	41	Prisoner	L3-4	-10/0	Yes	Yes/No
21.FK	F	35	IV drug	L2-3	+8/4	No	Yes/Yes(paresthesis)
22.ZH	F	30	HIV+	T10-11	+26/8	No	No/No
23.AR	M	38	Pulmonary TB	L1-2	+12/10	Yes	Yes/Yes(paresthesis)

*American Spinal Injury Association Impairment Scale

Table 2. Summary of postoperative findings.

Case No	Kyphosis/Scoliosis		Complications
	Early	Final	
1.BA	+5/2	+5/2	
2.MM	-7/0	-6/0	Death 3years after operation (septicemia due to severe IV drug abusing)
3.MA	-30/0	-28/0	Superficial wound infection
4.RS	0/4	+4/4	Complete neurologic recovery
5.ZY	-10/2	-10/2	-
6.AAG	-8/4	-8/6	-
7.MS	+4/0	+5/0	Neurologic state D
8.ZC	0/0	+20/10	Implant failure and pain (treated by PSFI†)
9.MH	-10/2	-10/0	-
10.AF	0/2	0/2	-
11.MA	-12/0	-12/2	Intraoperative ureteral tearing (Intraoperatively was repaired)
12.AR	-6/0	-6/0	-
13.AG	-15/4	-13/6	-
14.HT	+4/0	+6/2	-
15.NF	-4/4	-4/6	-
16.SG	+4/0	+4/0	-
17.SR	-2/0	-2/0	-
18.KY	+4/0	+4/4	Superficial wound infection
19.BH	+4/4	+4/6	Complete neurologic recovery
20.VA	-16/2	-14/2	-
21.FK	-2/0	0/0	-
22.ZH	+10/2	+12/4	-
23.AR	0/4	2/4	-

†PSFI=Posterior Spinal Fusion and Instrumentation

repaired on that session with double J stent. The stent was removed 3 months later with no additional complication. We did not notice any adverse reaction like miliary tuberculosis even in the cases who did not receive neoadjuvant medications before surgery.

Discussion

Extrapulmonary tuberculosis presents more of a diagnostic and therapeutic challenge than pulmonary tuberculosis. This partly relates to its being less common and therefore less familiar to most clinicians. In addition, extrapulmonary tuberculosis usually involves relatively inaccessible sites [5].

In Pott's disease, the destructive changes usually involve two adjacent vertebrae but rarely and lately the intervertebral discs. A usual presentation of the disease is pain. Systemic symptoms of infection are not common. The imaging abnormalities are not specific for tuberculosis but may be seen with any chronic osteomyelitis [13]. Confirmation of the diagnosis is obtained by aspiration or biopsy. Evidence of granuloma-

tous inflammation even in the absence of bacteriologic proof of the diagnosis is sufficient to begin anti-tuberculosis therapy unless another cause is found [14].

In a clinical review of 40 cases with tuberculous spondylitis, Tasova et al retrospectively studied the clinical presentation, laboratory, and radiologic findings in adult cases [15]. 30% of their patients had a history of contact with a patient having active pulmonary TB and 85% of them required surgery in addition to standard medical treatment. The most frequent symptom and site were low back pain and lumbar spine, respectively.

Anterior debridement and fusion through anterior approach has been the most common standard surgical treatment of spinal tuberculosis. Prolonged external immobilization or more recently posterior fusion and instrumentation via posterior approach are also proposed [16]. Recently, a variety of new approaches were introduced to facilitate and simplify the surgery. Posterior lumbar interbody fusion and posterior instrumenta-

tion is one of this approaches described by Lee for the lumbar tuberculous spondylitis [17].

In the past, most surgeons had some concerns about anterior instrumentation in the presence of tuberculous infection partly because of introducing foreign material into infected tissue. In one of the first reports related to applying anterior instrumentation in the patients with tuberculous spondylitis in 1999, Yilmaz et al [18] observed no recurrence of the disease. Average correction of the deformity which they reported was 64% and 81% in the cases with one or two levels of involvement and the patients with more than two levels, respectively. They propose that anterior is more effective than posterior instrumentation for reducing the deformity and stabilizing the vertebral column in patients who have kyphosis due to spinal tuberculosis.

In 2003, Benli reported their surgical results of 63 patients with Pott's disease who underwent anterior radical debridement, fusion and instrumentation [19]. The mean age of the patients was 46.8 years. They observed that the addition of anterior instrumentation increased correction rate of the deformity and maintaining it. Out of 25 patients with neurologic deficit, 20 and 4 had full and partial recoveries, respectively. They reported very few intra and postoperative complications. They employed an aggressive neoadjuvant chemotherapy prior to surgery (except in urgent cases with recently developed or progressive neurologic deficit) and reported no disease reactivation at all. Finally, they concluded that anterior instrumentation is a safe and effective method in the treatment of tuberculous spondylitis.

Similarly Jin [20] reported the surgical results of one stage anterior interbody autografting and instrumentation in thoracolumbar spinal tuberculosis in 23 cases with spinal tuberculosis; while 14 out of 15 patients with neurological deficit showed obvious improvement. A mean of 18° -kyphosis correction was achieved after surgery but a moderate progressive kyphosis occurred after 2 ½ years in a 9-yr child. Ultimately, they

recommended one-stage anterior interbody autografting and instrumentation in the surgical management of spinal tuberculosis in selected cases and suggested supplementary posterior fusion in children.

Conclusions

Our results showed that in selected cases of tuberculous spondylitis, anterior surgery alone that comprises thorough debridement, arthrodesis and rigid instrumentation could be encouraging. It is obvious that this approach for the cases with long segment involvement or severe kyphosis may be more challenging and even not applicable.

Acknowledgements

The authors wish to thank Toosi Katayoun Zarei for her help in reviewing and copyediting this paper. We would like to express our gratitude to Shahrzad Ariamanesh for her help in editing and verifying this paper.

Conflicts of interest

No benefits in any form have been received or will be received from a commercial party related directly or indirectly to the subject of this article.

References

1. Dye C, Scheele S, Dolin P, Pathania V, Raviglione MC. Consensus statement. Global burden of tuberculosis: estimated incidence, prevalence, and mortality by country. WHO Global Surveillance and Monitoring Project. JAMA 1999; 282(7): 677-686.
2. Centers for Disease Control and Prevention: Reported tuberculosis in the United States, 1997. Atlanta: Centers for Disease Control and Prevention, 1998.
3. Kumar A, Varshney MK, Trikha V, Khan SA. Isolated tuberculosis of the coccyx. J Bone Joint Surg Br 2006; 88(10): 1388-9.
4. Khan SA, Varshney MK, Hasan AS, Kumar A, Trikha V. Tuberculosis of the sternum: a clinical study. J Bone Joint Surg Br 2007; 89(6): 817-20.
5. Weir MR, Thornton GF. Extrapulmonary tuberculosis. Experience of a community hospital and review of the literature. Am J Med 1985; 79(4): 467-478.
6. Bakhsh A. Medical management of spinal tuberculosis: an experience from Pakistan. Spine 2010; 35(16): E787-91.
7. Tuli SM. Results of treatment of spinal tuberculosis by "middle-path" regime. J Bone Joint Surg Br

1975; 57(1): 13-23.

8. Kelly PJ, Karlson AG. Musculoskeletal tuberculosis. *Myo Clin Proc* 1969; 44(2): 73-80.

9 Jain AK, Dhammi IK, Prashad B, Sinha S, Mishra P Simultaneous anterior decompression and posterior instrumentation of the tuberculous spine using an anterolateral extrapleural approach. *J Bone Joint Surg Br* 2008; 90(11): 1477-81.

10. Modic MT, Steinberg PM, Ross JS, Masaryk TJ, Carter JR. Degenerative disk disease: assessment of changes in vertebral body marrow with MR imaging. *Radiology* 1988; 166: 193-9.

11. Ditunno JF, Young W, Donovan WH, Creasey G. The international standards booklet for neurological and functional classification of spinal cord injury. American Spinal Injury Association. *Paraplegia* 1994; 32(2):70-80.

12. Maynard FM, Bracken MB, Creasey G, Ditunno JF Jr, Donovan WH, Ducker TB, et al. International standards for neurological and functional classification of spinal cord injury. American Spinal Injury Association. *Spinal Cord* 1997; 35(5): 266-74.

13. Kim CJ, Song KH, Jeon JH, Park WB, Park SW, Kim HB, et al. A comparative study of pyogenic and tuberculous spondylodiscitis. *Spine* 2010; 35(21): E1096-100.

14. Berney S, Goldstein M, Bishko F: Clinical and

diagnostic features of tuberculous arthritis. *Am J Med* 1972; 53(1): 36-42.

15. Tasova Y, Sarpel T, Inal AS, Saltoglu N, Guzel R, Kurtaran B. A clinical review of 40 cases with tuberculous spondylitis in adults. *Neurosurg Q* 2006; 16(4): 169-176.

16. Jain AK. Tuberculosis of the spine: a fresh look at an old disease. *J Bone Joint Surg Br* 2010; 92(7): 905-13.

17. Lee JS, Moon KP, Kim SJ, Suh KT. Posterior lumbar interbody fusion and posterior instrumentation in the surgical management of lumbar tuberculous spondylitis. *J Bone Joint Surg Br* 2007; 89(2): 210-4.

18. Yilmaz C, Selek HY, Gürkan I, Erdemli B, Korkusuz Z. Anterior instrumentation for the treatment of spinal tuberculosis. *J Bone Joint Surg Am* 1999; 81(9): 1261-7.

19. Benli IT, Acaroğlu E, Akalin S, Kiş M, Duman E, Un A. Anterior radical debridement and anterior instrumentation in tuberculosis spondylitis. *Eur Spine J* 2003; 12(2): 224-34.

20. Jin D, Qu D, Chen J, Zhang H. One-stage anterior interbody autografting and instrumentation in primary surgical management of thoracolumbar spinal tuberculosis. *Eur Spine J* 2004; 13(2): 114-21.