

## NEW APPLICATION FOR THE BITEMPORAL (VISOR) FLAP IN RECONSTRUCTION OF ADVANCED LOWER LIP CARCINOMA

MASOUD MOTASADDI ZARANDY, M.D., MOJGAN KIANI ASIABAR,  
M.D., LAYLA MOSTAAN, M.D., ARMAN TAHERI, M.D., AND SAFA  
SAMADZADEH, M.D.

*From the Department of Otolaryngology, Head and Neck Surgery, Tehran University of Medical Sciences,  
Tehran, Iran.*

### ABSTRACT

**Background:** Lip carcinoma is a common cancer with a good prognosis and when patients refer early in the course of disease the results of treatment are acceptable.

Surgical procedures for reconstruction of lip defects are the use of remaining lip tissue, tissue from the opposite lip, adjacent cheek tissue, distant flaps and microvascular free flaps.

The bitemporal (visor) flap is a regional flap that is used in large advanced upper lip lesions. This study shows that it can be used in the reconstruction of total lower lip lesions. It is in the same operative field, the defect can be covered in the same operation, spread of disease is detected more easily, and it can camouflage the scar. In male patients it is very acceptable aesthetically and multiple surgical teams are not required.

**Methods:** Two patients with advanced lower lip squamous cell carcinoma were operated and the defect reconstructed with a bitemporal (visor) flap. After the hair is shaved, a bipedicle temporal flap including the major branch of the superficial temporal artery was swung in two portions over the defect, and a split-thickness skin graft used to cover the donor site.

**Results:** Both patients had no major problem with deglutition or speech after sectioning the pedicles.

**Conclusion:** The bipedicle temporal flap can be used for reconstruction of midface defects. There is no report of lower lip reconstruction with the bitemporal flap. This study shows that the bitemporal flap can be used in reconstruction of total lower lip lesions, especially in male patients. It is in the same field, the defect can be covered in the same operation, spread of disease is detected more easily, it can camouflage the scar and does not require two team management.

*MJIRI, Vol. 19, No. 4, 297-302, 2006.*

**Keywords:** bitemporal flap, defect, reconstruction.

---

**Correspondence:** M. Motasaddi, M.D., Otolaryngology Department, Amiralam Hospital, Saadi Ave., Tehran, Iran. Tel: +989121097479, e-mail: Motasaddi@Yahoo.com

### INTRODUCTION

The lip plays an essential role in deglutition, articulation and facial expression. Reconstruction of its lesions is very important and offers a unique challenge to the surgeon.<sup>1</sup> Contemporary lip reconstruction techniques are based on early work from the 19th century.

The gold standard management of patients with lip cancer is complete excision of the tumor with a margin of normal tissue, although radiation therapy may be used in those patients who refuse surgery or who carry an unacceptable surgical risk.<sup>2</sup>

There is no report of lower lip reconstruction with the bitemporal flap.<sup>1,2,3,4</sup>

In this article two patients with advanced lower lip squamous cell carcinoma that were operated and the defects reconstructed with bitemporal flap are presented.

### PATIENTS AND METHODS

When the lesion is greater than 2/3rds of the

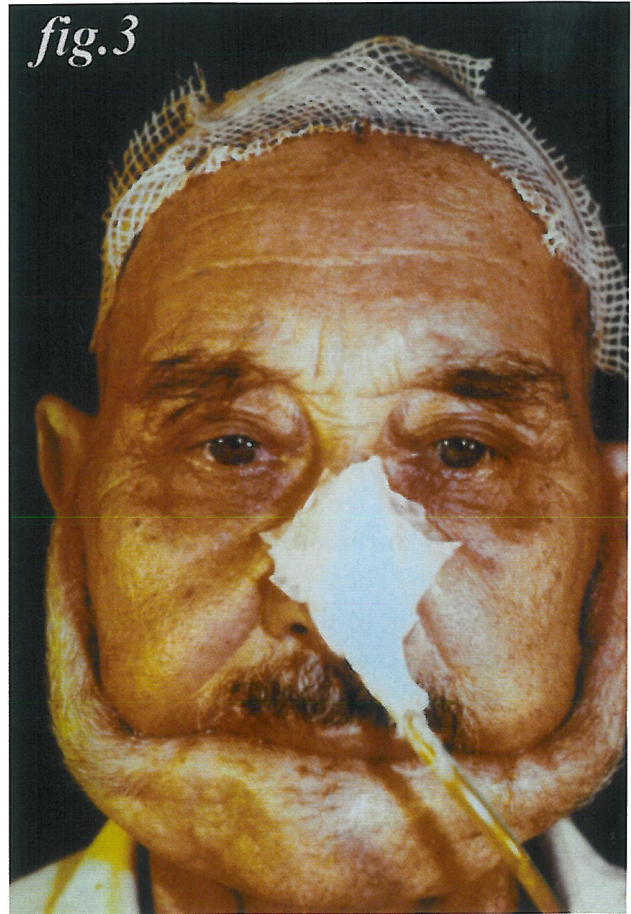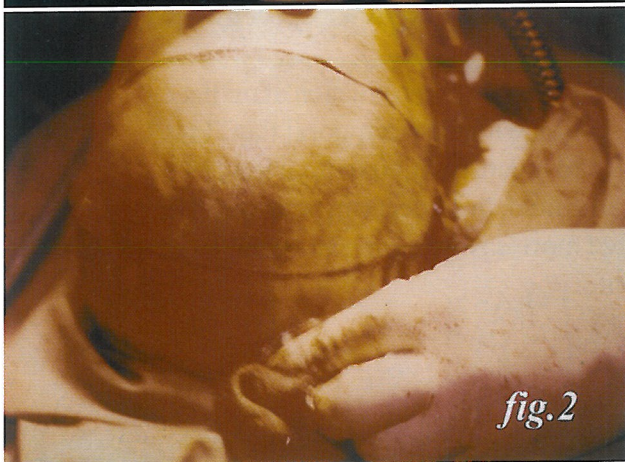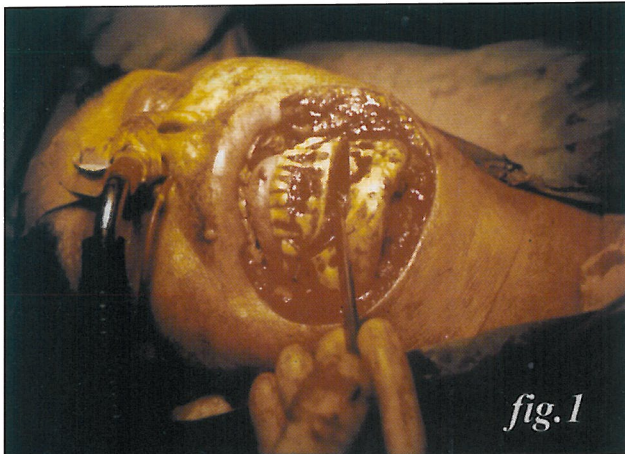
lower lip with chin involvement and no local flap can be used to reconstruct the defect, especially in the male patient, he becomes a good candidate for repair with this flap.

After the hair is shaved, a bipedicle temporal flap including the major branches of the superficial temporal artery in both pedicles is outlined.

The full-thickness flap, including galea, is immediately swung into position over the defect. No delay is necessary. A non hair-bearing area is used for the lip and rotated into position. Alternatively a free split-thickness skin graft or a tongue flap can also be used as mucous membrane lining.<sup>3</sup>

Split-thickness skin grafts are used to cover the donor site and the bare areas of the pedicles.

The time of section of the pedicles will depend on the blood supply derived from the edges of the defect. Sectioning should be done in stages (one side at a time). At a later stage, the vermillion of the lip can be restored by using cross – lip grafts of the vermillion of the other lip.<sup>3</sup>



**Fig. 1-3.** Case 1, The defect was reconstructed with a bitemporal flap.

**Case 1**

A 60 year old man who had an itching, bleeding ulcer in the lower lip was referred to our hospital. At first visit the commissure was involved and the ulcer periphery had a 2 cm induration. Preoperative biopsy indicated that the lesion was squamous cell carcinoma.

The lesion, accompanied with a 2 cm margin, the lateral part of the upper lip and half of the mucosa over the lower alveolar ridge was excised.

The defect was reconstructed with a bitemporal flap (Figs. 1,4). The bare surface of the flap was grafted with a split - thickness skin graft. The pedicles were sectioned 4 and 6 weeks later consecutively (Figs. 5-7).

The patient has had no major problem with deglutition or speech after sectioning the pedicles.

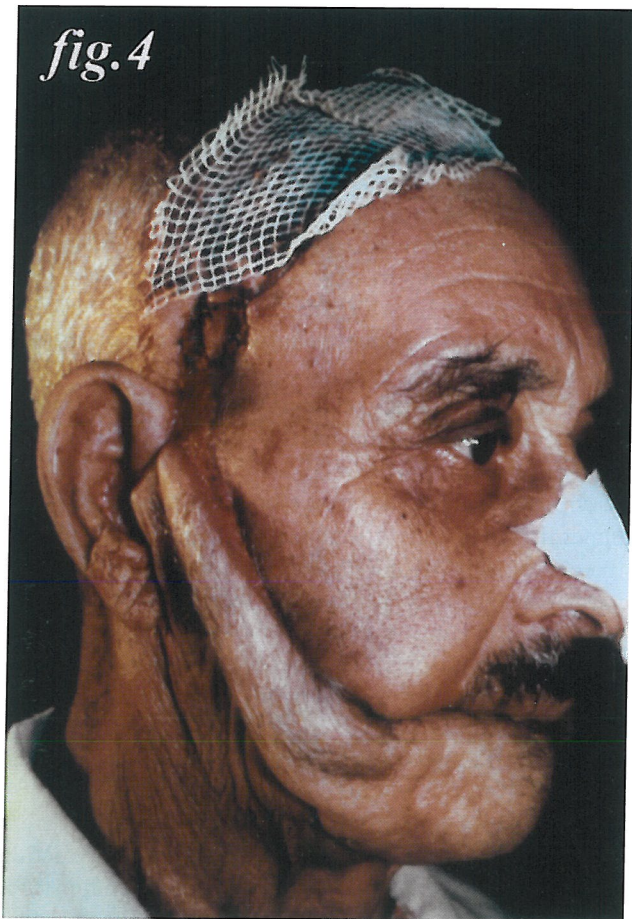**Case 2**

A 74 year old man with a small ulcer in the lower lip for 4 years which had enlarged since 2 months ago was referred to our hospital. Previous biopsy indicated that the lesion was squamous cell carcinoma. The patient received a full - course radiation therapy which was not

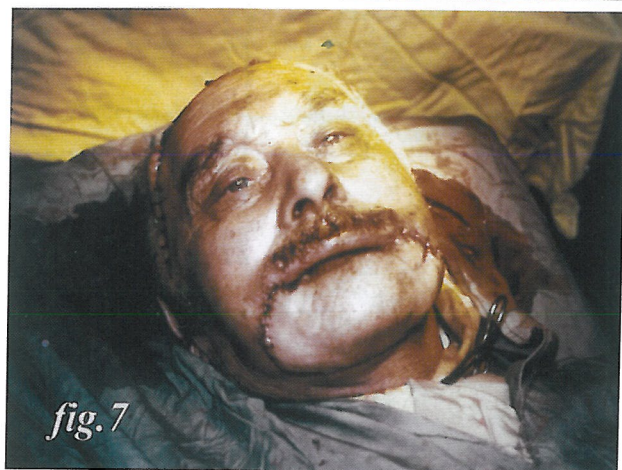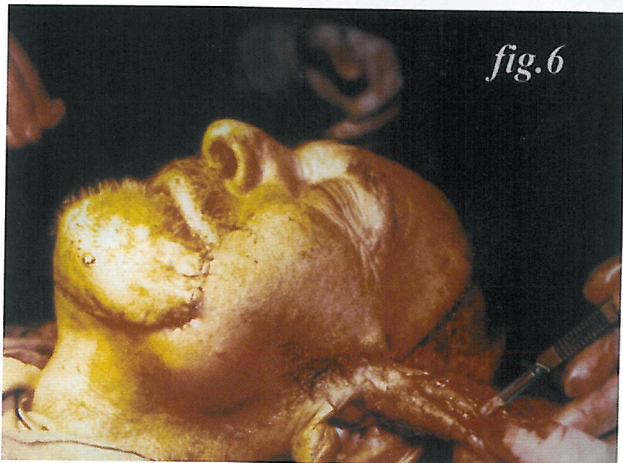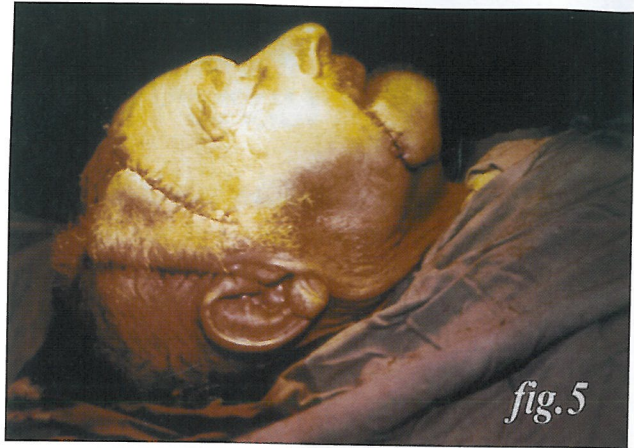effective and was referred for surgical resection.

At first visit the lesion involved the lower lip, chin and alveolar ridge and was infected and ulcerated.

After systemic antibiotic therapy, the entire lower lip with both commissures and the upper one-third of the



**Fig. 4.** Case 1, Three weeks after operation.



**Fig. 5-7.** Case 1, Four weeks later. The flap pedicle was sectioned and the pedicle was returned to the scalp.

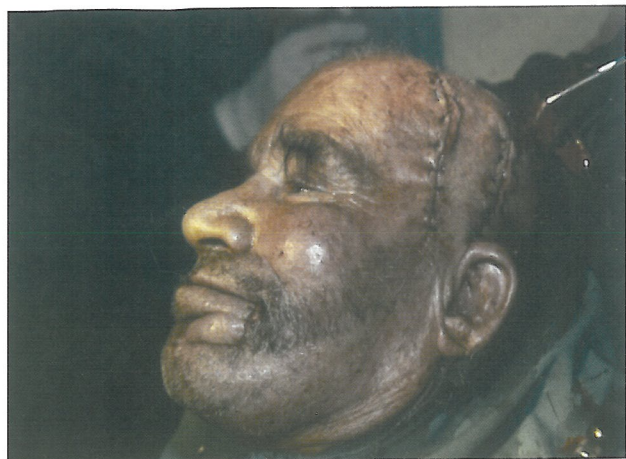

Fig. 8. Case 2, designed bitemporal flap for reconstruction of the lower lip defect.

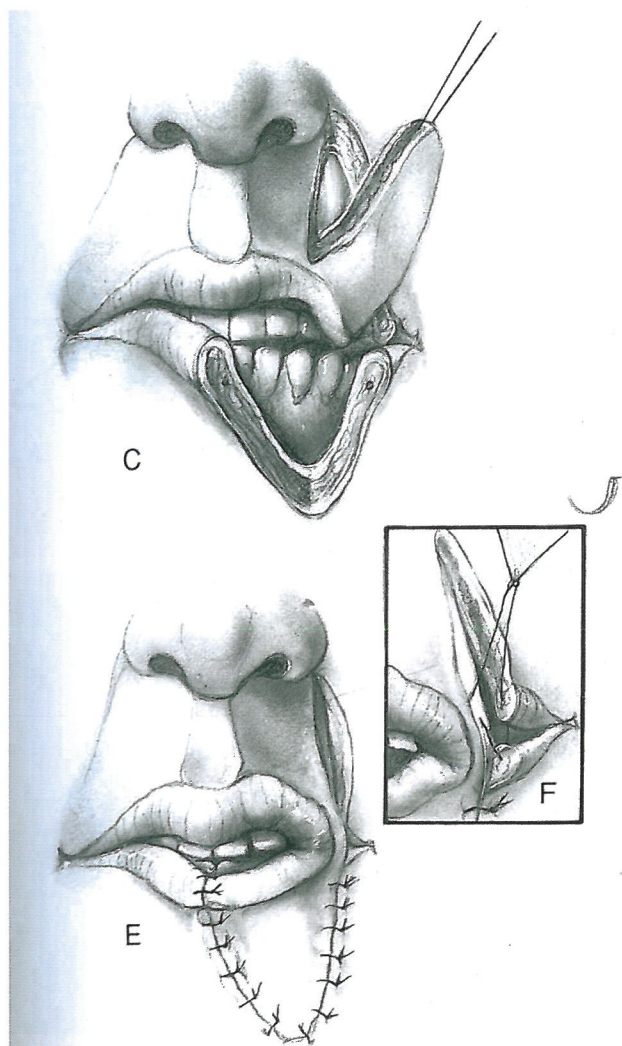


Fig. 9. Abbe-Estlander Lip Operation.

mandible with incisor teeth was resected.

The margins were reported free with frozen section and the defect was reconstructed with a bitemporal flap (Fig. 8). Pedicles were sectioned after 4 weeks.

As in the first case this patient has had no problem with deglutition and speech.

## RESULTS AND DISCUSSION

Reconstruction of lip defects is very important due to its function in deglutition and speech. Various methods have their own advantages and disadvantages. Reconstruction of large defects with local flaps are troublesome.

Surgical procedures used for reconstruction of lip defects are classified as:

- 1) those that use remaining lip tissue
- 2) those that borrow tissue from the opposite lip
- 3) those that use adjacent cheek tissue
- 4) those that use distant flaps
- 5) microvascular free flaps

The first two categories are the preferred method and reconstruction remains within aesthetic units of the lip.

After resection the edges of the defect immediately retract and the defect size must be measured before excising the lesion.<sup>1</sup> In the Shield technique up to one-third of the lower lip may be excised, 1.5 to 2.3 cm, and the defect closed with simple approximation of the edges. In the Abbe-Estlander lip operation, one-third to one-half of the upper or lower lip can be resected for carcinoma with immediate reconstruction (Fig. 9).

In those patients in which the defect is greater than two-thirds of the lip width, reconstruction becomes difficult and closure of only the defect site will not provide normal lip function.

In extensive upper or lower lip lesions if adjacent cheek tissue is inadequate, regional, distant or revascularized flaps must be used.<sup>5</sup>

Options include the Gillies fan flap (two-thirds of the upper lip is excised. It often results in excess scarring in the cheek) (Fig. 10), Webster modification of the Bernard-Von (virtually the entire lower lip can be excised.) (Fig. 11), and Burrow's flap (excision of excess skin and muscle with straight horizontal advancement; a significant drawback is narrowing of oral orifice), deltopectoral flap and pectoralis major myocutaneous flap. In upper lip lesions bitemporal (visor) flap and neck flap also can be used.<sup>2</sup>

Because of their multiple advantages, free flaps from the radial forearm have a definite role for reconstruction of head and neck defects.<sup>6</sup> It can be used for reconstruction of the lower lip in combination with other procedures like radial forearm-palmaris longus tendon, radial

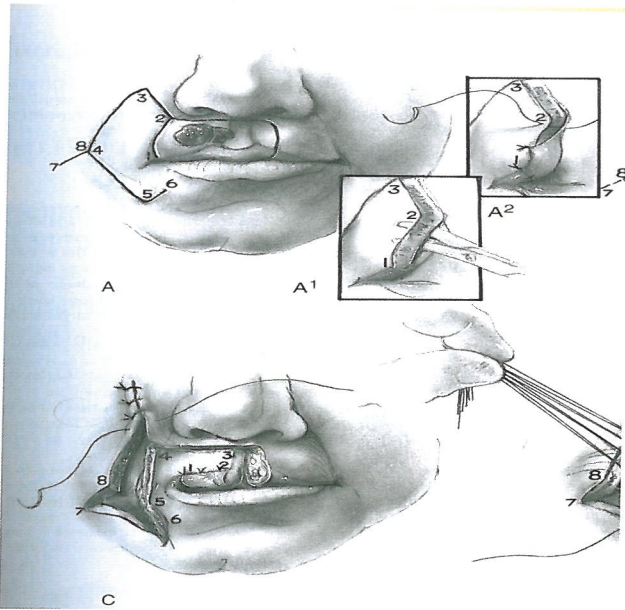


Fig. 10. Fan Flap Reconstruction.

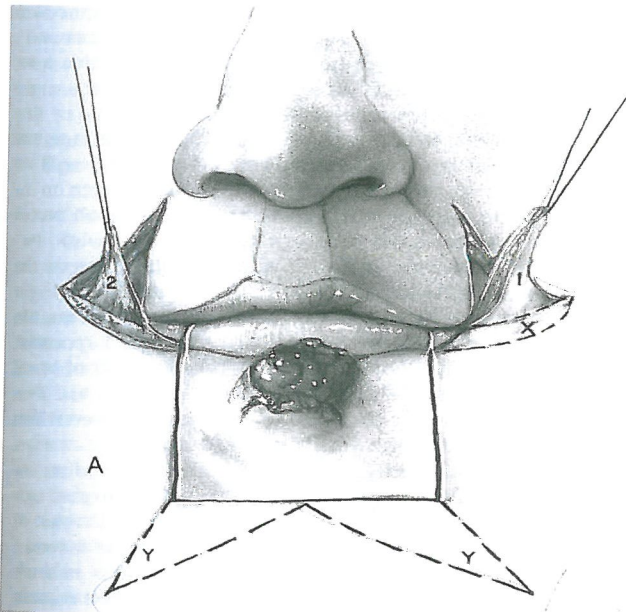


Fig. 11. Resection of lower lip with bernard reconstruction.

mity precludes its common use.<sup>10,11</sup>

The bitemporal (visor) flap is a regional flap that can be used in selected patients for reconstruction of larger lower lip lesions, especially in male patients.

The advantages and disadvantages of this flap are:

-With respect to defect it is in the same field.

-No delay is necessary and the bipedicle full-thickness flap is immediately swung into position over the defect. This is particularly important since the defect can be covered at the same operation.

As local tissue is not used in this flap, in malignant neoplasms spread of the disease is detected more easily and not confused with the scars of local flaps.

The hair-bearing portion of the flap can camouflage the scar and in male patients it is very acceptable aesthetically.

The use of local advanced skin or mucosal flaps, if feasible, is often preferred. The regional flaps are more easier than distant flaps or microvascular free flaps.

It is more viable than free flaps and does not need larger services with two teams.

The major drawbacks of this flap are that it require 2 or 3 stages for reconstruction and it leaves a significant aesthetic deformity on the forehead at the donor site especially in younger patients.

However, most flaps are nonfunctional in that they do not have muscular activity in relation to the part that they are replacing as this flap. On the other hands free flaps in combination with other methods do not have this problem and a sensate and functional lip can be produced.<sup>7,9</sup> But the easy technique and minor aesthetic deformity of the donor site make it acceptable in special situations for the surgeon and the patient.

## CONCLUSION

Bipedicle temporal flap can be used for reconstruction of midface defects.

There is no report of lower lip reconstruction with the bitemporal flap. This study shows that the bitemporal flap can be used in reconstruction of total lower lip lesions, especially in male patients.

## REFERENCES

1. Barker SR: Reconstruction of facial defects. Otolaryngology Head and Neck Surgery, Vol. 1 (ed. 3), St Louis Missouri: Mosby, pp. 527-559, 1998.
2. Galyon SW, Frodel JL: Lip and perioral defects. The Otolaryngol Clin North Am 34: 647-666, 2001.
3. Lore JM: An Atlas of Head and Neck Surgery, (2nd ed), Philadelphia, PA: Saunders, 1988.

forearm with a masseter muscle transfer and radial forearm with Webster modification.<sup>7,8,9</sup>

It must be emphasized that microvascular free flap reconstruction needs great technical experience and trained medical personnel.

The bipedicle forehead flap (bitemporal flap) may be used for total upper lip reconstruction. In males, hair-bearing scalp may be incorporated to provide hair growth for scar camouflage, but the unsightly secondary defor-

## Visor Flap for Lower Lip Reconstruction

4. Barry ZM: Deformities of the lips and the cheeks: Plastic Surgery, Vol. 3, part 2, W.B. Saunders, pp. 2012 – 2026, 1990.
5. Blackwell KE, Buchbinder D, Biller HF, Urken ML: Reconstruction of massive defects in the head and neck: The role of simultaneous distant and regional flaps. *Head & Neck* Oct 19(7): 620-28, (abstr) 1997.
6. Santamaria E, Granados M, Barrera-Franco JL: Radial forearm free tissue transfer for head and neck reconstruction: versatility and reliability of a single donor site. *Microsurgery* 20 (4): 195-201, (abstr) 2000.
7. Carroll CN, Pathak I: Reconstruction of total lower lip and chin defects using the composite radial forearm-palmaris longus tendon free flap. *Arch Facial Plast Surg* Jan-Mar 2(1): 53-56 (abstr), 2000.
8. Shinohara H, Iwasawa M, Kitazawa T, Kushima H: Functional lip reconstruction with a radial forearm free flap combined with a masseter muscle transfer after wide total excision of the chin. *Ann Plast Surg* Jul: 45 (1): 71-73 (abstr), 2000.
9. Weinzweig N, Chen L: Lower face reconstruction using a neurosensor osteocutaneous radial forearm flap and Webster modification lip repair. *Plast Reconstr Surg* Oct 94 (5): 685-90, (abstr) 1994.
10. Hafezi F, Naghibzadeh B, Nouhi A: Facial reconstruction using the visor flap. *Burns* Nov 28(7): 679-83, (abstr) 2002..
- 11 ) Kudo K, Yokota M, Fujioka Y: Immediate reconstruction using a scalp-forehead flap for the entire upper lip defect with the application of lyophilized porcine skin to surgical wounds. A case report of a malignant melanoma in the upper lip and oral mucosa. *J Maxillofac Surg* De 11(6): 275-8, (abstr) 1983.
12. Lore JM, Jr, Medina JE: *An Atlas of Head & Neck Surgery*, 4th ed, 2005.