



Successful treatment using Actinomycin D in a case of methotrexate-resistant ectopic pregnancy: A case report

Soheila Aminimoghaddam*¹, Ara Omranipoor²

Received: 3 Jan 2019

Published: 23 Sep 2019

Abstract

Ectopic pregnancy is an urgent clinical condition that represents a serious hazard to reproductive power, and thus threatens woman's health. Commonly, methotrexate is considered for early resolution of placental tissue. Despite its potential advantages such as minimizing hospitalization and quick recovery, its high skin and gastrointestinal side-effects and requiring time monitoring may limit its application. Recently, high effectiveness of the single-agent chemotherapy agents, such as Actinomycin D, has been suggested. Herein, a case of methotrexate-resistant EP that was successfully treated with Actinomycin D was described.

Keywords: Ectopic pregnancy, Actinomycin-D, Beta HCG

Conflicts of Interest: None declared

Funding: None

**This work has been published under CC BY-NC-SA 1.0 license.*

Copyright© Iran University of Medical Sciences

Cite this article as: Aminimoghaddam S, Omranipoor A. Successful treatment using Actinomycin D in a case of methotrexate-resistant ectopic pregnancy: A case report. *Med J Islam Repub Iran.* 2019 (23 Sep);33:100. <https://doi.org/10.47176/mjiri.33.100>

Introduction

Ectopic pregnancy (EP) is an urgent clinical condition that represents a serious hazard to reproductive power, and thus threatens woman's health. Because of its related adverse clinical consequences, early and prompt diagnosis followed by early aggressive intervention is the choice treatment approach to manage this condition (1). Both congenital factors (tubal hypoplasia, elongation, stenosis, accessory ostia, diverticula, polyps, and tortuosity) and acquired factors (pelvic inflammatory disorders, contraceptive failure, sterilization failure, and reproductive inducing interventions) affect the incidence of EP (2). Due to serious complications of EP, including tubal rupture, massive hemorrhage, severe hemodynamic instability and

death, early management of EP, which is done by both medical and invasive interventional approaches, is recommended to reduce fatality rate. Two medical and surgical approaches are now used to manage EP (3). In medical approach, both local and systemic medications, such as methotrexate, potassium chloride, prostaglandins, hyperosmolar glucose, and mifepristone, are used (4). Methotrexate is commonly considered for early resolution of placental tissue. However, despite its potential advantages, such as minimizing hospitalization and quick recovery, its high skin and gastrointestinal side-effects and requiring time monitoring may limit its application (5, 6). Moreover, some cases of complete failure of this medical ap-

Corresponding author: Dr Soheila Aminimoghaddam, aminimoghaddam.s@iums.ac.ir

¹ Department of Gynecology Oncology, Iran University of Medical Sciences, Tehran, Iran

² Firoozgar Hospital, Department of Gynecology Oncology, Iran University of Medical Sciences, Tehran, Iran

↑What is “already known” in this topic:

Some studies addressed using MTX for treating EP, while a few studies investigated the applicability of using Actinomycin -D for treating EP.

→What this article adds:

Other scholars used MTX or Actinomycin-D for treating low-risk GTN. Also, some studies addressed using MTX for treating EP, while a few studies investigated the applicability of using Actinomycin-D for treating EP. Evaluating this approach was the main aim of this study. For this purpose, the level of toxicity and the BHCG level were measured. The results of this study showed that the level of toxicity was low and the level of BHCG was reduced fast. The results and the approach have made this study unique.

proach have also been reported. Recently, high effectiveness of the single-agent chemotherapy agents, such as Actinomycin D, has been suggested (7, 8). Some studies have even indicated that Actinomycin D could induce remission more than methotrexate (9-14). Herein, a case of methotrexate-resistant EP that was successfully treated with Actinomycin D was described. The new message of this paper is about Actinomycin D for medical treatment of EP. Other scholars used MTX or Actinomycin-D for treating low-risk GTN. Also, some studies addressed using MTX for treating EP, while a few studies investigated the applicability of using Actinomycin-D for treating EP. Evaluating this approach was the main aim of this study, and for this purpose, the level of toxicity and BHCG level were measured.

The results of this study showed that the level of toxicity was low and the level of BHCG was reduced fast. The obtained results and the used approach have made this study unique.

Case report

The case described in this report was a 30-year-old woman (G6AB3EP2) with a history of curettage (2 times) due to invisibility of FHR, one spontaneous abortion and 2 left tubal EP, which were successfully managed by methotrexate administration. The patient was submitted having a delayed menstruation and a β HCG level of 1720 IU/L. Transvaginal sonography revealed an eccentrically located

in the gestational sac at the superior fundal level of the uterus surrounded by 4 mm myometrial tissue and separate empty uterine cavity. EP was finally confirmed. Hence, the patient received a multidose treatment regimen of methotrexate (60mg) and leucovorin (6mg). However, the detection of raising β HCG level to 2210 IU/L and 6800 IU/L 2 and 4 days after initial treatment, respectively, convinced the patient to refer to the hospital due to the failure of drug therapy. Based on the sonography reports on admission, GS was not found in imaging, but an echogenic mass with the dimensions of $26 \times 28 \text{ mm}^2$ was found in the superior fundal level of the right uterine cornea (transitional zone), with a 4.5 mm echo free region suspecting right interstitial EP. At the first day of admission, the patient had a β HCG level of 6800IU/L, which was also revealed by TVS an EL with the diameter of 12 mm and an echogenic lesion sized 26 mm, indicating a right interstitial EP. Due to the lack of response to the standard treatment, pulse treatment regimen was performed again. Methotrexate was started with the dosage of 85 mg one day after admission, and β HCG level was rechecked 4 and 7 days later, which reached to 6946IU/L and 6500IU/L, respectively. One day after methotrexate injection, assessing intrauterine cavity by TVS and MRI (Fig. 1) revealed an intramural heterogenic zone consisting small cystic regions sized $39 \times 38 \times 35 \text{ mm}^3$ at right interstitial region, suggesting interstitial EP surrounded by a narrow band of the myometrium (Fig. 2). A second dose

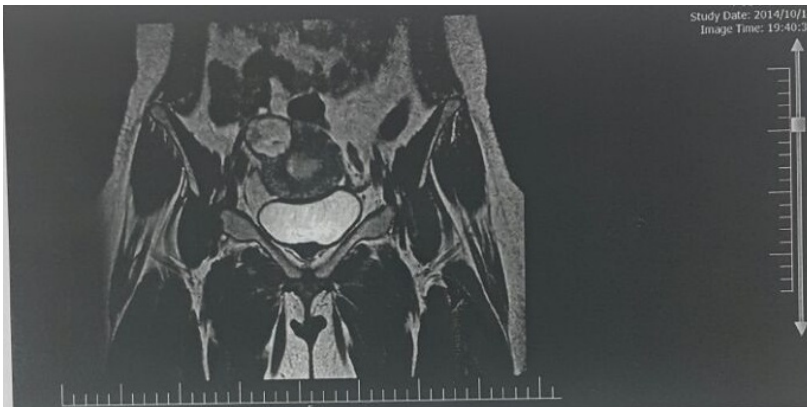

Fig. 1. Sagittal view of pelvic MRI

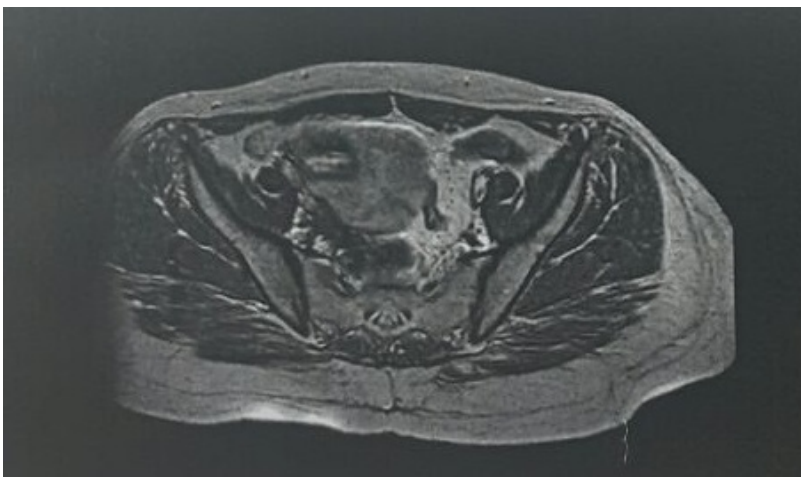


Fig. 2. Coronal view of pelvic MRI

was administered on day 7. A partially decreasing trend of β HCG level was noticed a few days after treating with methotrexate (6400 IU/L in the 11th day and 6300 IU/L in the 14th day). Finally, considering the inappropriate response to methotrexate and lack of change in the condition of the mass, the patient was treated with intravenous Actinomycin D (2 g). On the day of injection, bleeding and disposing the tissues sized 3 to 4 cm were observed, confirming decidual reaction in pathological assessment. A week after administrating Actinomycin D, the level of β HCG reached to 910 (IU/L). The downward trend of β HCG continued which was less than 4 (IU/L) after 2 weeks. The sonography performed on discharge showed a mass sized 43 ×40 mm with a good general condition, stable hemodynamics, and lack of clinical manifestations such as abdominal pain. β HCG was rechecked 6 months later and was negative.

Conflict of Interests

The authors declare that they have no competing interests.

References

1. Dialani V, Levine D. Ectopic pregnancy: a review. *Ultrasound Q*. 2004 Sep;20(3):105-17.
2. Rana P, Kazmi I, Singh R, Afzal M, Al-Abbasi FA, Aseeri A, Singh R, Khan R, Anwar F. Ectopic pregnancy: a review. *Arch Gynecol Obstet*. 2013 Oct;288(4):747-57.
3. Sivalingam VN, Duncan WC, Kirk E, Shephard LA, Horne AW. Diagnosis and management of ectopic pregnancy. *J Fam Plan Reprod Health Care*. 2011 Oct;37(4):231-40.
4. Bachman EA, Barnhart K. Medical management of ectopic pregnancy: a comparison of regimens. *Clin Obstet Gynecol*. 2012 Jun;55(2):440-7.
5. Atkinson M, Gupta S, Megee T. β hCG monitoring after single-dose methotrexate treatment of tubal ectopic pregnancy: is the Day 4 β hCG necessary? A retrospective cohort study. *Aust N Z J Obstet Gynaecol*. 2014 Oct;54(5):475-9.
6. Aminimoghaddam S, Norouzi S. Ovarian failure due to cancer treatment and fertility preservation options. *Tehran Uni Med J*. 2016;74(1):1-8.
7. Tanaka K, Baartz D, Khoo SK. Management of interstitial ectopic pregnancy with intravenous methotrexate: An extended study of a standardised regimen. *Aust N Z J ObstetGynaecol*. 2015 Apr;55(2):176-80.
8. Aminimoghaddam S, Norouzi S, Fayazi A. Outcome of pregnancy subsequent to chemotherapy with actinomycin-D in low risk gestational trophoblastic neoplasia. *Tehran Uni Med J*. 2017;75(4):273-279.
9. Brand E, Gibbs RS, Davidson SA. Advanced cervical pregnancy treated with actinomycin-D. *Br J Obstet Gynaecol*. 1993 May;100(5):491-2.
10. Aminimoghaddam S, Nezhadislami F, Anjidani S, Tond SB. Outcome of treatment with EMA/EP (etoposide methotrexate and actinomycin-D/etoposide and cisplatin) regimen in gestational trophoblastic neoplasia. *Med J Islam Repub Iran*. 2018;32:36.
11. Koba M, Konopa J. Actinomycin D and its mechanisms of action. *Postepy Hig Med Dosw (Online)*. 2005;59:290-8.
12. Fujioka S, Yamashita Y, Kawabe S, Kamegai H, Terai Y, Ohmichi M. A case of a methotrexate-resistant ectopic pregnancy in which dactinomycin was effective as a second-line chemotherapy. *Fertil Steril*. 2009 Mar;91(3):929.
13. Neary BA, Rose PG. Complete response of a persistent ectopic pregnancy to dactinomycin after methotrexate failure: A case report. *J Reprod Med*. 1995 Feb;40(2):160-2.
14. Ghaoomi M, Aminimoghaddam S, Safari H, Mahmoudzadeh A. Awareness and practice of cervical cancer and Pap smear testing in a teaching hospital in Tehran. *Tehran Uni Med Sci J*. 2016;74(3):183-9.