

## Reintroducing the latissimus-rib free flap as a long bone substitute in the reconstruction of lower extremity injuries

Shahram Nazerani, MD,<sup>1</sup> Amir R. Motabar, MD.<sup>2</sup>

*Department of General Surgery, Iran University of Medical Sciences, Tehran, Iran.*

### Abstract

The leg is a complex district with functions of weightbearing support, stability, and motility. The management of extensive and complex defects is more challenging and often results in leg amputation or shortening. Leg amputation is a severe mutilation that alters the patient's work and social life by limiting ambulation and self-sufficiency. During a 3 years period we treated four patients with leg injury consisting of tibial defect who underwent one-stage surgery for soft tissue and bone reconstruction. The follow-up period was from 31 to 36 months. Time to bony union ranged from 4 to 7 months. Time to full weight bearing was from 5 to 9 months after operation. All of the transferred tissue showed hypertrophy after weight bearing. Nonunion & abscess occurred in one case. Arterial thrombosis & valgus deformity were other postoperation complications. The limb was shorter by an average of 0.5 cm in three cases, longer by 1.1 cm in one case, and in the last case, it was not measurable. Other disabling complications were not seen. We believe that this forgotten method can be a valuable alternative to other techniques such as free fibula flap in certain cases that the surgeon can reconstruct bone & soft tissue defects in one stage.

**Keywords:** free rib flap, tibial injury, reconstruction.

### Introduction

The treatment of complicated fractures in the lower leg depends on many factors such as the energy of the trauma, the anatomic location and morphology of the fracture, the degree of displacement and soft-tissue injury, concomitant injuries and diseases, the age of the patient, and the surgical facilities available. Problems faced by surgeons treating such fractures include soft- and bone-tissue defects, delayed union or nonunion, malalignment, shortening, and os-

teomyelitis. In the past, the vast majority of massive lower leg injuries resulted in amputation. The introduction of free microvascular tissue transfer 20 years ago has enabled hundreds of legs with severely complicated tibial fractures to be salvaged [1]. Small bone defects of the tibia are treated with external fixation and cancellous bone grafting, with satisfactory results.

The management of extensive and complex defects is more challenging and often results in leg amputation or shortening. Leg amputation is a severe mutilation that alters the patient's

1. Assistant Professor of General Surgery, Department of Surgery, Iran University of Medical Sciences, Firozgar Hospital, Tehran, Iran. email: Nazerani@netscape.net

2. **Corresponding author**, Resident of General Surgery, Department of Surgery, Iran University of Medical Sciences. Hazrat-e-Rasool-e-Akram Hospital, Niyayesh Street, Tehran, Iran. Tel:+98912 1500971, email: motabar@yahoo.com.

work and social life by limiting ambulation and self-sufficiency. In cases of complex injuries of the leg with destruction of soft tissue & bone patients usually require more than one operation but we suggest a forgotten method, i.e., with chimera flap in which we can substitute skin, muscle & bone in a one stage operation.

### Technique

The LD muscle is a type 3 muscle of Nahai classification, with one major vascular supply and several minor ones, this muscle is almost always transferred on its major blood supply, the thoracodorsal vessels, but it can also be harvested on its minor pedicles which are perforators of intercostal arteries. In our series we have harvested the muscle using standard technique but the minor pedicles have been saved for one or two ribs and the ribs had been harvested with their intercostal arteries intact so when the rib is elevated off the chest wall it has its blood supply reestablished from the LD muscle connecting branches as confirmed by arterial bleeding from the cut ends of the ribs. When there is need for two ribs every other rib is harvested so chest wall collapse is prevented. Bisecting or trisecting of the rib is possible as has been performed in two of our cases.

### Case report

We report 4 cases of leg crush injury during 2003-2006 due to motor-car accident or pedestrian car accident.

#### Case 1

A 24-year old man, a car driver, was admitted to our hospital for upper leg injury with a 10 cm defect in the tibial bone. We found also skin loss & soft tissue injury. We used the right latissimus dorsi muscle and rib beneath it with vascular pedicle and two levels up of nonvascularized ribs were also harvested. After vascular anastomosis to the popliteal vessels external fixation was used. The patient had an uneventful postoperation period. Three months later he

has started walking.

#### Case 2

Another case was a 3 year old child admitted by major trauma to the left lower leg and ankle. A chimera flap of latissimus dorsi and two ribs were taken from the right chest wall and transferred to the leg, then the vascular pedicle was anastomosed to the posterior tibialis artery and vein.

After a year we reoperated the patient for correction of severe valgus deformity and defect. A year later he started walking normally.

#### Case 3

A 23-year-old man presented with proximal left leg traumatic injury leading to an 8 cm defect in the proximal tibia with skin & muscle loss. After harvesting the right latissimus dorsi & rib beneath it the rib from two levels higher was also harvested. The composite was transferred to the defect. After bone fixation the flap vessels were anastomosed to the popliteal artery & vein. The defect was resurfaced with a skin graft. Two weeks later we reoperated the patient for arterial graft thrombosis. And 4 months later for removal of the plate for treatment of osteomyelitis. Postoperatively the flap survived completely, with primary healing, and the patient began weight bearing at 8 weeks.

#### Case 4

An 18-year-old man presented with traumatic avulsion of his heel, with the calcaneal bone involved. The defect had been left to heal by secondary intention due to technical difficulties. When he came to us, a soft tissue defect of 5×5 cm<sup>2</sup> size was present at the calcaneal region. The bone defect was about 10cm and was substituted with an osteomuscular rib free flap. The defect was resurfaced with a distal-based posterior tibial fasciocutaneous flap. Postoperatively the flap survived completely, with primary healing, and the patient began weight bearing at 4 weeks. At the last follow-

up, 25 months postoperatively, the flap had healed well without trophic ulceration although no sensory nerve anastomosis was performed. There was proprioceptive sensation and ability to detect deep pressure.

### Results

We should mention that in all cases we used the fifth and sixth rib and the fourth also in two cases. Approach was from the right posterolateral chest wall from the midaxillary line through the posterior axillary line. In operated patients, all the flaps survived. There was no gross ischemia (except in the distal zone of one flap). All patients were immobilized throughout the operation. According to the main disease of the patients, mobilization periods were balanced to prevent the damage of the flaps and fractured bone. Mean immobilization period was 21 days in three patients, and in the other, there was a distal tibiofibular fracture, and this period was extended until 4 weeks. At follow-up, there were no complications related to the flap and patients. All operated flaps were sensate. The follow-up period was from 31 to 36 months. Time to bony union ranged from 4 to 7 months. Time to full weight bearing was from 5 to 9 months after operation. All of the transferred tissue showed hypertrophy after weight bearing. Nonunion occurred in one case, which was treated with a long leg cast. Arterial thrombosis was another complication that happened one week after surgery and lead to ischemia of the flap but it resolved spontaneously. One of the patients had another operation to correct severe valgus deformity. The limb had been shorter by an average of 0.5cm in three cases, longer by 1.1 cm in one case, and in the last case, it was uncheckable because the opposite limb had been previously amputated. Limited arc of rotation was not a problem. Other disabling complications were not seen. There is no need for a sensation test of two point discrimination since all these flaps are located in nonweight bearing areas such as the tibial plateau or medial of the

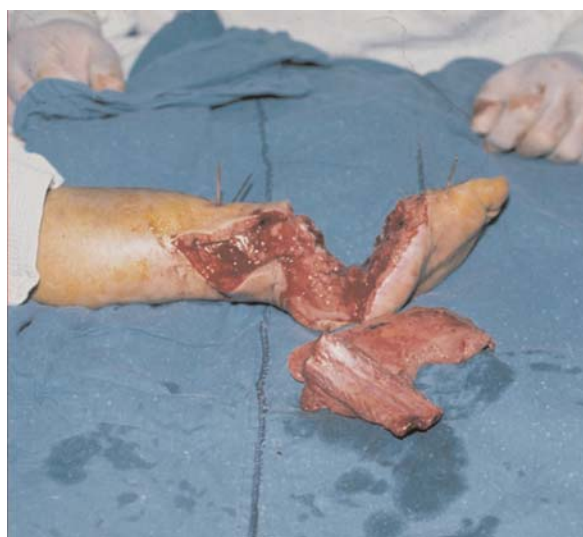

Fig.1. Two ribs were harvested and prepared for transposition.

foot.

### Discussion

The introduction of free microvascular tissue transfer 20 years ago has enabled hundreds of legs with severely complicated tibial fractures to be salvaged [1].

The first successful microvascular transplantation was performed in 1973, and since then, free flaps have been used to cover soft-tissue defects in open tibial fractures and to manage infected fractures of the tibia[2-8]. In early experience, the free flap failure rate was between 8% and 9% with an amputation rate of 5% to 6%. Free vascularized fibular transfer has become the standard practice to bridge long (>6 cm) bone defects of the extremities [9,12].

In the 1970s, microsurgical techniques were mainly used in emergency settings to reestablish the vascular perfusion of amputated limbs and salvage them. Complex tibial fractures or extensive bone defects were usually treated by orthopedic surgeons with autologous nonvascularized cancellous bone grafting stabilized with external fixation. Complex open fractures of the tibia were associated with an increased incidence of delayed union (20-40%),

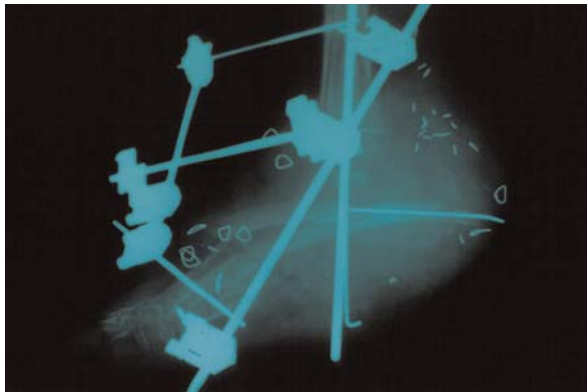


Fig. 2. Internal and external fixation.

nonunion (7-45%), and osteomyelitis (2.7-27%). These contributed to a high incidence of delayed amputation, ranging from 20-75% [13].

Later, cortical bone grafting with rigid internal fixation was introduced. The early results of the use of the fibula graft for the tibia appeared satisfactory. In 1980, Enneking et al reported a 95% success rate in the postneoplastic reconstruction of tibial gaps greater than 7.5cm with large, nonvascularized fibular autografts. This procedure demonstrated several complications, such as stress fractures (32%), bone nonunions (27% at 6 months), and tibial curvatures [14]. To reduce the complication rate, which increased in infected and poorly vascularized wounds, the use of free bone transfer microsur-gically revascularized to the recipient area was proposed.

In 1973, Ueba and O'Brien evaluated the fibula as a donor site for the free microvascular bone flap [13]. The first report of a successful free bone transplant was in 1974 by Ostrup and Fredrickson, who successfully transplanted free rib grafts vascularized on intercostal arteries in dogs [14].

In 1975, Taylor et al performed the first 2 free microvascular fibula transfers on human patients to reconstruct tibial bone gaps. Microvascular bone flaps were shown to heal more rapidly, with fewer complications and earlier functional recovery than conventional nonvascular-

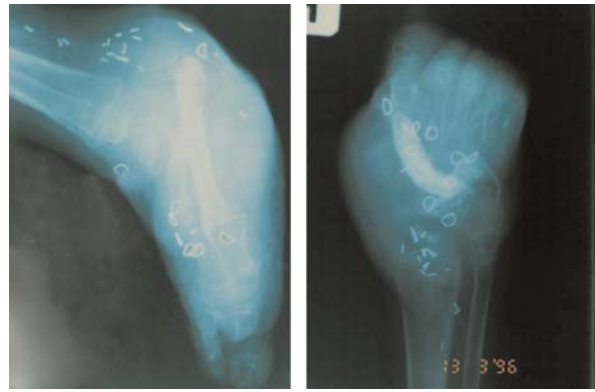


Fig. 3. Two months later.

ized grafts[15]. Gradually, microvascular bone flaps have gained popularity, becoming the treatment of choice for bone defects larger than 6 cm or located in poorly vascularized and contaminated wound beds.

The first free rib transfer was done in 1979 by G.Ian Taylor from Australia which is around 30 years ago.

The reconstruction of partially comminuted fractures or small bone gaps usually benefits from cancellous or devascularized cortical bone grafting and external fixation.

On the contrary, the reconstruction of segmental, comminuted tibial fractures or extensive bone defects requires vascularized bone grafts to overcome infection and restore bone continuity and blood supply. The Ilizarov technique is a procedure used for the reconstruction of such defects, but the bulky apparatus, long lengthening and union times, and pin tract infection limit the present method.

Generally, the goal in the reconstruction of tibial defects is to restore the anatomy of the altered segment, gaining a satisfactory functional recovery. Finding a bone substitute of adequate length and width, customized to the defect, covered by vascularized muscle or skin, and stabilized in the most anatomic position compatible with maximal functional return is often a great demand. Currently, microvascular free bone grafts are the best answer.

The classification of tibial fractures consid-

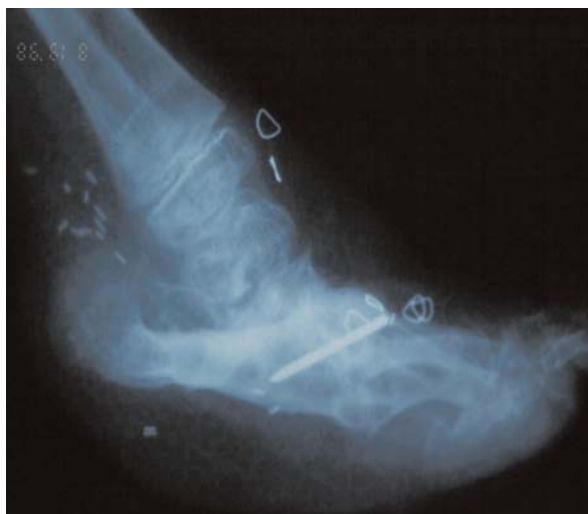

Fig. 4. Six months after operation.

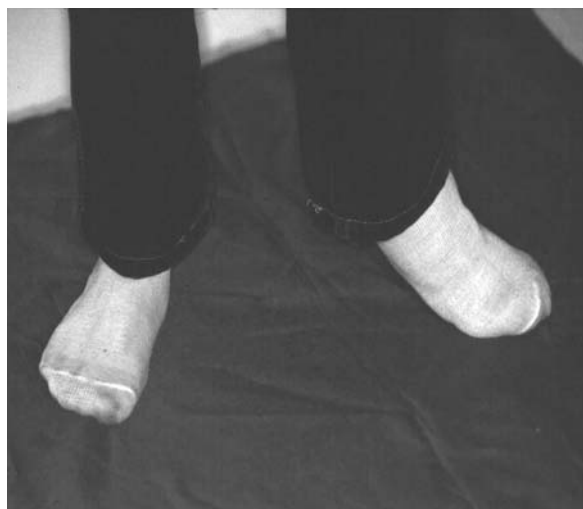

Fig. 5. Nine months later. Time to full weight bearing.

ers the mechanism of the trauma, the location, the extent and type of fracture, involvement of soft tissues, and neurovascular impairment. The type of tibial fracture is related to the mechanism involved in its pathogenesis, ie, contusive, clean-cut, tear, degloving, crushing, avulsion, and burst (high speed). Usually, crushing, avulsions, or high-speed bursting injuries lead to more complex defects.

Conventional treatments (i.e, bone grafting, Ilizarov technique) are best indicated for limited (<6 cm) defects because of the long time needed for newly formed bone to consolidate.

Microsurgical bone transfers are indicated when conventional treatments are not useful (ie, bone defect >6 cm, poorly vascularized or infected recipient beds) or have previously failed.

Primary indications for free bone transfer to tibial defects are as follows:

- Severely comminuted fractures or wide bone loss greater than 6 cm (grade 3a-3c from Gustilo classification, type III from Byrd classification)

- Wide (>6 cm) en bloc tibial resections for cancer.

- Wide bone resection (>6 cm) for congenital pseudoarthrosis of the tibia.

Secondary indications for free bone transfer

are as follows:

- Wide bone resection of acquired pseudoarthrosis or chronic osteomyelitis following nonunions for failed conventional treatment of fractures,

- Short limb (>6 cm) following conventional treatment of fractures or reimplantation of an avulsed limb, with or without distraction,

- Amputation stump lengthening,

- Wide soft tissue coverage of bone defects (<6 cm) of the lower third of the leg (osteocutaneous, myo-osteocutaneous flap)[14].

Timing of reconstruction in open fractures has always been a matter of discussion. In fact, performing primary closure of traumatic wounds with tissue viability that is still in question is often discouraged; however, primary flap coverage within 72 hours has been determined to yield better results and a lower infection rate than delayed or late closure. Therefore, an early reconstruction may underestimate or overestimate the amount of bone to excise and replace, while a delayed reconstruction may be at higher risk of infective and vascular complications. The timing of bone reconstruction depends on the time passed from injury at the first referral of the patient, on soft tissue involvement and viability, and on the width of the bone gap to be filled [15].

Within the first 72 hours after the trauma, simple lesions with limited or no soft tissue involvement are treated immediately with radical debridement and bone grafting or bone flap transfer in one stage. Complex lesions with soft tissue involvement are treated with muscle free flap and delayed bone grafting or a one-stage free osteomyocutaneous flap.

Patients referred 72 hours after trauma usually present with infected wounds and require debridement and delayed reconstruction. In summary, the following options are available:

- Immediate reconstruction (within 72 h)
- One-stage surgery - Soft tissue and bone reconstruction (muscle flap and bone grafts/osteocutaneous-osteomyocutaneous flap),
- Two-stage surgery - Soft tissue cover (pedicled free muscle flap); bone reconstruction (bone graft/flap).

Usually, reconstruction of the tibia for open fractures is a function of the characteristics of the bone gap (>6 cm) resulting from wound debridement and fracture reduction and of the characteristics of soft tissue damage (local or free flap).

Soft tissue reconstruction has been clearly demonstrated to affect fracture healing and callus formation in open fractures. For defects of the superior third of the leg, use of the medial/lateral gastrocnemius, free muscle flap, or free osteocutaneous fibula has been recommended. For defects of the middle third of the leg, use of a soleus flap, a free muscle flap or free osteocutaneous fibula has been recommended. For defects of the inferior third of the leg, use of a free muscle flap or free osteocutaneous fibula has been recommended.

### Conclusion

Upper tibia large bone and soft tissue defects are the main indication of this flap which brings a large muscle and skin coverage to the leg and also a vascularized bone which can be divided in up to six parts when two ribs are transferred. These struts when arranged near each other can

almost completely fill the upper tibia bone defects. Transferring the fibula with its scarce muscle coverage needs an additional free flap with the increased operating time and hazard of two free flaps at one setting. The second option which is favored by orthopedic surgeons is covering these defects with a muscle only flap and at a second stage bone transport is performed, which is a very difficult and time consuming method in these scarred tissues.

We conclude that, this forgotten procedure can be a suitable technique in tibial complex injuries. In one stage the surgeon could fill the defect by this kind of chimera flap. There is no need to do another operation except for controlling postoperation complications.

### References

1. Hicks JH. Amputation in fractures of the tibia. *J Bone Joint Surg Br* 1964; 46: 388.
2. Daniel RK, Taylor IG. Distant transfer of an island flap by microvascular anastomoses. *Br J Plast Surg* 1973; 78: 285
3. Yaremchuk MJ. Acute management of severe soft tissue damage accompanying open fractures of the lower extremity. *Clin Plast Surg* 1986; 13: 621.
4. Babovic S, Johnson CH, Finical SJ. Free fibula donor-site morbidity: the Mayo experience with 100 consecutive harvests. *J Reconstr Microsurg* 2000; 16 (2): 107-10
5. Khouri RK, Shaw WW. Reconstruction of lower extremity with microvascular free flaps: a 10-year experience with 304 consecutive cases. *J Trauma* 1989; 29:1086.
6. Boeckx W, Blondeel PH, Van Raemdonck D, et al. The use of free flaps in the treatment of severe lower leg trauma. *Eur J Plast Surg* 1992; 15: 63.
7. Francel TJ, Vander Kolk CA, Hoopes JE, Manson PN, Yaremchuk MJ. Microvascular soft tissue transplantation for reconstruction of acute open tibial fractures: timing of coverage and long-term functional results. *Plast Reconstr Surg* 1992; 89:1
8. Wiss D, Sherman R, Oechsel M. External skeletal fixation and rectus abdominis free-tissue transfer in the management of severe open fractures of the tibia. *Orthop Clin North Am* 1993; 24: 549.

9. Asko-Seljavaara S, Slatis P, Kannisto M, Sundell B. Management of the infected fractures of the tibia with associated soft tissue loss: experience with external fixation, bone grafting and soft tissue reconstruction using pedicle muscle flaps or microvascular composite tissue grafts. *Br J Plast Surg* 1985; 38: 546-555.
10. Anthony JP, Mathes JM, Alpert SA. The muscle flap in the treatment of chronic lower extremity osteomyelitis: results in patients over 5 years after treatment. *Plast Reconstr Surg* 1991; 88: 311-318.
11. Koval KJ, Meadows SE, Rosen H, Silver L, Zuckerman JD. Posttraumatic tibial osteomyelitis: a comparison of three treatment approaches. *Orthopedics* 1992;15: 455.
12. Nieminen H, Kuokkanen E, Tukiainen E, et al. Free flap reconstructions of tibial fractures complicated after internal fixation. *J Trauma* 1995; 38: 660.
13. O'Brien BMcC. *Microvascular Reconstructive Surgery*. New York: Churchill Livingstone; 1977.pp. 142-152.
14. Organek AJ, Klebuc MJ, Zuker RM. Indications and outcomes of free tissue transfer to the lower extremity in children: review. *J Reconstr Microsurg* 2006; 22 (3): 173-81.
15. Taylor GI, Miller GD, Ham FJ. The free vascularized bone graft. A clinical extension of microvascular techniques. *Plast Reconstr Surg* 1975; 55 (5): 533-44