



## Parotid gland metastasis as an initial presentation of renal cell carcinoma: A case report

Hala Halbony\*<sup>1</sup>, Mutaz Albrezat<sup>2</sup>, Dima Hmaid<sup>2</sup>, Nader Albsoul<sup>2</sup>

Received: 27 Apr 2019

Published: 28 Dec 2020

### Abstract

This report is to describe a rare case of parotid metastasis from renal cell carcinoma (RCC) in a 50-year-old male presenting with unilateral facial symptoms. Following investigations, the patient was diagnosed to have metastatic renal cell carcinoma. He was planned for radio-chemotherapy, and got deceased 1 year afterward.

**Keywords:** Parotid, Renal cell carcinoma, Metastasis

**Conflicts of Interest:** None declared

**Funding:** None

**\*This work has been published under CC BY-NC-SA 1.0 license.**

Copyright © Iran University of Medical Sciences

**Cite this article as:** Halbony H, Albrezat M, Hmaid D, Albsoul N. Parotid gland metastasis as an initial presentation of renal cell carcinoma: A case report. *Med J Islam Repub Iran.* 2020(28 Dec);34:175. <https://doi.org/10.47176/mjiri.34.175>

### Introduction

Renal cell carcinoma (RCC) accounts for 3% of all adulthood malignancies, and for 85% of primary renal tumors (1). The incidence of RCC increases with age with a peak in the sixth decade of life; epidemiological data reveal a male predominance (2:1) (2, 1). RCC is known for its aggressive behavior, where about one-third of patients present with metastatic disease (2). Metastasis usually occurs via hematogenous and lymphatic dissemination (3). Metastasis to the salivary glands is uncommon, accounting for 5% of all malignant tumors at that site. When salivary glands are involved, the parotid gland is the most frequently affected gland (2). Herein, we present a case of parotid metastasis from RCC as a first presentation.

### Case report

A 50-year-old male was referred to the Department of General Surgery at Jordan University Hospital,

Amman, Jordan, complaining of right lower lip paresthesia and right facial pain radiating to the right ear of five-month duration. The patient was diagnosed in the private sector to have trigeminal neuralgia and was treated by Carbamazepine for two months. A month prior to admission, the patient started developing right facial swelling. Physical examination revealed right non-tender immobile parotid swelling without overlying skin changes. Trismus, right cervical and supraclavicular lymphadenopathy were also noted. There was no facial weakness. The patient has lost 20 kg over the last 2 months prior to admission.

Lab tests were performed and revealed hypercalcemia (calcium 12.20 mg/dL), hypoparathyroidism (PTH 5.6 pg/mL), elevated aspartate aminotransferase (AST 110 u/lit) and lactate dehydrogenase (LDH 349 u/lit) were also noted.

Right parotid gland fine-needle aspiration cytology

**Corresponding author:** DrHala Halbony, [hala.halbouni@yahoo.com](mailto:hala.halbouni@yahoo.com)

<sup>1</sup> University of Jordan, Amman, Jordan

<sup>2</sup> Kahramanmaraş Sutcu Imam University, Kahramanmaraş, Turkey

#### ↑What is “already known” in this topic:

When a parotid mass with neurological manifestations is encountered, a wide differential diagnosis spectrum has to be considered.

#### →What this article adds:

Despite being an extremely rare finding, initial presentation due to parotid localization from primary Renal Cell Carcinoma should be considered to prevent delay in treatment and hence poor prognosis.




Fig. 1. 1-Pictures of FNA cytology slides stained with hematoxylin and eosin stain (4), 2-Pictures of FNA cytology slides stained with PAP stain (4)

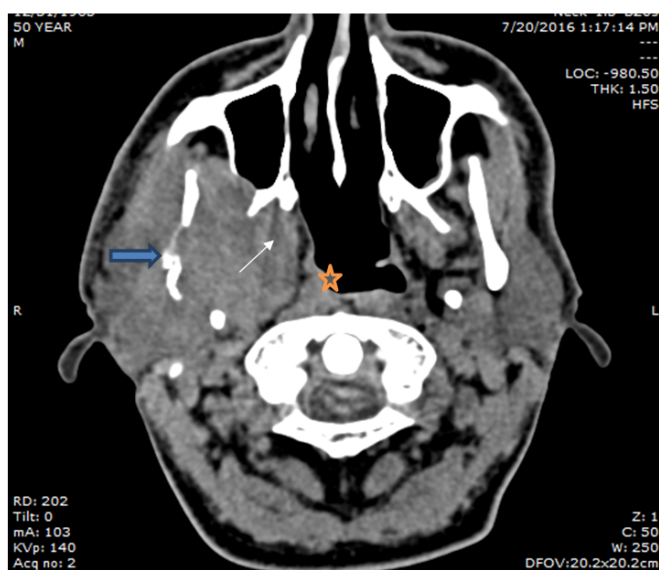


Fig. 2. Large heterogeneously enhancing soft tissue lesion involving the right pterygoid muscle (arrow) and masseter muscle (broad arrow) with extension to the infratemporal and parapharyngeal spaces, measured (6 \* 5.5 \* 5 cm), causing mass effect on the surrounding structures with obliteration of right fossa of Rosenmüller (star) and right Eustachian tube, the mass has also caused erosion of the ramus of right mandible (5).

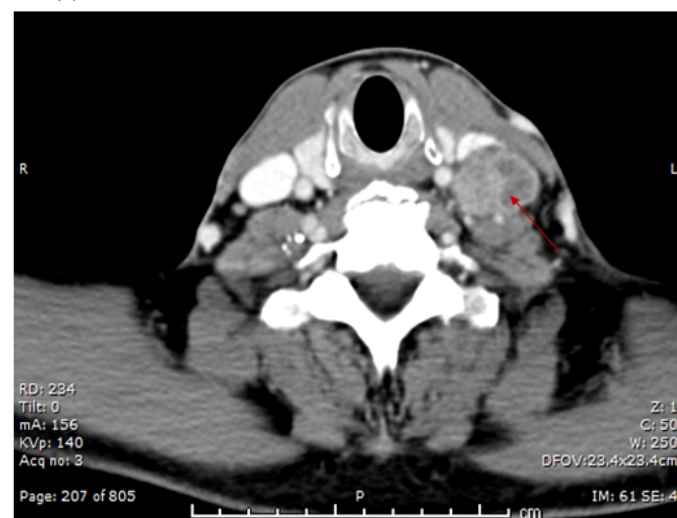

Fig. 3. Multiple bilateral pathologically enlarged supra and infraclavicular lymph nodes (arrow); some of them showed necrotic center with the largest measured 2 cm in the short axis (5).

gy(FNA) was conducted twice due to inadequacy and showed multilayered sheets of cells with eccentric

nuclei, granular cytoplasm, occasional prominent nucleoli and occasional mitotic figures, suspicious for

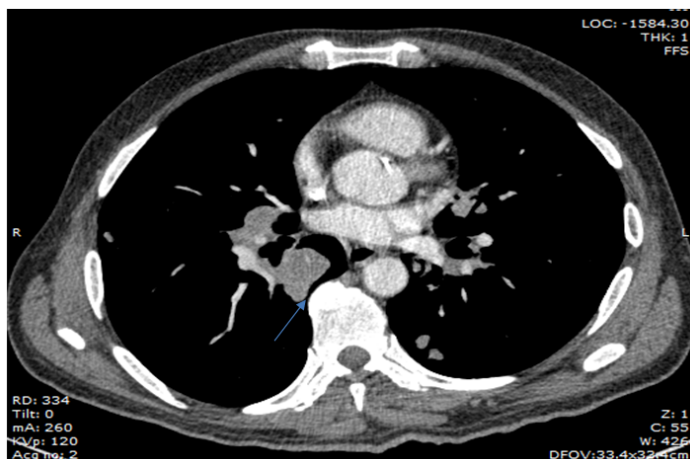


Fig. 4. Multiple significantly enlarged subcarinal lymph nodes and bilateral hilar lymph node enlargement (arrow) (5).

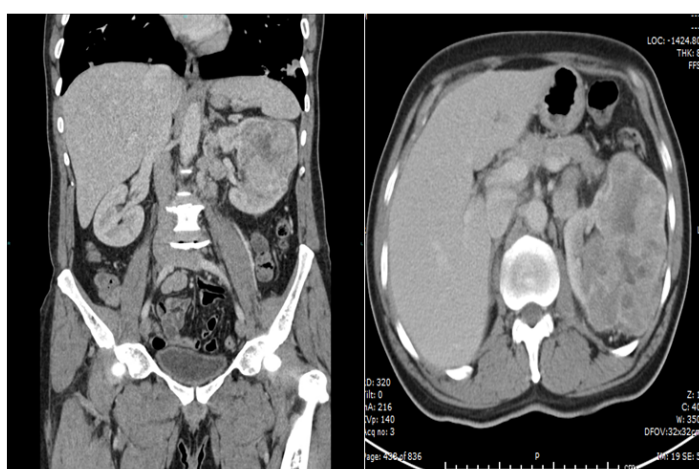


Fig. 5. Large exophytic heterogeneously enhancing lobulated lesion with necrotic components occupying and distorting most of the upper and middle pole of the left kidney (5).

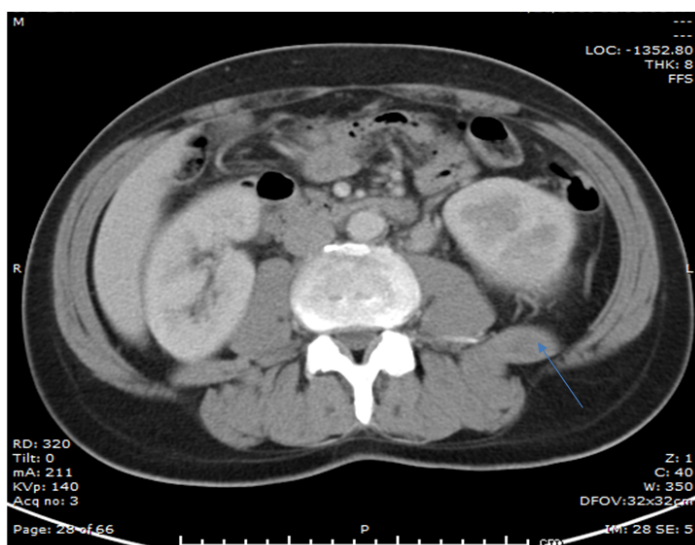


Fig. 6. Multiple tortuous surrounding vessels indicating vascular nature (arrow) (5)

malignancy. The cells were diffusely positive for CD-10 and AMACR with focal positivity for CK7. They were negative for C-kit immunostains. This immune

profile favors RCC over the others.

Microscopically all the slides show a hemorrhagic smear containing scattered sheets and clusters

of plasmacytoid and cuboidal cells having abundant cytoplasm and showing mild nuclear pleomorphism. The cytoplasm is granular and occasionally containing few vacuoles (Fig. 1).

A needle biopsy was done on the left renal mass and revealed Renal Cell Carcinoma with Furman nuclear grade (II/ III). A bone scan also revealed a suspicious lesion involving the right mandibular ramus, multiple bilateral pathologically enlarged supra and infraclavicular lymph nodes with necrotic center with the largest measured 2 cm in the short axis, enlarged subcarinal lymph nodes and bilateral hilar lymph node enlargement. Large exophytic heterogeneously enhancing lobulated lesion with necrotic components occupying and distorting most of the upper and middle pole of the left kidney, were noticed (Figs. 2-6).

### Discussion

Benign and malignant non-salivary gland tumors occur in the parotid area. Benign examples include lipoma, histiocytoma, neurilemmoma, hemangioma, lymphangioma, neurofibroma, and embryoma (6).

Malignant neoplasms account for about 29% of all parotid gland masses; 21-42% of those are metastatic in origin (6, 7). Malignant tumors of lymphatic tissue origin being the most common non-salivary malignancies of the parotid region, chondrosarcoma, neuroblastoma, fibrosarcoma, and malignant melanoma are other malignant tumors presenting in this anatomic region (8). Primary sites below the clavicles are uncommon, and malignant melanoma and squamous cell carcinoma are the most common tumors to metastasize to the parotid gland.

Renal cell carcinoma is the most common solid renal tumor; it originates from the proximal renal tubular epithelium. Clear cell carcinoma is the most common subtype of renal cell carcinoma. The classical triad of renal cell carcinoma is flank pain, hematuria, and a palpable mass. However, this triad is present in only 10-15% of the cases (9, 10). The fact that the kidney receives about 25% of the circulating blood volume per minute, in addition to the release of vascular endothelial growth factor (VEGF) and other angiogenic factors by renal cell carcinoma result in the hypervascularity of these tumors and their association with atriovenous shunts. These factors together contribute to the unique hematogenous route of spread of renal cell carcinoma as a tumor thrombus into the lumen of the inferior vena cava (7). The other route of spread is the lymphatic system (3). The usual sites of metastases are the lung, liver, brain, and bone (6). Bone metastases are osteolytic metastasis, and are usually observed in axial bones, specially T2-L5. Mandibular and maxillary bone metastasis is common; mandibular metastasis from renal origin account for 16% of its metastasis (7).

Metastatic renal cell carcinoma to the head and neck is rare. Most reported cases involve the thyroid gland and to a lesser extent the parotid gland. Metastasis to the sublingual and submandibular glands is extremely rare (8, 10). Other reported sites of renal cell carcinoma

metastasis include the skin, nasal cavity, lips, hard palate, tongue, sinuses, and the tonsils (2). In the post-mortem series of 1451 renal cell carcinoma, Siatoh et al. found ENT metastasis in 5% of the cases, but none had parotid metastasis (7). Renal cell carcinoma is known for its unusual behavior. According to the literature, parotid metastasis may occur prior to or following primary treatment (5).

Patients with metastatic renal cell carcinoma to the parotid gland usually present with a painless palpable parotid mass; however, pain and tenderness may be present. Occasionally, there is an accompanying pulsation, tinnitus, and ipsilateral facial weakness (2). In some cases, multiple masses in the thyroid, submandibular, and sublingual gland may be present as well. One-third of the patients with advanced-stage have bony metastasis causing substantial morbidity including pain, pathological fractures, spinal cord compression, and hypercalcemia (9).

Nowadays, the first choice in the diagnosis of parotid swellings is ultrasonic examination (7). The diagnostic value of fine-needle aspiration biopsy (FNAB) is controversial, as it is associated with a high false-negative rate in the evaluation of metastatic renal cell carcinoma to the parotid gland; this is contributed its vascular nature (3, 10, 11). Pathological examination, immunohistochemical staining with antibodies against CD10, CEA, EMA, CK, and vimentin, are essential even if FNAB is diagnostic (3, 7, 9, 12). Furthermore, the use of PAS and diastase enzyme are helpful in differentiating between primary and metastatic parotid tumors. Imaging (CT/ MRI) can help in the assessment for possible extension or invasion. PET and CT scans are used in evaluating other sites of metastasis (3).

Superficial parotidectomy with preservation of the facial nerve and with disease-free margins is the optimal procedure for isolated parotid metastasis provided the facial nerve is not adhering to the tumor (3, 11, 12, 13). With surrounding tissue invasion, the scope of the parallel operation requires expansion to involve elective lymph node dissection (II-V area) (5). The treatment of diffuse metastatic disease is mainly palliative and includes a combination of chemotherapy, immunotherapy, hormone treatment, and radiation; this is due to the fact that metastatic renal cell carcinoma is often resistant to chemotherapy and radiotherapy (7, 14, 15, 16). Surgical excision is provided to alleviate pain and discomfort along with an aim to avoid complications such as infection and bleeding (16). Bone targeted therapy using bisphosphonates and denosumab can reduce skeletal complications; however, it has no role in improving survival (10).

### Conclusion

The metastatic disease should always be considered in the differential diagnosis of patients presenting with painless salivary or thyroid swelling, especially if they have a history of renal cell carcinoma. Thorough clinical and radiological examination, as well as, the distinction between metastasis and the primary tumor, is

essential for proper diagnosis and hence proper treatment. Finally, the extent of the metastatic burden determines the approach to treatment.

### Conflict of Interests

The authors declare that they have no competing interests.

### References

- Balaban M, Dogruyol SV, Idilman IS, Unal O, Ipek A. Renal cell carcinoma metastasis to ipsilateral parotid and submandibular glands: report of a case with sonoelastographic findings. *Polish J Radiol*. 2016;81:17-2.
- Majewska H, Skálová A, Radecka K, Stodulski D, Hyrcza M, Stankiewicz C, et al. Renal clear cell carcinoma metastasis to salivary glands – a series of 9 cases: clinico-pathological study. *Pol J Radiol*. 2016;81:17–20.
- Hussain F, Yedavalli N, Loeffler D, Kajdacsy-Balla A. Solitary parotid metastasis 8 years after a nephrectomy for renal cell carcinoma. *J Commun Hosp Intern Med Perspect*. 2016;6(4):10.3402.
- Pathology Department, University of Jordan, Amman 11942 Jordan. In press *Med JU JO* 2017.
- Radiology Department, University of Jordan, Amman 11942 Jordan. *Med JU JO* In press 2017.
- Jia-Li SH, Zhou JQ, Li JP. Renal clear cell carcinoma with thyroid and parotid metastases: A case report. *Oncol Lett*. 2015 Oct;10(4):2617-2619.
- Saldaña Rodriguez M, Fe Garcia Reija M, Gonzalez Rodilla I. Primary clear cell carcinoma of parotid gland: Case report and review of literature. *J Oral Maxillofac Pathol*. 2013 Jan-Apr;17(1):101–105.
- Errami M, Margulis V, Huerta S. Renal Cell Carcinoma Metastatic to the Scalp. *Rare Tumors*. 2016 Nov 17;8(4):6400.
- Miah MS, White SJ, Oommen G, Birney E, Majumdar S. Late simultaneous metastasis of renal cell carcinoma to the submandibular and thyroid glands seven years after radical nephrectomy. *Int J Otolaryngol*. 2010;2010:698014.
- Serouya SM, Dultz LA, Concors SJ, Wang B, Patel KN. Late Solitary Metastasis of Renal Cell Carcinoma to the Submandibular Gland. *J Oral Maxillofac Surg*. 2012 Jan 21;70(10):2356-2359.
- Deeb R, Zhang Z, Ghanem T. Metastatic Renal Cell Carcinoma to the Parotid Gland in the Setting of Chronic Lymphocytic Leukemia. *Case Rep Med*. 2012;2012:265708.
- Hosn-Centenero SA, Coll-Anglada M, Pradillos-Garcés A, Salinas-Duffo DA. Rare Case of Renal Cell Carcinoma Metastasis in the Parotid Gland Eleven Years After the Initial Diagnosis. *Acta Otorrinolaringol Esp*. 2014;65(6):375.
- Yanlan C, Liping S, Shaomin C, Zi L. Metastasis to the parotid region as an initial presentation of renal cell carcinoma: A case report. *Oncol Lett*. 2013 Mar;5(3):997–999.
- Gooran S, Yasser AF, Behtash N, Khalili M, Asadi M. Mandibular Mass as an Only Presentation of Metastatic Renal Cell Carcinoma For Four Years: A Case Report. *Urol J*. 2017 Jan 18;14(1):2979-81.
- Chen SC, Kuo PL. Bone metastasis from renal cell carcinoma. *Int J Mol Sci*. 2016 Jun;17(6):987.