

## PEACILOMYCES INFECTION IN AN IMMUNOCOMPROMISED PATIENT

SHAHINDOKHT BASSIRI JAHROMI AND ALIASGHAR KHAKSAR

*From the Department of Medical Mycology, Pasteur Institute of Iran, Tehran, Iran.*

### ABSTRACT

*Paecilomyces* sp. is a saprophytic fungus which has rarely been associated with human disease. We report the first case of invasive subcutaneous infection caused by this fungus in a 78-year-old female from Damghan, Iran, with diabetes and chronic renal failure. A biopsy provided an initial diagnosis of the mold in tissue. Multiple positive fungal cultures which were obtained from the biopsied tissue were subsequently identified by microscopic and macroscopic characteristics to be *Paecilomyces* sp. This case was successfully treated by oral ketoconazole (200 mg/day).

*MJIRI, Vol. 18, No. 2, 181-184, 2004.*

**Keywords:** *Paecilomyces* infection – fungal infection – immunocompromised patients.

### INTRODUCTION

*Paecilomyces* spp. is seldom associated with human infections. Most of the cases recorded have been of a mycotic keratitis. Several cases are now on record of endocarditis following valve replacement,<sup>1</sup> and endophthalmitis following lens implantation.<sup>2</sup>

mon air-borne contaminant is resistant to most sterilizing techniques. occurred in which the organism was growing in the disinfectant used for surgical instruments. there were 12 cases of endophthalmitis following intraocular lens implantation<sup>2-3</sup> The first case of endophthalmitis was reported by Uys<sup>4</sup> in 1963, typical of these cases.

the blood, from a thrombus overlying the mitral valve, and from an embolus in the iliac artery following the death of a patient who had had a valve replacement.<sup>4</sup>

*Paecilomyces* spp. was recovered from the renal pelvis by Sherwood and Dansky, who reviewed *Paecilomyces* infections up to 1983.<sup>5</sup>

Pulmonary infusion<sup>6-7-8</sup> and pneumonia<sup>9</sup> have been noted. Georg from pulmonary lesion in a giant tortoise. Mycelium was present in many small abscesses throughout the lung. Most cases are cutaneous or concern transient catheter-related infections, but also deep infections are

known.<sup>18</sup> The present article describes *Paecilomyces* spp. from subcutaneous tissue in the insulin induction site.

### CASE REPORT

The patient was a 78-year-old woman residing in Damghan, diabetes mellitus for a long time. the Medical Mycology Department, Pasteur Institute of Iran with pruritic, ous nodules of the left hand with adjacent suppurative lymphatics. His problem began 28 days before she referred to the Medical Mycology Pasteur Institute laboratory.

Organisms had inoculated in the left hand in the insulin induction site.

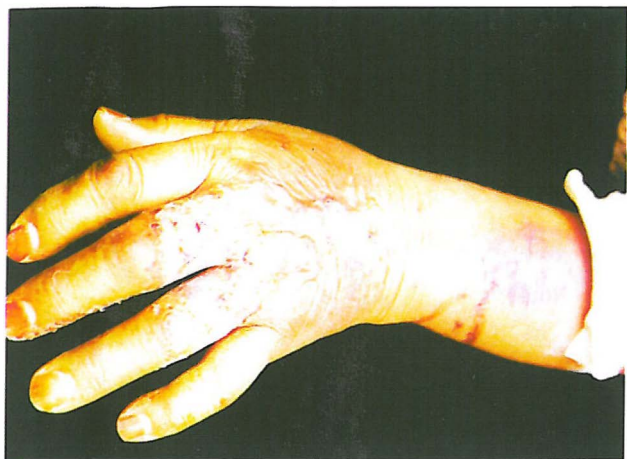multiple subcutaneous abscesses in the left forearm (Fig. 1). Fever had started 12 days after her problem began. Urine culture and tissue culture for bacteria were negative.

Her clinical history revealed that she had chronic renal failure over a period of 25 years and diabetes mellitus for over 14 years. She received insulin for 4 years before her problem began. Biopsy specimens of the lesions were performed.

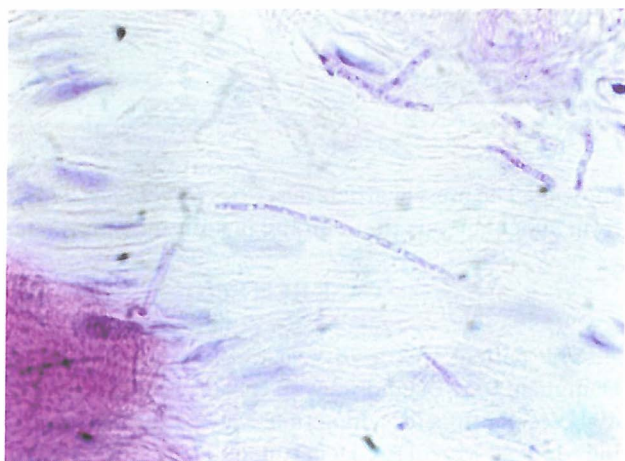
Specimens were directly examined with 10% potassium hydroxide. The biopsy specimen showed hyphae (Fig. 2) The tissue sections were stained by hematoxylin and eosin and periodic acid schiff stains. a granulomatous reaction.

on Sabouraud dextrose agar,

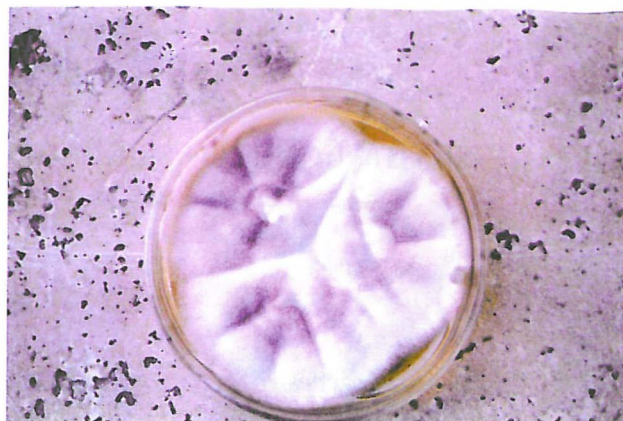E-mail: shahindokhtbassiri@yahoo.com



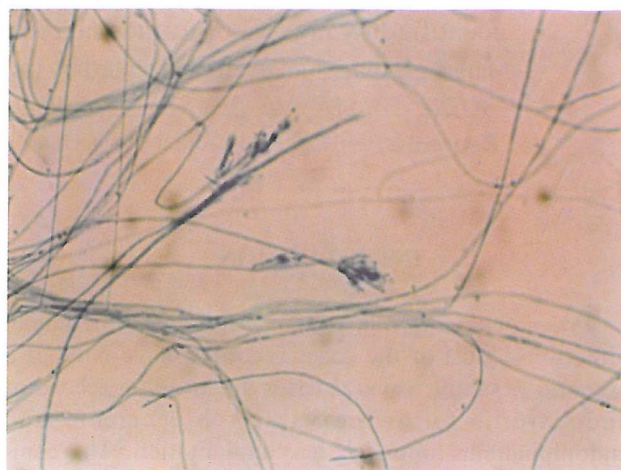
**Fig. 1.** Clinical appearance of the subcutaneous lymphatic abscesses.



**Fig. 2.** Histopathological section of biopsy specimen, showing numerous hyphae (hematoxylin – eosin stain).



**Fig. 3.** Colony of *Paecilomyces* sp. on sabouraud dextrose agar.



**Fig. 4.** Slide culture stained by cotton-blue method.

chloramphenicol (50 mg/mL), blood agar and brain heart infusion agar (BBL); Duplicate cultures on each medium were incubated at 35°C and 25°C, cultures of specimens gave rise to *Paecilomyces* spp. Microscopic features of the isolates were studied by slide culture preparation.

*Paecilomyces* colonies turned lilac in the substatum (Fig. 3).

Microscopic examination showed hyaline septate hyphae similar to *Penicillium* spp., but the phialides are single or verticillate on well – developed conidiophores or directly on vegetative hyphae (Fig. 4). The phialides end in a long tapered tube and bear long chains of lemon-shaped or nearly cylindrical conidia. Chlamydoconidia and aleurioconidia are also produced. The patient was treated for 40 days with oral ketoconazole (200 mg/day).

## DISCUSSION

*Paecilomyces* spp. is a common fungus in the air and can grow in environments with high ambient temperatures. The fungus has been reported to be the causative agent of human mycoses in the literature, mostly occurring in conjunction with prosthetic implants or immunosuppression. Cases include pneumonia,<sup>20-21</sup> peritonitis,<sup>11-25</sup> a fatal infection of a ventriculoperitoneal shunt<sup>19</sup> a case of pyelonephritis,<sup>26</sup> fungemia,<sup>27</sup> soft tissue infection of the heel,<sup>28</sup> sinusitis<sup>29-30</sup> endophthalmitis,<sup>31</sup> chronic suppurative otitis media,<sup>32</sup> cutaneous infection,<sup>33-34</sup> and a mycosis at the incision site of a patient who underwent a cesarean section.<sup>35</sup> Essential data are summarised in Table I.

Anderson et al<sup>13</sup> described infectious complications in 80% of renal transplant patients or renal failure, associated with high-dose corticosteroid therapy, hypergly-

cemia, leukopenia, or age over 40 years. These risk factors operated presumably by effects on suppression of humoral and cellular immunity and impairment of polymorphonuclear leukocyte function.<sup>13</sup> Our patient's infection was caused by the opportunistic fungus *paecilomyces* and was associated with three of the four risk factors noted above.

Because the organism was demonstrated in the dermis in pure culture on two separate biopsies, we considered it etiologic in our patient's infection. Many organisms that were previously considered to be contaminants when isolated from human specimens have emerged as major causes of disease, especially in the immunocompromised host.<sup>20</sup> Our

patient survived with antifungal treatment. This treatment included ketoconazole (200 mg per day) for 40 days.

## REFERENCES

1. Kalish, SB, Goldschmidt R, et al: Infective endocarditis caused by *Paecilomyces varioti*. J Clin Pathol 78:249-252, 1982.
2. Miller GP, Rebell G, et al: The intravitreal antimycotic therapy and the cure of mycotic endophthalmitis caused by a *Paecilomyces lilacinus* contaminated pseudophakos. Ophthalmic Surg 9: 54-63, 1978.
3. Mosier NA, Lusk B, et al: Fungal endophthalmitis follow-

**Table I.** Review of human *Paecilomyces spp.* infection.

Infection	References	Age/sex	Underlying conditions	Treatment	Outcome
pneumonia	20		Hairy cell leukemia		
pneumonia	21		DM		
peritonitis	22				
peritonitis	11	12/M	CAPD	AMB (10days)	Cured
peritonitis	11	60/F	CAPD	AMB (4weeks)	Cured
peritonitis	11	56/F	CAPD	KTZ (10days)	Cured
peritonitis	11	39/M	CAPD	KTZ	Cured
peritonitis	25	Infant	CAPD	FLZ	Cured
peritonitis	23		CAPD		
peritonitis	24	65/F	CAPD	AMB	Cured
CNS(disseminated?)	19	57/F	VSP		Died
CNS	12	60/F	Cancer, CT, DM	AMB	Died
pyelonephritis	26		Nephrolithiasis, VSP		
Fungemia	27	/F	BMT	AMB+ITZ	Cured
Soft tissue	28	8/M	CGD	AMB (4weeks) +ITZ (1 year)	Cured
Sinusitis	29				
Sinusitis	30			Surgical	Cured
Cutaneous	33				
Cutaneous	34	25/M			
Surgical site infection	35	31/F	Cesarian incision		Cured
Endophthalmitis	31				
Chronic Suppurative otitis media	32				Cured
Airway colonization	36	CF,LT			
Sub cutaneous	This study	78/F	RF, DM	KTZ(40 days)	Cured

M, male; F, female; DM, diabetes mellitus; CAPD, continuous ambulatory peritoneal dialysis; VSP, ventriculoperitoneal shunt placement; CT, chemotherapy; BMT, allogenic bone marrow transplant; CGD, chronic granulomatous disease; LT, lung transplant; CF, cystic fibrosis; RF; renal failure.

- ing intraocular lens implantation. Am J Ophthalmol 83: 1-8, 1977.
4. Uys CJ, Don PA, et al: Endophthalmitis following cardiac surgery due to fungus *Paecilomyces*. South Afr Med J 37: 1276-1280, 1963.
5. Sherwood JA, Dansky AS: *Paecilomyces* pyelonephritis complicating nephrolithiasis and a review of *Paecilomyces* infections. J Urol 130: 526-528, 1983.
6. Dekhkan-khodzhave NA, Shamsiev S, et al: Role of *Paecilomyces* in the etiology of protracted recurrent bronchopulmonary disease in children. Pediatriya 9: 12-14, 1982.
7. Fenech FF, Mallia CP: Pleural effusion caused by *Paecilomyces lilacinus*. Br J Dis Chest 66: 284-290, 1972.
8. Mormede M, Texier J, et al: Isolement d'un *Paecilomyces* (*P. lilacinus*), a partird'un epanchement pleural. Med Malad Infect 14: 76-78, 1982.
9. Dharmasena FM, Davies GSR, Catovsky D: *Paecilomces variotii* pneumonia complicating hairy cell leukemia. Br Med J 290: 967-968, 1985.
10. Geory LK, Williamson WM, et al: Mycotic pulmonary disease of captive giant tortoises due to *Beauveria bassiana* and *Paecilomyces fumosoroseus*. Sabouraudia 2: 80-86, 1962.
11. Marzec A, Heron LG, Pritchard RC et al: *Paecilomyces* peritonitis in peritoneal dialysate. J Clin Microbiol 31: 2392-5, 1993.
12. Kkantarcioglu AS, Hatemi G, Yucel A, De Hoog GS, Mandel NM: *Paecilomyces variotii* central nervous system infection in a patient with cancer. Mycosis 46, 45-50.
13. Anderson RJ, Schefer LA, Olin DB, et al: Infections risk factors in the immunosuppressed host. Am J Med 54: 453-460, 1973.
14. O'Day DM, Fungal endophthalmitis eased by *Paecilomyces lilacinis* after intraocular lens. Am J Ophthalmol 83: 130-131, 1977.
15. Harris LF, Dan BM, et al: *Paecilomyces* cellulitis in a renal transplant patient: Successful treatment with intravenous miconazole. South Med J 72: 897-898, 1979.
16. De Hoog GS, Guarro J, Gene JL, Figueras MJ: Atlas of clinical fungi, 2<sup>nd</sup> ed. , Utrecht/Reus : centraalbureau voor schim melcultures, Universitat Rovira, Virgili, 1126, 2000.
17. Kantarcioglu AS, et al: *Paecilomyces variottii* central nervous system infection in a patient with cancer. Mycoses 46: 45-50, 2003.
18. Abi-Said D, Anaissie EJ: New emerging fungal pathogens. In: Meunier F (ed.), Bailliere's Clinical Infectious Diseases. 2. Invasive Fungal Infections in cancer patients, London: Bailliere & Tindall, p. 71-87, 1995.
19. Fagerburg R, Suh B, Buckley HR, Laber B, Karian J: Cerebrospinal fluid shunt colonization and obstruction by *Paecilomyces variotii*. J Neurosurg 54: 257-60, 1981.
20. Harmasena FM, Davies GSR, Catovsky D: *Paecilomyces variotii* pneumonia complicating hairy cell leukemia. Br Med J 5: 290: 967-8, 1988.
21. Byrd RP, Roy TM, Fields CL, Lynch JA: *Paecilomyces variotii* in a patient with diabetes mellitus. J Diabetes Complic 6: 150-3, 1992.
22. Crompton CH, Balfe JW, Summerbell RC, Silver MM: Peritonitis with *Paecilomyces* complicating peritoneal dialysis. Pediatr Infect Dis 10: 869-71, 1991.
23. Eisinger RP, Weinstein MP: A bold mold? *Paecilomyces variotii* peritonitis during continuous ambulatory peritoneal dialysis. Am J Kidney Dis 18: 606-8, 1991.
24. Nankivell BJ, Pacy D, Gordon DL: Peritoneal eosinophilia associated with *Paecilomyces spp*. Infection in continuous ambulatory peritoneal dialysis. Am J Kidney Dis 18: 603-5, 1991.
25. Rinaldi S, Fiscarelli E, Rizzoni G: *Paecilomyces spp*. peritonitis in an infant on automated peritoneal dialysis. Pediatr Nephrol 365-6, 2000.
26. Sherwood JA, Dansky AS: *Paecilomyces* pyelonephritis complicating nephrolithiasis and review of *Paecilomyces* infections. J Urol 130: 326-8, 1983.
27. Shing MM, Ip M, Li CK, Chik KW, Yuen PM: *Paecilomyces varioti* fungemia in a bone marrow transplant patient. Bone marrow Transplant 17: 281-3, 1996.
28. Williamson PR, Kwon-Chung KJ, Gallin JI: Successful treatment of *Paecilomyces* infection in a review of *Paecilomyces* species infections. Clin Infect Dis 14: 1023-6, 1992.
29. Tcenasek M, Jirousek Z, Menel K. *Paecilomyces* of the maxillary sinus. Mykosen 27: 242-51, 1984.
30. Thompson RF, Bode RB, Rhodes JC, Gleukman JC: *Paecilomyces variotii*: an unusual case of isolated sphenoid sinusitis . Arch Otolaryngol Head Neck Surg 114: 489-96, 1988.
31. Lam DS, Koehler AP Fan DS, Cheuk W, Leung AT, Ng JS: Endogenous fungal endophthalmitis caused by *Paecilomyces variotii*. Eye 13: 113-6, 1999.
32. Jaisree N, Singh SM: Hyalohyphomycosis caused by *Paecilomyces spp*. A case report, animal pathogenicity, and *in vitro* sensitivity. Antonie van Leuwenhoek 62: 225-30, 1992.
33. Dhindsa MK, Naidu J, Singh SM, Jain SK: Chronic suppurative otitis media caused by *Paecilomyces variotii*. J Med Vet Mycol 33: 59-61, 1995.
34. Naidu J, Singh SM: Hyalohyphomycosis caused by *Paecilomyces spp*. A case report, animal pathogenicity, and *in vitro* sensitivity. Antonie van Leuwenhoek 62: 225-30, 1992.
35. Athar MA, Sekhon AS, Megrath JV, Malone RM. Hyalohyphomycosis caused by *Paecilomyces variotii* in an obstetrical patient. Eur J Epidemiol 12: 33-5, 1996.
36. Das A, MacLaughlin EF, Ross LA, Monforte HL, Horn MV, Lam GL, Mason WH: *Paecilomyces spp*. in a pediatric patient with lung transplantation. Pediatr Transplant 3: 328-32, 2000.