

GASTROESOPHAGEAL LEIOMYOMATOSIS IN A YOUNG WOMAN WITH VULVAR LEIOMYOMATOSIS AND GALLSTONE DISEASE: REPORT OF A RARE CASE

ALIREZA TAVASSOLI, M.D., FATEMEH TAVASSOLI, M.D.,
NORIE SHARIFI, M.D., AND ALI SADRIZADEH, M.D.

*From the Department of Surgery, Ghaem Hospital, Mashhad University of Medical Sciences,
Mashhad, Iran.*

ABSTRACT

Gastroesophageal-vulvar leiomyomatosis is a very rare condition; it is characterized by diffuse, ill-defined proliferation of smooth muscle in the esophagus and vulva.

We present an interesting case of esophageal leiomyomatosis in a woman with a history of vulvar leiomyomatosis and a gall bladder full of stones. She was 18-years old and had a 4 year history of vulvar mass and clitoromegaly, with subclinical dysphagia. This paper represents the first reported simultaneous occurrence of these three pathologic entities in the English literature.

Esophago-vulvar leiomyomatosis should be considered in a young patient with vulvar mass and long-standing dysphagia in whom a smooth, tapered esophageal narrowing on barium study and circumferential esophageal wall thickening on CT scan are seen. An esophagectomy combined with a reconstruction procedure is indicated.
MJIRI, Vol. 17, No. 4, 347-352, 2004.

INTRODUCTION

Leiomyomatosis is a rare condition of unknown etiology;¹ there is diffuse thickening of the esophageal musculature.^{1,3} A few cases of leiomyomatosis have been described so far in the literature.^{4,5,6,7,8,9} The largest series, from Mexico, only described six cases, four of which belonged to one family, indicating that heredity may have a role in pathogenesis.¹⁰ The patients are often children and young adults,^{3,4} and females may be affected more often than males. It may be isolated or found in association with other intrathoracic and genital localizations or Alport syndrome (nephropathy, sensorineural deafness, and ocular lesions).^{1,3,11,12,13} Genital localizations, exclusively in women (clitoral hypertrophy, vulvar leiomyomatosis), in association with esophageal leiomyomatosis comprise the esophago-vulvar syndrome.¹⁴ In this article, we present an interesting case of esophago-vulvar leiomyomatosis in a woman with gallstone disease. This paper represents the first reported simultaneous occurrence of these three pathologic entities in the English literature.

CASE REPORT

An 18 year old woman presented with clitoromegaly and retrovulvar mass. She hadn't told her problem to anybody until she got married and her husband referred her to a physician.

On physical examination, the lungs were clear, there was no palpable abdominal mass but abnormal genitalia because of clitoromegaly and a retrovulvar mass was detected (Fig. 1). Examination of hymen and vagina was normal. Chest radiographs (Fig. 2) demonstrated a large middle mediastinal mass in the region of the esophagus. Further questioning revealed mild dysphagia, which limited her to small bites of food. UGI Endoscopy didn't show intraluminal invasion and a minimal degree of mucosal inflammation was confirmed by biopsy. The patient had no signs of Alport's syndrome such as renal disease, sensorineural hearing loss, and ocular impairment. Family history for similar abnormalities was unremarkable.

Barium esophagogram (Fig. 3) showed a consider-

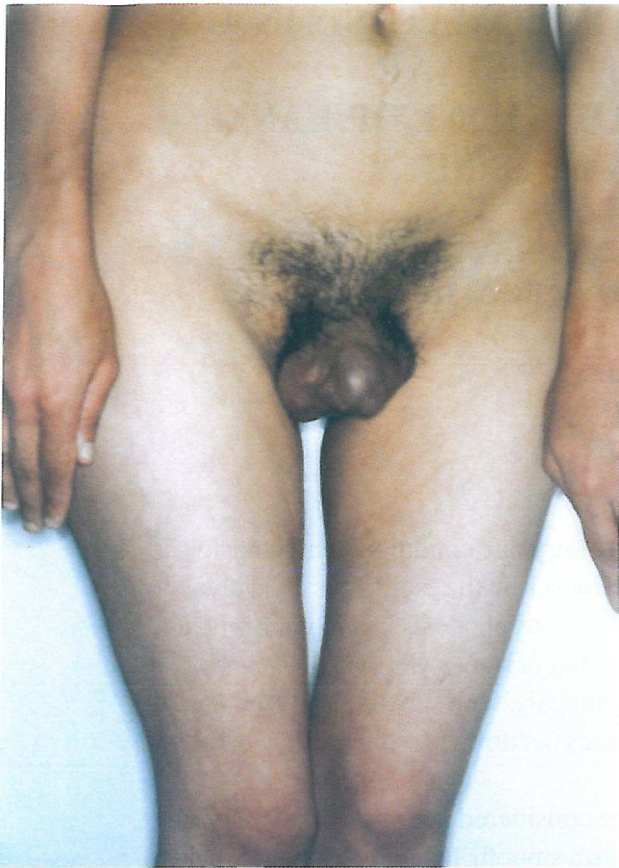

Fig. 1. The patient with esophagovulvar leiomyomatosis.

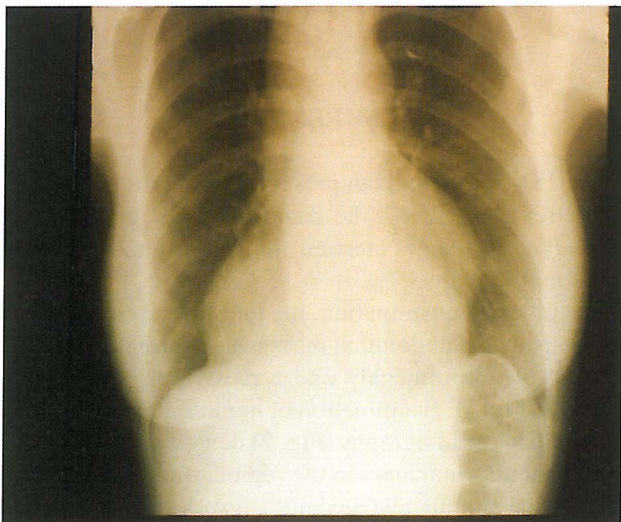


Fig. 2. CXR (PA) demonstrates a large middle mediastinal mass in the region of the esophagus.

able variability in the caliber of the esophagus with regions that were quite distended. The maximum diameter in some areas extended up to 15 centimeters and was similar to a stomach! The mass extended to the gastro-esophageal junction but did not seem to involve the fun-

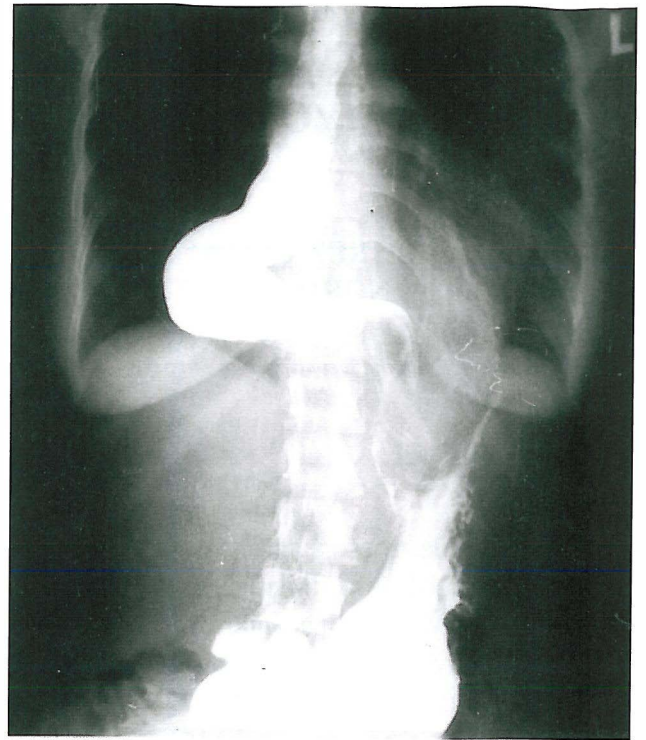

Fig. 3. Barium esophagogram demonstrates considerable variability in the caliber of the esophagus with regions that were quite distended. No passage disturbance was present.

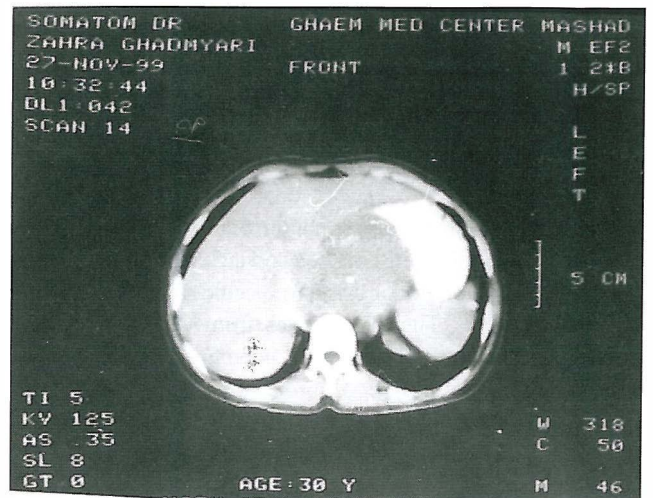


Fig. 4. Contrast-enhanced computed tomography of the chest reveals a long segment of circumferential soft tissue mass encircling the esophagus.

cus per se. Sonography and CT scan revealed the soft tissue bicomponent masses intimately associated with the esophagus though the lumen of the esophagus was quite smooth (Fig. 4). No adenopathy, either in the gastrohepatic region or in the mediastinum was defined on

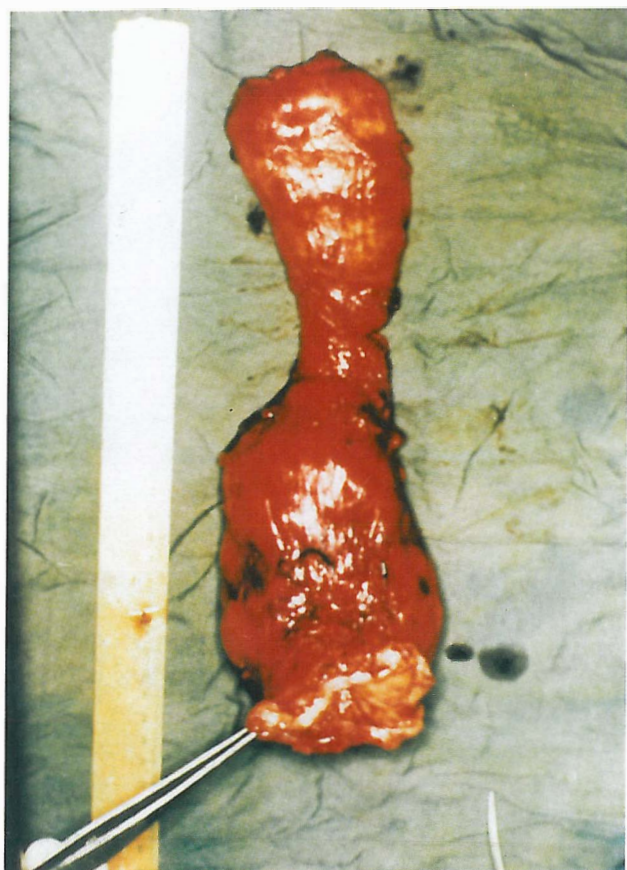


Fig. 5. Gross specimen of the esophagus (A-P view) reveals a circumferential multilobulated solid mass encircling the esophagus which has an intact mucosa.

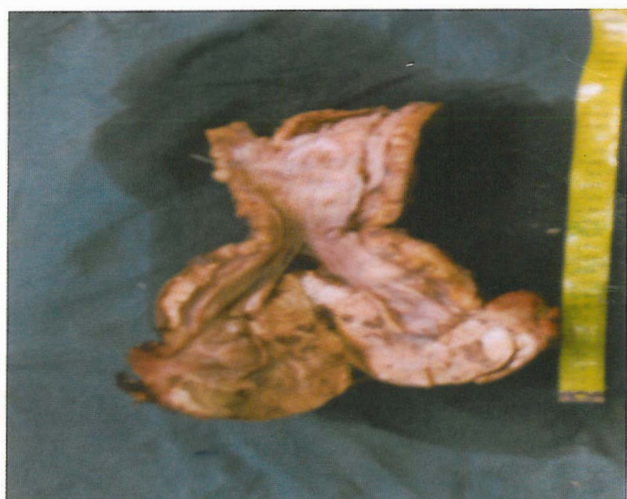

Fig. 6. Cut surface of the esophageal specimen shows bulk of the tumor at the lower end and abnormal muscular hypertrophy throughout the whole esophagus.

the CT images.

A right posterolateral thoracotomy was performed to establish the diagnosis and hopefully salvage the




Fig. 7. Gallbladder stones.

esophagus. The complex bicomponent mass was within the esophageal wall. It extended several centimeters proximal to the azygos vein to the hiatus. Intraoperatively, it was decided that esophageal preservation was not possible. After resection of the thoracic esophagus (Figs. 5,6) the patient was turned supine and a laparotomy and left neck incision were performed. The stomach was mobilized and transposed through the posterior mediastinum to the neck and a cervical esophagogastrostomy was performed. The genital mass was excised, and the remaining skin was reapproximated. The gallbladder containing more than 30 stones also was removed (Fig. 7). Postoperatively the patient needed further ventilation support for 2-3 days but made a smooth postoperative recovery.

The gross specimen of the vulvar lesion was a well-demarcated tumor measured 11×5×4 cm with a bulging gray cut surface.

Histologic examination showed poorly defined interlacing bundles of smooth muscle cells with blunt ended, cigar shaped nuclei and eosinophilic cytoplasm. There was no necrosis (Fig. 8). Cytoplasmic immunoreactivity for desmin, actin, and vimentin was present by

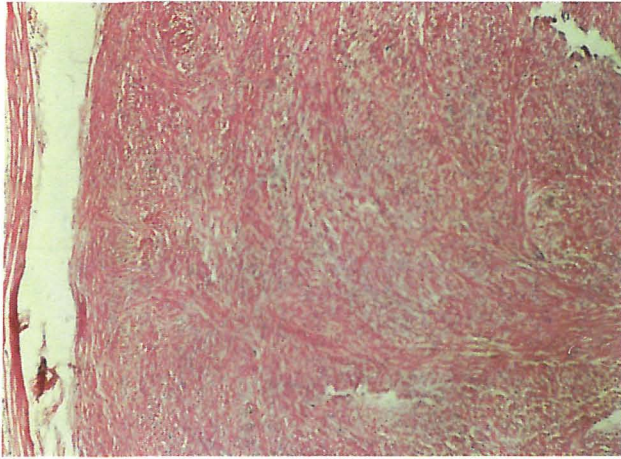


Fig. 8. Histopathologic examination of mass (H & E; original magnification $\times 100$), show diffuse proliferation of smooth muscle cells as interlacing bundles with blunt ended, cigar shaped nuclei and eosinophilic cytoplasm.

the avidin-biotin technique with appropriate control (Fig. 9). There was nuclear positivity for estrogen and progesterone receptors.

The esophagogastrectomy specimen measured $25 \times 11 \times 7$ cm. On opening, the mucosa was smooth throughout the esophageal portion. However, there were multiple nodular masses projecting submucosally. The wall of the esophagus averaged 3.0 cm in thickness. Histologic examination was remarkable for a diffuse proliferation of spindle cells resembling smooth muscle under the mucosa with few mitosis. The proximal resection margin was involved. The distal resection margin was free.

Abdominal exploration was negative for other pathologies but the gall bladder was full of stones, and a cholecystectomy was performed.

DISCUSSION

Leiomyomas are benign tumors of smooth muscle origin and represent only 0.4% of all esophageal tumors.⁴ The lesions are mostly solitary, and multiple lesions are rare.⁴ Only a few cases of diffuse esophageal leiomyomatosis have been reported. On the other hand, smooth muscle neoplasms of the vulva are also exceedingly rare, a comprehensive study included only 32.¹⁸ Genital localizations, exclusively in women (clitoral hypertrophy, vulvar leiomyomatosis), in association with esophageal leiomyomatosis comprise the esophago-vulvar syndrome. Only a few cases of this rare syndrome have been described so far in the literature.^{5,7,19,20,21-23}

Leiomyomatosis represents a diffuse proliferation of smooth muscle that forms ill-defined nodules. Some authors have questioned whether they represent true neo-

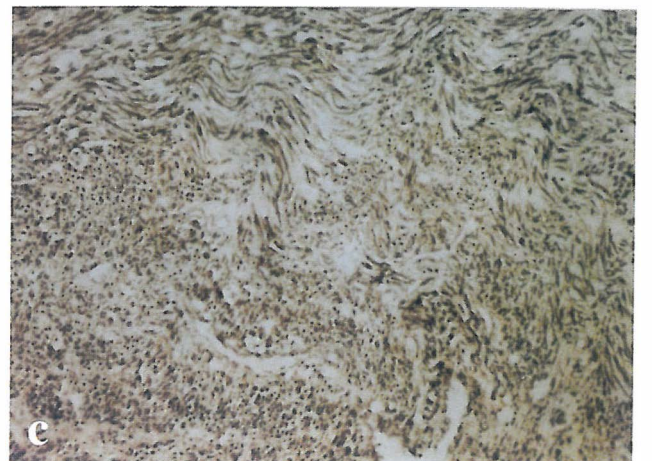
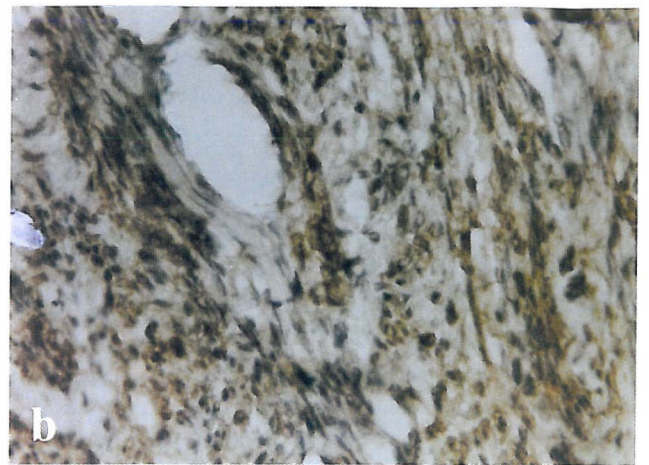
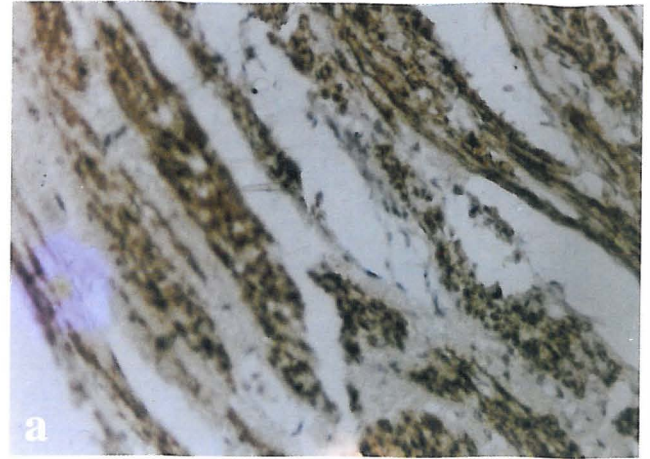


Fig. 9, (a, b, c). Immunohistochemical examination of vulvar mass biopsy with desmin-vimentin-actin markers show positive tumoral cell immunoreactivity (Immunostaining desmin-vimentin-actin $\times 250$).

plasms or hamartomas.^{4,15}

The clinical history of slowly insidious progressive dysphagia in a young patient and radiologic findings of smooth mucosa lining seen on the esophagogram are helpful in differentiating this benign entity from a malignant tumor.^{3,4,22} In patients with malignant esophageal tumor, the mucosa is eroded and irregular. Ranchod and Kempson have suggested that the primary feature in determining aggressive clinical behavior is the mitotic rate.²³ Those tumors with mitotic rates greater than five per 10 high-power fields ought to be regarded as leiomyosarcomas. In the case of gastroesophageal leiomyomatosis described herein, mitoses numbered fewer than two per 10 high-power fields, and therefore the criteria for malignancy is negative. Leiomyomas of the vulva are also very uncommon.² Tavassoli and Norris, in a study of 32 smooth muscle vulvar tumors accessioned during a 16-year period at the Armed Forces Institute of Pathology, proposed that tumors with an infiltrating margin should be considered malignant.^{2,23,24} Nielsen et al. did a clinical pathological study of 25 cases of smooth muscle tumors of the vulva,²⁴ According to their findings, tumors that manifest at least three of the following four criteria should be considered malignant: moderate to severe cytologic atypia, more than five mitoses per 10 high-power fields, infiltrating margins, and a size greater than 5 cm in size. In our case the vulvar nodules were larger than 5 cm in size, but mitoses numbered fewer than two per 10 high-power fields and margins was not infiltrated. More importantly, in this case, the patient has had a history of nodules in the vulva for more than 4 years and the pattern of growth in the esophageal and vulvar masses were not suggestive for a malignant process. Tapered narrowing of the distal esophagus with increased esophageal peristalsis, mimic the appearance of achalasia.^{1,3,6,8,14-15} Early evaluation with CT is valuable in detecting the intramural location of leiomyomatosis and differentiating this entity from achalasia and other causes of dysphagia.^{6,22,25} In our case the presentation of dysphagia was insidious and interestingly it wasn't a problem for the patient and she thought it is a normal condition

We examined the estrogen and progesterone profiles and found both receptors to be absent. Estrogen and progesterone probably do not play a role in the growth and proliferation of leiomyomatosis. Therefore an attempt at reducing the size of vulvar leiomyomatosis with antiestrogen agents is not with success. There was no suggestion of proliferations of smooth muscle elsewhere. Leiomyomatosis may represent a more systemic syndrome. In the majority of the reported cases of gastroesophageal-vulvar leiomyomatosis, there is an association with Alport's syndrome, a hereditary disease of type IV collagen.^{1,4,6,11,12,13,19,25} Families with this condition have triad of nephropathy, ocular abnormalities and high-

frequency sensorineural hearing loss. Leiomyomatosis can be associated with Alport's syndrome in 22% of cases.^{4,25} This case had none of the features of Alport's syndrome, and no pathologic condition was found on her parents.

Of interest in this particular case is the concomitance of gallstone disease. The gallbladder contained over 30 small black-pigmented stones. There was no mucosal infiltration or nodularity, and chronic inflammation without neoplastic changes was identified. The patient hadn't any symptoms related to cholecystitis. Cholelithiasis is often found in women of childbearing age, with an incidence of about 75% between the ages of 25 and 34 years. It is unusual for an 18-year old girl to have cholelithiasis.

We didn't find any abnormality in hematologic and biochemical profiles related to the syndrome.

Upon reviewing the literature, esophago-vulvar leiomyomatosis with cholelithiasis has not been reported yet and therefore this case may be the first case report.

In conclusion, recognition of esophago-vulvar leiomyomatosis is important because of its benign prognosis. Furthermore, awareness of this uncommon clinical condition may facilitate the proper diagnosis and treatment. Our case is typical in that the patient was young and presented with a 4 years history of vulvar mass and clitoromegaly, with subclinical dysphagia. We emphasize that leiomyoma of the vulva should prompt X-ray studies of the esophagus, and leiomyoma of the esophagus should prompt a search for vulvar leiomyoma.

REFERENCES

1. Campell F, Bogomeletz WV, Williams GT: Tumors of the esophagus and stomach. In: Christopher DM, (ed), Diagnostic Histopathology of Tumors, Vol 1, Harcourt Publishers Limited, pp. 327-328, 2000.
2. Buckley CH: Tumors of the Vulva, In: Christopher DM, (ed.), Fletcher Diagnostic Histopathology of Tumors, Vol 1, Harcourt Publishers Limited, pp. 714-715, 2000.
3. Guest AR, Strouse PJ, Hiew CC, Arca M: Progressive esophageal leiomyomatosis with respiratory compromise. *Pediatr Radiol* 30: 247-250, 2000.
4. Hsueh CJ, Hsu HH, Shen HJ, Juan CJ, Chin SC, Hsiao HS, Young TH, Chao DG: Diffuse leiomyomatosis of the esophagus: a case report. *Chin J Radiol* 24(2): 87-90, 1999.
5. Compagnoni GM, Talamonti MS, Joob A, Ergun GA, Rao S: Esophageal leiomyomatosis in a woman with a history of vulvar leiomyoma and Barrett's esophagus: a case report and review of the literature. *Dig Surg* 17: 306-9, 2000.
6. Rabushka LS, Fishman EK, Kuhlman JE, Hruban RH: Diffuse esophageal leiomyomatosis in a patient with Alport syndrome: CT demonstration. *Radiology* 179: 176-178, 1991.

Leiomyomatosis and Gallstone Disease in a Young Woman

- Faber K, Jones MA, Spratt D, Tarraza HM: Vulvar leiomyomatosis in a patient with esophagogastric leiomyomatosis: review of the syndrome. *Gynecol Oncol* Apr 41: 92-4, 1991.
- Philippe G, Frederic D, Lola C, Jean-Pierre T, Corinne A, Laurence H, Pierre Q: Diffuse esophageal leiomyomatosis with perirectal involvement mimicking Hirschsprung disease. *Gastroenterology* 120: 216-220, 2001.
- Levine MS, Buck JL, Linda PB, Buetow PC, Lowry MA, Sobin LH: Esophageal leiomyomatosis. *Radiology* 199: 533-536, 1996.
- Guarner V, Garcia Torres R: Diffuse leiomyomatosis of the esophagus, tracheobronchial, genital, and renal insufficiency. In: DeMeester TR, Skinner DB, (eds.), *Esophageal disorders: pathophysiology and therapy*. New York: Raven Press, pp. 447-57, 1985.
- Gregory MC, Atkin CL: Alport's Syndrome, Fabry's Disease, and Nail-Patella Syndrome. In: Schrier RW, Gottschalk CW, (eds), *Diseases of the Kidney*, Chapter 19, 6th ed, Boston: Little, Brown & Co., pp. 561-590, 1997.
- Miner JH: Alport syndrome with diffuse leiomyomatosis. *Am J Pathol* 154(6): 1883-9, 1999.
- Sans N, Galy-Fourcade D, Bloom E, et al: Imaging of diffuse esophageal leiomyomatosis: two case reports and review of the literature. *Eur Radiol* 10: 134-138 (2000)
- Thorner P, Heidet L, Moreno Merlo F, et al: Diffuse leiomyomatosis of the esophagus: disorder of cell-matrix interaction? *Pediatr Dev Pathol* 6: 543-9, 1999.
- Lonsdale RN, Roberts PF, Vaughan R, Thiru S: Familial esophageal leiomyomatosis and nephropathy. *Histopathology* 20: 127-133, 1992.
- Cheng YL, Hsu JY, Yu CP, Lee SC: Diffuse leiomyomatosis of the esophagus. *Dig Surg* 17: 528-31, 2000.
- Reinhold OC, Hillemanns G: Leiomyomatosis of the esophagus. *Radiology* Sep 34: 534-6, 1994.
- Tavasolli FA: Smooth muscle tumors of the vulva. *Obstet Gynecol* 53: 213-217, 1979.
- Le Bras A, David A, Knipping M, Mensie A, Heidet L, Lopes P: Diffuse leiomyomatosis with genital involvement and Alport syndrome. Report of two cases. *J Gynecol Obstet Biol Reprod (Paris)* Sep 27:523-8(abstract), 1998.
- Wahlen T, Astedt B: Familial occurrence of coexisting leiomyoma of vulva and esophagus. *Acta Obstet Gynecol Scan* 44: 197-203, 1965.
- Shairo RL, Sadrock AR: Esophagogastric and vulvar leiomyomatosis: a new radiologic syndrom. *J Can Assoc Radiol* 24: 184-190, 1988.
- Yang PS, Lee KS, Lee SJ, et al: Esophageal leiomyoma: radiologic findings in 12 patients. *Korean J Radiol* 2(3): 132-7, September 2001.
- Siegler RW, Rothstein RI, Beecam JB, Dann JL: Gastroesophageal-vulvar leiomyomatosis presenting over the course of 20 years. *Arch Pathol Lab Med* 120: 1141-1144, 1996.
- Hopkins am, Chambers CD, Goodman MD: Epithelioid leiomyoma of the vulva. *J Natl Med Assoc* 91: 171-173, 1999.
- Rabushka LS, Fishman EK, Kuhlman JE, Hruban RH: Diffuse esophageal leiomyomatosis in a patient with Alport syndrome: CT demonstration. *Radiology* 179: 176-178, 1991.