

ELECTRODIAGNOSTIC STUDY OF PERIPHERAL NERVOUS SYSTEM (PNS) IN 30 PATIENTS WITH MULTIPLE MYELOMA

H. AYROMLOU,* M.D., J. EIVAZI,** M.D., R. KHANDAGI,* M.D.,
AND B. JALALIAN,* M.D.

*From the Departments of *Neurology and **Internal Medicine,
Tabriz University of Medical Sciences, Tabriz, I.R. Iran.*

ABSTRACT

Involvement of the peripheral nervous system is one of the complications of multiple myeloma with a varying incidence of clinical and subclinical neuropathy in different studies. As most of the patients with multiple myeloma suffer from generalized systemic symptoms such as malaise, bone and low back pain, the clinical clues to the diagnosis of the neuropathy in its initial stages could be ignored. In this study, we tried to determine the frequency of peripheral nervous system involvement in these patients by electromyography/nerve conduction (EMG/NCV) studies. This cross-sectional descriptive study of 30 patients with multiple myeloma revealed that 70% of cases showed peripheral nervous system involvement, of whom 57% were found to be asymptomatic and 43% symptomatic for peripheral nervous system disease.

The pattern of peripheral nervous system involvement was polyneuropathy (62%) followed by radiculopathy and carpal tunnel syndrome, 52% and 29%, respectively. Most of the neuropathies were of the sensorimotor axonal type. L5, S1 roots were the most common sites of radiculopathies. Therefore we conclude that the frequency of subclinical peripheral nervous system involvement in multiple myeloma patients was so rampant that evaluation of multiple myeloma patients with EMG/NCV studies was necessary.

MJIRI, Vol. 17, No. 2, 113-116, 2003.

Keywords: Multiple myeloma, PNS, Electrodiagnosis, Neuropathy

INTRODUCTION

Multiple myeloma (MM) is a multisystem disease which can involve the peripheral nervous system. Peripheral neuropathy may be the first presentation of MM. The incidence of peripheral neuropathy in MM patients has been variably reported, clinically (3-14%) and subclinically (40-60%).¹⁻⁴ Radiculopathy is considered as the most common neurologic complication of MM.^{1,4,5} Polyneuropathy and entrapment neuropathy also occur in this

disorder. Most patients with MM have musculoskeletal pain and weakness, as well as low back pain, thus the initial symptoms and signs of neuropathy may be missed in these patients. We decided to study the frequency and the type of peripheral nervous system (PNS) involvement in patients with MM and determine the usefulness of electrodiagnostic studies in asymptomatic neuropathic cases.

PATIENTS AND METHODS

Thirty patients with MM (21 men and 9 women) were studied at Imam Khomeini Hospital of Tabriz between

Correspondence: Dr. H. Ayromlou, Neurology Ward, Imam Khomeini Hospital, Tabriz, I.R. Iran.

EMG/NCV Studies in Multiple Myeloma

Jan. 1999 to Nov. 2000. All patients were examined generally and neurologically. We considered other conditions relevant to neuropathy (e.g. diabetes mellitus, uremia, and so on) and excluded any causes of neurologic findings other than underlying disease (e.g. discopathy many years before onset of the disease in 2 cases, mononeuropathy due to leprosy in one case). All patients were tested in an air-conditioned quiet room with the same electrodiagnostic machine and by the same neurologist. At least two sensory and two motor nerves in upper and lower limbs were tested. Depending on the NCV findings, EMG was performed on proximal or distal muscles of limbs, and if necessary more nerves or muscles were studied. The positive findings in our study included mononeuropathy, polyneuropathy and radiculopathy patterns. The type and severity of involvement was also detected. Finally our data was analyzed by software "SPSS 10.01" by independent sample "T" and chi-square tests.

RESULTS

Among 30 patients, age range in men was 40-73 years (mean 50yr) and in women was 40-70 years (mean 56.7yr) (Fig. 1). Mean duration of the illness was 22.9 months. In this study 70% (n= 21) of cases had positive electrodiagnostic findings (totally 76% of males and 50% of females). The mean duration of disease in patients with and without PNS involvement in electrodiagnosis was 25.9 months and 58 months respectively. Seven patients had uremia and all of them showed positive findings (neuropathy n= 6, radiculopathy n=1), only one case was diabetic and no other condition relevant to neuropathy found. Based on our clinical findings the most common pattern of involvement was polyneuropathy (n= 13, 62%) followed by radiculopathy (n= 11, 52%) and carpal tunnel syndrome (CTS) (n= 6, 29%) (Fig. 2.) The severity of PNS involvement in all patients was often mild and only two severe cases were found. The L₅ and S₁ were the most affected roots in radiculopathies. The most frequent type of polyneuropathies were axonal type

(53.8%), demyelinating (9%) and mixed type (23%). Sensorimotor polyneuropathy was found in 8 of 11 cases (53.8%), only 2 cases of pure sensory (n= 1, 52%) and no pure motor polyneuropathy was detected. In our study 9 patients (30%) had clinical findings related to neuropathy and 12 patients (43%) were clinically asymptomatic but showed positive findings in electrodiagnosis. In other words 100% of cases with clinically symptomatic neuropathy and 57% of asymptomatic ones (12 out of 21 cases) had positive findings of neuropathy in electrodiagnosis. The symptoms and signs associated with PNS involvement that we found were paresthesia (n= 5), radicular pain (n= 2), hypoesthesia (n= 5), atrophy (n= 2), weakness (n= 2) and reduced or absent deep tendon reflexes (n= 4).

DISCUSSION

MM is reported more frequently in males than female and its occurrence before 40 years, especially before 30 years is rare.⁶⁻⁸ In our study M/F ratio was 2.3/1, all of them were above forty. As no statistically significant findings were found between age and sex, we could infer that these factors had no influence on the results. The duration of illness was longer in patients with positive findings than with normal findings. There was no significant difference in relation to the length of treatment and positive findings.

We found a statistically significant difference in electrodiagnostic findings between symptomatic and asymptomatic patients with neuropathy (*p*-value <0.05). Therefore, electrodiagnostic testing in MM patients who are asymptomatic for neuropathy seems to be a valuable practical method in detecting subclinical cases and probably helpful in initiating appropriate management for neuropathic complications of MM. In order to suggest an appropriate time for such studies in the course of MM, further research seems necessary.

As mentioned, the incidence of peripheral neuropathy is between 3% to 14%, however the incidence has

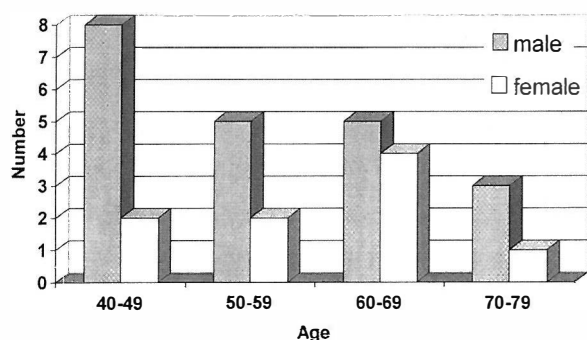


Fig. 1. Frequency of MM patients in different decades of life.

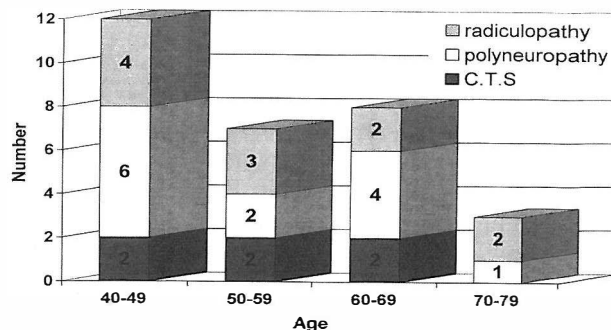


Fig. 2. Frequency of PNS involvement in MM patients in different decades of life.

increased to 40% and 60% when patients with subclinical peripheral neuropathy based on abnormal nerve conduction or histopathologic studies were included. In our study 30% of patients (9 out of 30 cases) had peripheral neuropathy clinically (excluding radiculopathies) and 57% of them (17 out of 30) manifested the neuropathic findings in EMG/NCV studies.

According to articles the most common neurologic complication of MM is thoracic or lumbosacral radiculopathy.⁵ However, in our study peripheral polyneuropathy has been the most common complication followed by radiculopathy and CTS respectively. Axonal type of neuropathy was present in most of our cases and pure demyelinating and mixed types were less frequent. In addition sensorimotor involvement was more common than pure sensory or motor types^{4,7} (as in other studies). Amyloid deposition in the flexor retinaculum is the cause of CTS in MM.⁹ 20% of our cases had CTS findings. Therefore, in all CTS cases with undefined etiology the possibility of amyloidosis and MM should be considered. The common radiculopathies caused by discopathies are mostly unilateral, but in our study, almost all radiculopathies were bilateral, hence it is suggested to consider MM and other systemic disorders in those suffering from bilateral radiculopathies. Of MM systemic complications, uremia has been the most accompanied with neuropathy, therefore the presence of uremia in these patients could be an indicator of neuropathy coexistence in MM patients. In most references it is mentioned that peripheral nervous system involvement is correlated to the type of multiple myeloma and it is more common in osteosclerotic and solitary forms.¹³⁻¹⁶ Also there are reports of monoclonal gammopathies of undetermined significance (MGUS) that are characterized by serum M-protein level less than 3g/dL, fewer than 10% plasma cells in the bone marrow and no or small amounts of MM protein in the urine¹⁹ and peripheral nervous system involvement as polyneuropathy is frequently seen in this type of gammopathy.¹⁸⁻²⁰ In our study all patients had osteolytic type of MM and there was no case of solitary or sclerotic types, in addition none of our patient's signs were consistent with POEMS syndrome. All our patients after a definite diagnosis of MM were referred to a neurologist for electrodiagnostic study, so we didn't see any patient before MM diagnosis with polyneuropathic signs. The other interesting point in this study was the unique therapeutic protocol applied for all of our cases. Melphalan, prednisolone and allopurinol were included in this protocol while in some patients with spinal cord compression, radiotherapy has been prescribed. No other cytotoxic drug was used by the patients. In addition, in our review articles no documented neurologic side effects have been reported for these drugs¹⁰ Therefore we could exclude the role of cytotoxic side effects as the

cause of neuropathy in our study. There are some reports that treatment of MM can occasionally improve neuropathy^{1,2,11-13} but in our study there was no significant correlation between duration of MM therapy and PNS involvement.

CONCLUSION

The subclinical involvement of PNS is a common problem in patients with MM thus electrodiagnostic evaluation in these patients seems to be useful for early diagnosis and management of this complication. Our study showed that mild axonal sensorimotor peripheral neuropathy is the most common pattern of PNS involvement in MM patients.

REFERENCES

1. Bosch P, Smith E: Disorders of peripheral nerves, In: Brady G, Daroff B, (eds), *Neurology in Clinical Practice*. Washington: Butterworth Heinemann, pp. 2045-2130, 2000.
2. Aminoff J: Neurologic complications of systemic disease. In: Brady G, Daroff B, (eds.), *Neurology in Clinical Practice*. Washington: Butterworth Heinemann, pp. 1009-1034, 2000.
3. Adams D, Victor M: Disease of Peripheral Nerves. In: Adams D, Victor M, (eds), *Principles of Neurology*. New York: McGraw-Hill, pp. 1302-1369, 1997.
4. Kelly J, et al: The spectrum of peripheral neuropathy in myeloma. *Neurology (Ny)* 31: 24-31, Jan. 1981.
5. Papadopoulos P, Balmaceda M: Hematologic and related diseases. In: Rowland LP, (ed.), *Merritts Neurology*, Philadelphia: Williams and Wilkins, pp. 864-875, 2000.
6. Hernandez JA, et al: Leukemia, myeloma and other lymphoreticular neoplasms. *Cancer* 75 (suppl): 381-94, 1995.
7. Longo L: Plasma cell disorders. In: Braunwald E, et al, (eds.), *Harrison's Principles of Internal Medicine*. New York: McGraw-Hill, pp. 712-718, 1998.
8. Hewell M, et al: Multiple myeloma in young persons. *Annals of Internal Medicine* 84: 414-443, 1976.
9. Forrester J, Paraskevas F: Multiple Myeloma, In: Lee RG, Forrester J, et al. (eds.), *Wintrobe's Clinical Hematology*. Vol. 2, Baltimore: Williams and Wilkins, pp. 2631-2680, 1999.
10. Gianni AM, et al: Efficacy, toxicity and application of high-dose sequential chemotherapy as adjuvant treatment in operable breast cancer with 10 or more involved axillary nodes: five-year results. *Jour Clin Oncol* 15 (6): 2312-2321, 1997).
11. Rotta T, et al: Marked improvement of severe polyneuropathy associated with multifocal osteosclerotic myeloma following surgery-radiation, and chemotherapy. *Muscle & Nerve* 20: 1035-1037, 1997.

EMG/NCV Studies in Multiple Myeloma

12. Knwabara S, et al: Long term melphalan-prednisolone chemotherapy for POEMS syndrome. *J Neurol Neurosurg Psych* 63: 385-387, 1997.
- 13- Diego MG, et al: Dyscrasia with polyneuropathy. *N Engl J Med* 31: 327 (27); 1919-23, 1992.
- 14- Solder G, et al: Lymphocytes in sural nerve biopsies from patients with plasma cell dyscrasia and polyneuropathy. *Peripher Nerv Syst* 4 (2): 91-8, 1999.
15. Hu KC, et al: Multiple myeloma associated with extramedullary plasmacytoma causing nerve root compression. *J Formos Med Assoc* 100 (4): 277-80, Apr 2001.
16. Grassi MR, et al: Light chain deposition disease. Neuropathy resembling amyloid neuropathy in a multiple myeloma patient. *Ital J Neurol Sci* 19 (4): 229-33, Aug 1998.
17. Kyle RA, Rajumar SV: Monoclonal gammopathies of undetermined significance. *Hematol Oncol Clin North Am* 13 (6): 1181-202, Dec 1999.
18. Simmons Z: Paraproteinemia and neuropathy. *Curr Opin Neurol* 12 (S): 589-95, Oct 1999.
19. Kelly JJ: Neuropathies of monoclonal gammopathies of undetermined significance. *Hematol Oncol Clin North Am* 13 (6): 1203-10, 1999.
20. Bosch EP, Smith BE: Peripheral neuropathies associated with monoclonal proteins. *Med Clin North Am* 77 (1): 125-39, 1993.