

Original Articles

LIVING-RELATED LIVER TRANSPLANTATION IN CHILDREN: THE SHIRAZ EXPERIENCE

S. A. MALEK-HOSSEINI, M.D., M. LAHSAIE, M.D. H. SALAHI, M.D.,
A. BAHADOR, M.D., M. HAGHIGHAT, M.D., M.J. KAVIANI, M.D.,
M.B. KHOSRAVI, M.D., M. BORZOIE, M.D., M. ARASTEH, M.D.,
M.H. BAGHERI, M.D., M. FATTAHI, M.D., H.R. DAVARI, M.D.,
S. NIK-EGHBAL, M.D., AND A. KARBASSI, M.D.

*From the Organ Transplantation Unit, Nemazee Hospital, Shiraz University
of Medical Sciences, Shiraz, Iran.*

ABSTRACT

The liver transplantation program was established at Shiraz Nemazee Hospital in 1993. Shortage of cadaver organ supply due to various social and legal issues urged us to develop a living-related liver transplantation (LRLT) program. So far 7 (6 males, 1 female) living-related liver transplantations have been performed at this center. The mean age of patients was 8.21 years (+/- 4.16), with a range of 4.5 to 14 years. Live donors (3 mothers, 2 fathers, and 1 brother) with a mean age of 30.83 years (+/- 4.11) underwent procurement of the left lateral segment without mortality or any serious morbidity. The native liver disease was idiopathic cirrhosis (1 case), biliary atresia (3 cases), Budd-Chiari syndrome (1 case), neonatal cirrhosis (1 case), and cryptogenic cirrhosis (1 case). Allografts were implanted using piggy-back surgical technique. Baseline immunosuppression consisted of a triple drug regimen including cyclosporine, mycophenolate mofetil and steroids. Acute graft rejection was treated with intra-venous bolus of methyl-prednisolone. Early death occurred in 2 patients due to vascular thrombosis. Biliary complication was observed in 1 patient. Five patients are alive with a normal functioning liver. In conclusion, LRLT program is promising in Iran. It can help to overcome the shortage of organs and minimize the mortality of patients in the waiting list.

MJIRI, Vol. 17, No. 1, 1-3, 2003.

Keywords: Liver transplantation, Living-related, Children

INTRODUCTION

Since our team performed the first liver transplantation procedure in Iran in 1993, this operation has become an effective treatment for patients with end-stage liver disease.¹ However, cadaver organ shortage due to various social and legal issues remains a crippling prob-

lem. In an attempt to overcome the small size cadaver-donor scarcity, living-related liver transplantation has been performed in our center.²

PATIENTS AND METHODS

In January 1998, we started our series of living-re-

Living-Related Liver Transplantation in Children

lated liver transplantations, and to date 7 such procedures have been performed at our center. The mean age of patients was 8.21 years, with a range of 4.5 to 14 years. The native liver diseases were idiopathic cirrhosis (1 case), biliary atresia (3 cases), Budd-Chiari syndrome (1 case), neonatal cirrhosis (1 case) and cryptogenic cirrhosis (1 case). The donors were mothers in 4 cases, fathers in 2, and a sibling in one, with a mean age of 30.83 years.

The donor, recipient, and family were fully informed about LRLT. Blood group, HLA tissue typing, cross match, and routine laboratory tests were done on donors who had no history of liver disease or medical illness. The donor and recipient were also evaluated from a psychiatric point of view. Doppler sonography was done to determine the patency of the portal vein. Ultrasonography of the liver was also performed, and the volume of the liver was determined by spiral CT-scan. If the donor's liver was found to be of an appropriate size, celiac and superior mesenteric artery angiography was carried out to assure that no vascular anomalies existed. Recipient evaluation was similar to those who wanted to receive a cadaver graft, except for a color Doppler sonography to detect any thrombosis in portal and hepatic veins.

The donor hepatectomy was performed through a chevron incision. We explored the abdomen and checked the liver for presence of an accessory artery as it might not be shown in angiography. After left triangular and coronary ligaments were transected the hepatic artery and portal vein were dissected up to bifurcations, with attention to preserve the blood supply of bile ducts, then the bile duct of the left hepatic lobe was dissected. In the first two cases we used intra-operative Doppler to delineate middle hepatic vein anatomy for safer hepatic resection. We dissected the left and middle hepatic veins in 2 donors in whom the left lobe was dissected, in others only the left hepatic vein was dissected. The line of dissection was marked by argon

beam and then the left lobe or left lateral segment was dissected using CUSA and bipolar cautery (Fig. 1). Simultaneously in another room recipient hepatectomy was performed preserving the inferior vena cava.

The partial liver graft was performed with University of Wisconsin solution through the left portal vein, the left hepatic artery, and the left hepatic duct (Fig. 2). First, the graft's hepatic vein was anastomosed in a triangular fashion to the inferior vena cava with 6-0 prolene. Next, the portal vein was anastomosed end to end with 6-0 prolene to the recipient's portal vein. Finally, the left hepatic artery was anastomosed to the common hepatic artery of the recipient. Following the vessel anastomosis, a Roux-en-y segment was prepared and a hepaticojejunostomy performed. Routinely, intra-operative liver biopsies were obtained. Mean warm ischemic time and cold ischemic time were about 8 minutes and 4 hours respectively. Mean recipient's operation time was 6 hours (Fig. 3). Immunosuppressive therapy consisted of a triple regimen. In this protocol, cyclosporine (CyA) was administered (1.5 mg/kg/d intravenously) until oral feeding was started, and at 7.5 to 10 mg/kg/d thereafter. The CyA dosage was adjusted according to its blood level. The methyl-prednisolone dosage was 10-15 mg/kg/d for the first 3 days and once oral feeding was started, prednisolone was started at 30 mg/d. Prednisolone was tapered and discontinued by the 30th day post-operation. Mycophenolate mofetil was administered at 500 mg to 1 g/d. Rejection episodes were treated with steroid bolus administration and/or with monoclonal (OKT3) antibodies in steroid-resistant cases.

RESULTS

Early death occurred in 2 recipients within the first month following the operation due to vascular thrombosis. Five other patients whose primary illnesses were

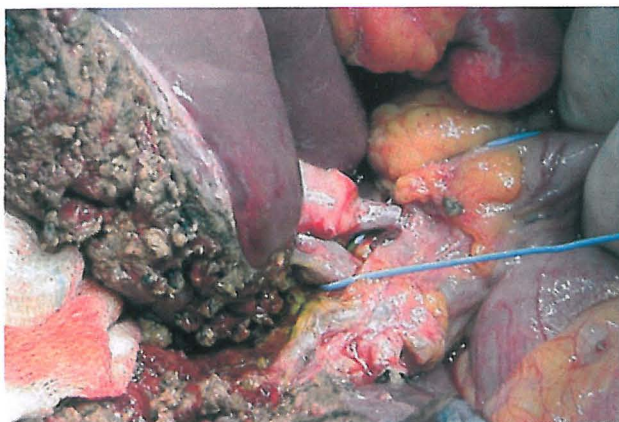

Fig. 1. Dissection and separation of left lateral segment.

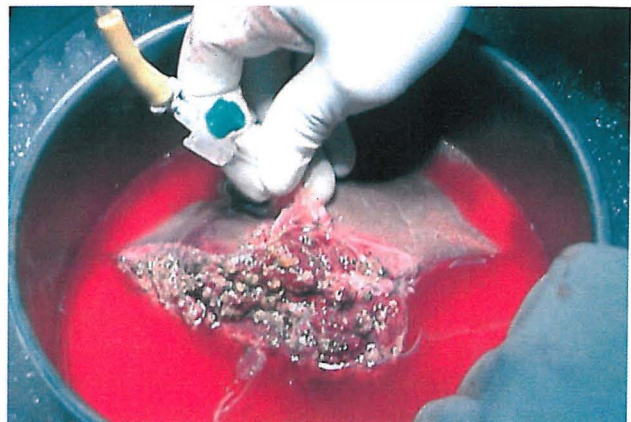

Fig. 2. Back table irrigation of left lateral segment.

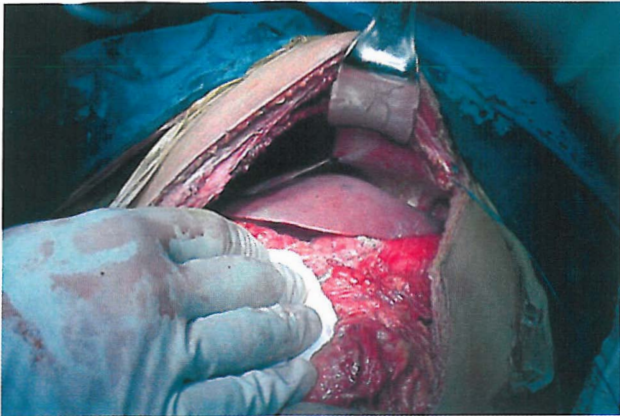


Fig. 3. Partial liver transplantation after anastomosis in recipient.

Budd-Chiari syndrome, Biliary atresia, and cryptogenic cirrhosis are still alive with livers functioning well in the 52nd, 16th, 14th, 10th, and 5th postoperative months. Biliary leakage was observed in 1 recipient which was repaired 1 year post-operation. The mean hospitalization period for donors was 7 days, and no serious complications were observed in these cases. To date, all donors are alive and in good health with normal liver function.

DISCUSSION

The first successful liver transplant from a living donor was reported by Strong et al. from Australia. This method is now becoming a standard mode of treatment for select patients at some liver transplant centers.^{3, 4} It has been shown in several clinical trials that orthotopic transplantation of a liver graft reduced to the left lateral lobe could be satisfactorily achieved.⁵ The main benefit of using living donors is that the appropriate operation time can be electively scheduled before serious decompensation occurs. Compared to cadaver donor grafts, organ preservation injury is minimized with extremely short cold ischemic time.⁶ The surgical procedure is technically more demanding, and exceptional expertise in hepatic

resectional surgery is essential to protect donor safety. The risk of donor death and complications are real. None of our 7 living donors had any serious operative or post-operative complications. Both the remnant liver in the donor and the transplanted liver segment in the recipient regenerate after transplantation, but the transplanted segmental liver has been shown to regenerate much faster than the donors residual liver, although both are made up of the same hepatocytes.⁷

CONCLUSION

The distressing shortage of cadaveric donors continues to be the greatest barrier to liver transplantation in Iran. LRLT program is promising in Iran. It is safe for donors and beneficial for recipients. LRLT can decrease the gap between the number of available organs and the number of patients on the waiting list.

REFERENCES

1. Malek-Hosseini SA, Lahsae M, Salahi H, et al: Report of the first liver transplantation in Iran. *Transplant Proc* 27(5): 2618, 1995.
2. Nezakatgoo N, Malek-Hosseini SA, Salahi H, et al: Lessons learned from the first successful living-related liver transplantation. *Transplant Proc* 31: 3171, 1999.
3. Strong RW, Lynch SV, Ong TH, et al: Successful liver transplantation from a living donor to her son. *N Engl J Med* 322(21): 1505-7, 1990.
4. Strong RW: Whither living donor liver transplantation. *Liver Transplant Surg* 5(6): 536-8, 1999.
5. Broelsch CE, Whittington PE, Edmund JC: Liver transplantation with reduced-size donor organs. *Transplantation* 45(3): 519-21, 1998.
6. Bilgin N, Karakayali S, Boyacioglu M, et al: Donor safety in living-related liver transplantation. *Transplant Proc* 33: 2730-31, 2001.
7. Matsunami H, Makunchi M, Kawazaki S: Living-related liver transplantation in fulminant hepatitis. *Lancet* 34(8832): 1411-12, 1992.

