




## The Effect of Nasal Tip Defatting on Skin Thickness in Rhinoplasty: A Quasi-Experimental Study

Alireza Mohebbi<sup>1</sup>, Amitis Nozari<sup>1\*</sup> , Sanaz Asadian<sup>2</sup>, Sara Sohrabi<sup>3</sup>, Mohammad Reza Babaei<sup>4</sup>, Hesam Jahandideh<sup>1</sup>

Received: 22 Mar 2021

Published: 20 Dec 2021

### Abstract

**Background:** A few studies have been published on the clinical efficacy and safety of nasal tip defatting plus rhinoplasty, particularly among people with bulbous noses. Therefore, the present study aimed to assess the consequences of nasal tip defatting for skin thickness reduction.

**Methods:** This quasi-experimental study was performed on 72 consecutive patients, candidates for aesthetic rhinoplasty. Twenty-seven patients were scheduled for nasal tip defatting with routine open rhinoplasty concomitantly. Besides, 45 patients underwent rhinoplasty without nasal tip defatting method. Tip and supra-tip skin thickness were assessed before and 12 months after the operation using ultrasonography. The patients' and surgeon's satisfaction with aesthetic results after the operation were also evaluated based on visual analog scaling (VAS). SPSS version 16.0 (SPSS Inc., Chicago, IL., USA) was used for the analyses. P values below 0.05 were considered statistically significant.

**Results:** Seventy-two patients (4 men, 68 women; mean age  $26.40 \pm 4.61$  years) entered the study. Twenty-seven candidates underwent rhinoplasty plus nasal tip defatting (group A). Open rhinoplasty alone was performed for the other 45 patients (group B). The mean nasal tip thickness was  $3.98 \pm 0.84$  mm in group A and  $3.69 \pm 0.64$  mm in group B before the surgery ( $p=0.059$ ). Preoperative nasal supra-tip thickness of the patients was also assessed using ultrasonography ( $3.54 \pm 0.72$  mm in group A versus  $3.73 \pm 0.54$  mm in group B;  $p=0.065$ ). Both preoperative tip and supra-tip thickness did not statistically differ between the two groups. No significant difference in postoperative tip skin thickness was obtained between two groups after 12 months ( $3.24 \pm 1$  mm in group A versus  $3.25 \pm 0.625$  mm in group B;  $p=0.960$ ), while postoperative supra-tip skin thickness differed significantly according to ultrasonography assessments ( $2.86 \pm 0.60$  mm in group A versus  $3.25 \pm 0.71$  mm in group B;  $p=0.016$ ). Postoperative satisfaction of the candidates was obtained using the VAS scoring system 12 months after the operation in both groups ( $8 \pm 1$  in group A,  $7.5 \pm 1$  in group B;  $p=0.021$ ). Surgeon's satisfaction in terms of the aesthetic outcome was also assessed based on the VAS system which did not statistically differ between the two groups as well as the patients' satisfaction ( $7.84 \pm 1.42$  in group A,  $7 \pm 1.61$  in group B;  $p=0.014$ ).

**Conclusion:** Nasal tip skin defatting is the main component in aesthetic rhinoplasty, but its significant effect on the reduction of tip skin thickness is controversial. However, in patients with moderate or thick nasal tip skin, such a procedure can result in higher postoperative satisfaction with the aesthetic outcome compared to rhinoplasty alone.

**Keywords:** Rhinoplasty, Nasal Tip, Nasal Tip Defatting, Nasal Skin, Nasal Skin Thickness

**Conflicts of Interest:** None declared

**Funding:** This study was supported by Iran University of Medical Sciences as part of a thesis to obtain Final ENT specialty certificate.

\*This work has been published under CC BY-NC-SA 1.0 license.

Copyright© Iran University of Medical Sciences

**Cite this article as:** Mohebbi A, Nozari A, Asadian S, Sohrabi S, Babaei MR, Jahandideh H. The Effect of Nasal Tip Defatting on Skin Thickness in Rhinoplasty: A Quasi-Experimental Study. *Med J Islam Repub Iran.* 2021 (20 Dec);35:170. <https://doi.org/10.47176/mjiri.35.170>

**Corresponding author:** Dr Amitis Nozari, [nozari.am@iums.ac.ir](mailto:nozari.am@iums.ac.ir)

<sup>1</sup> ENT and Head & Neck Research Center and Department, Hazrat-e Rasool Hospital, The Five Senses Institute, Iran University of Medical Sciences, Tehran, Iran

<sup>2</sup> Rajaie Cardiovascular Medical and Research Center, Iran University of Medical Sciences, Tehran, Iran

<sup>3</sup> Firoozgar Clinical Research Development Center (FCRDC), Firoozgar Hospital, Iran University of Medical Sciences, Tehran, Iran

<sup>4</sup> Department of Interventional Radiology, Firoozgar Hospital, Iran University of Medical Sciences, Tehran, Iran

### ↑What is “already known” in this topic:

Nasal skin thickness is generally associated with subcutaneous and glandular tissues. Rhinoplasty candidates with thick skin are usually less satisfied with the outcomes. Owing to a close link between nasal skin thickness and aesthetic outcomes, novel interventions like the nasal tip defatting method have been evolved.

### →What this article adds:

No significant reduction in nasal tip skin thickness using the defatting technique was shown, while the thickness of nasal supra-tip skin was significantly reduced in this method. Moreover, such a procedure could result in higher satisfaction compared to open rhinoplasty surgery alone regarding postoperative aesthetic outcomes.

## Introduction

Regarding preoperative schedules and postoperative outcomes in patients, candidates for rhinoplasty operation, attention to important parameters including skin thickness and its related subcutaneous conditions is essential. Some individuals characterize their wide nasal tip as a big ball, which is known as the bulbous nose (1). In such people, the space between the two domes related to the lobule is wide and the nasal projection looks round. According to the literature, high skin thickness in the nasal tip can be found in about one-third of noses (2).

Nasal skin quality can be assessed by different examining techniques such as manual touching, simple photography, and radiography. However, these methods are frequently inaccurate. High-resolution ultrasonography or even computed tomography scanning is now accepted as techniques providing accurate and quick information about the nasal structure and variations of the nasal deformities (3-5).

Refinement of the nasal tip is naturally considered the main goal in aesthetic rhinoplasty. This aim can be achieved by some surgical techniques such as tip defatting (6). In this procedure, a layer of fibrofatty tissue is removed from the space between the tip cartilages and overlying nasal tip skin. However, extensive tip defatting may injure the nasal tip vascular bed (certainly supply from lateral nasal arteries), which can be a major complication of this surgery (3). Moreover, skin congestion, hematoma, ecchymosis, or necrosis may occur less frequently (7). More importantly, maintaining normal nasal musculature is the main target. The nasal musculature is an extension of the superficial musculoaponeurotic system (SMAS) that essentially helps in facial fibromuscular structuring and normal face and nose-related functions such as smiling and breathing (8).

However, in any intervention with the purpose of nasal tip restructuring, SMAS structure should be maintained through its resection and debulking to minimize tip defatting adverse sequels (9-11). Therefore, the present study aimed to assess the consequences of nasal tip defatting for skin thickness reduction and, finally the surgeon's and patients' satisfaction with the final aesthetic result.

## Methods

This quasi-experimental study was performed on 91 consecutive patients, candidates for aesthetic rhinoplasty

referred to Hazrat-e-Rasool hospital in Tehran, Iran, between January and December 2018. Patients who appeared to have medium or thick nasal skin through initial clinical examination were considered. By further assessments, three patients were excluded with thin nasal skin diagnosed by ultrasound sonography. Additionally, 16 other patients did not participate in further follow-up visits. Finally, 72 patients entered the study.

The exclusion criteria included a previous history of smoking and allergic rhinitis, presence of skin scars, medical contraindications for rhinoplasty such as hemodynamic instability or serious systemic disorders, thin nasal skin assessed by ultrasonography, and any history of nasal surgery or deviated nose.

The study steps were performed in accordance with the Helsinki Declaration and approved by the Ethics committee of Iran University of Medical Sciences; (code: IR.IUMS.FMD.REC.1398.499). All surgical interventions were performed by the same surgeon and operating team. Only participants were blinded to the method of rhinoplasty. Informed written consent was obtained from all of them before the operation. Randomization was impossible due to practical limitations.

After the initial physical examination and photography for primary assessment of the nasal structure, the noses were assessed by ultrasonography (MyLab™Eight, Esaote Company, Italy, 12 megahertz ultrasound device with 0.01mm accuracy; available from [www.esaote.com](http://www.esaote.com)) to determine the nasal skin thickness. In this regard, the skin thickness of less than 2.6 mm was defined as thin, 2.6 to 3.1 mm as moderate, and more than 3.1 mm as thick (12).

The participants were then submitted for open rhinoplasty with nasal tip defatting or without it, according to the surgeon's decision. In the nasal tip defatting method, the subcutaneous fibrofatty tissues were dissected and extracted (Fig. 1). Patients who underwent open rhinoplasty plus nasal tip defatting were considered as the intervention group (group A) and those who underwent open rhinoplasty alone as the control group (group B). Both intervention and control groups received similar postoperative care.

Further evaluations were also performed using an ultrasonography device to measure nasal tip and supra-tip thickness by a single radiologist. The surgeon's satisfaction was determined based on the follow-up visit and

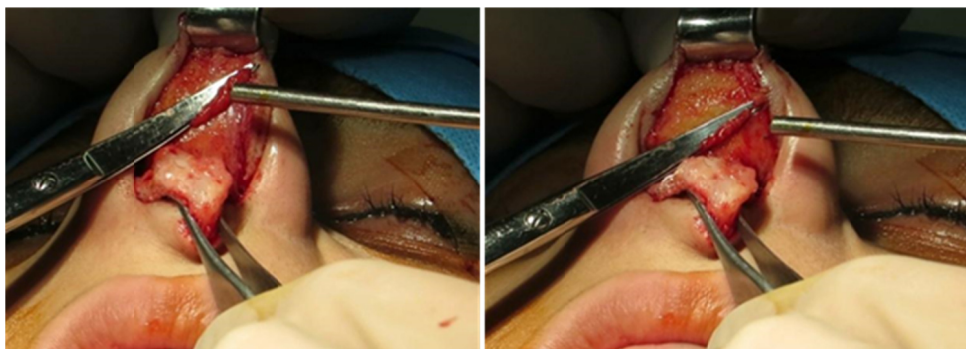


Fig. 1. Nasal tip defatting.

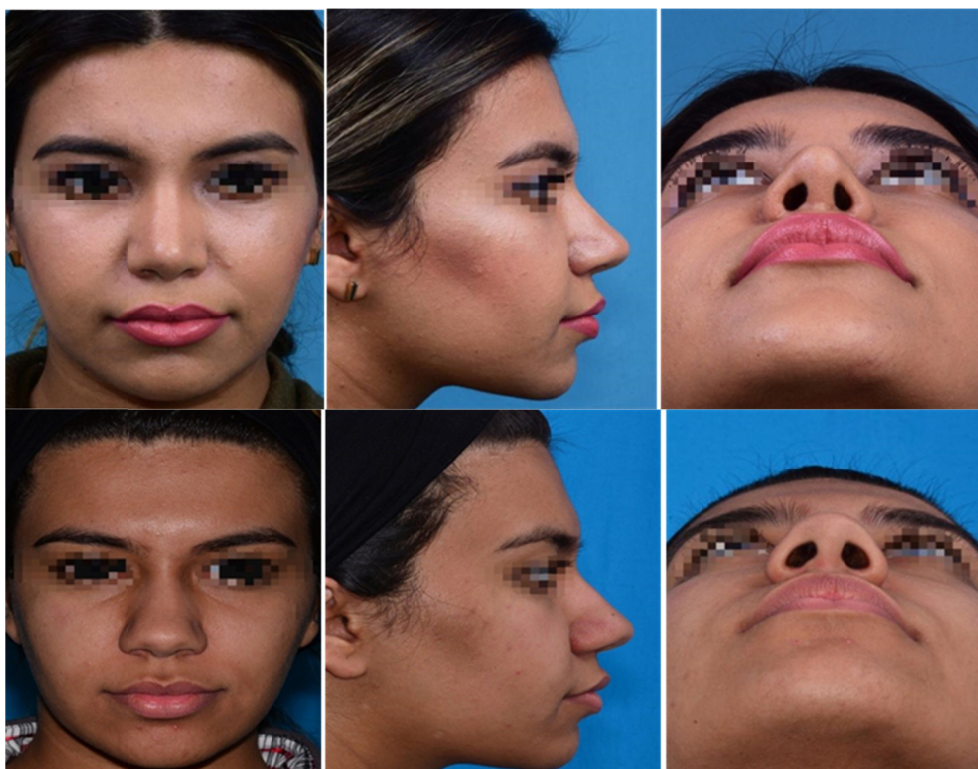

Fig. 2. A) .Patient with thick skin before surgery (first row). B) One year after rhinoplasty with nasal tip defatting (second row)

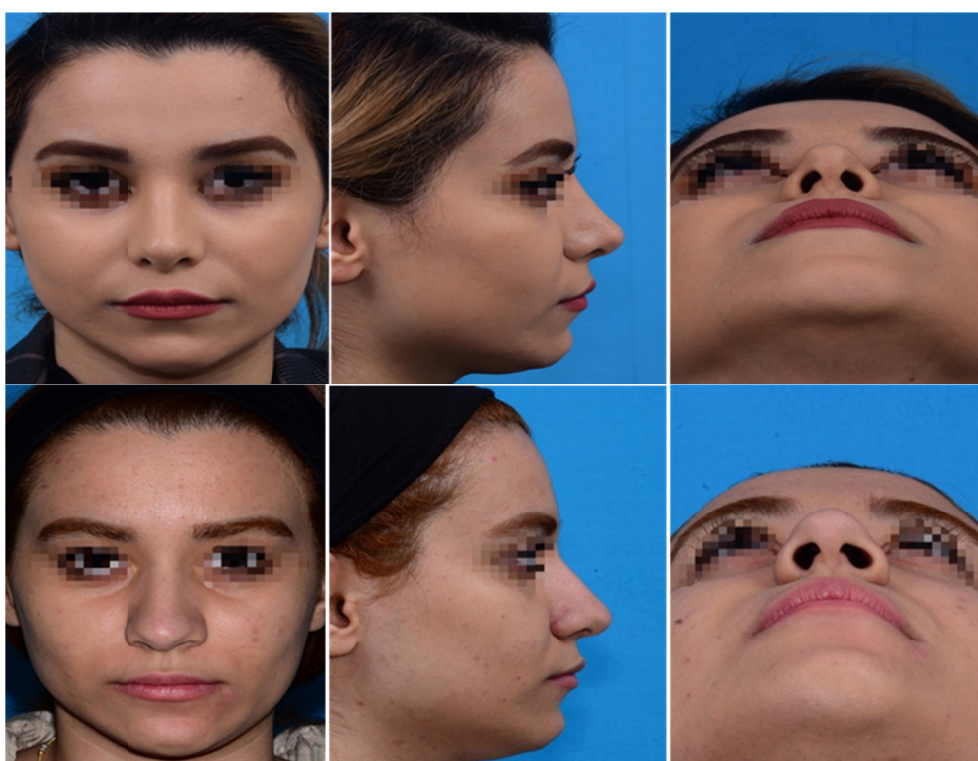

Fig. 3. A) Patient with thick skin before surgery (first row). B) One year after rhinoplasty without nasal tip defatting (second row)

comparing pre- and post-operative photos using the visual analog scaling (VAS) method 12 months after the operation. Additionally, patients' satisfaction was assessed by VAS scoring, in which 0 corresponded to the absence of satisfaction and 10 represents the perfect satisfaction with the result (Figs. 2 and 3).

#### Statistical Analyses

The results were presented as mean  $\pm$  standard deviation (SD) for quantitative variables and were summarized by absolute frequencies and percentages for categorical variables. The normality of data was checked using the Kolmogorov Smirnov test. Categorical variables were com-

pared using the Chi-square test or Fisher's exact test. Quantitative variables were also compared by t-test or Mann U test. SPSS version 16.0 for windows (SPSS Inc., Chicago, IL., USA) was used for the analyses. P values below 0.05 were considered statistically significant.

## Results

Seventy-two patients (4 men, 68 women; mean age of all patients, 26.40±4.61 years) entered the study. Twenty-seven candidates underwent rhinoplasty plus nasal tip defatting (group A). Open rhinoplasty alone (without nasal tip defatting procedure) was performed for the other 45 patients in the control group (group B). The mean age of patients in the intervention and control groups were 26.62±7.25 years and 26.26±4.85 years, respectively, indicating no significant difference ( $p=0.745$ ).

The mean nasal tip thickness was 3.98±0.84 mm in group A and 3.69±0.64 mm in group B before the surgery ( $p=0.059$ ). The preoperative nasal supra-tip thickness of the patients was also assessed using ultrasonography (3.54±0.72 mm in group A versus 3.73±0.54 mm in group B;  $p=0.065$ ). Both preoperative tip and supra-tip thickness did not statistically differ between the two groups.

Twelve months after the aesthetic rhinoplasty, tip and supra-tip thickness were measured by an ultrasonography device. Surgeons' and patients' satisfaction was also determined based on the VAS scoring system. As mentioned, 16 patients were lost to follow-up.

Regarding postoperative outcomes, no significant difference in postoperative tip skin thickness was obtained between the two groups (3.24±1 mm in group A versus 3.25±0.625 mm in group B;  $p=0.960$ ), while postoperative supra-tip skin thickness differed significantly according to the ultrasonography assessments (2.86±0.60 mm in group A versus 3.25±0.71 mm in group B;  $p=0.016$ ). Regarding the aesthetic result of rhinoplasty on nose appearance, postoperative satisfaction of the candidates was obtained using the VAS scoring system 12 months after the operation in both groups (8±1 in group A, 7.5±1 in group B;  $p=0.021$ ). Surgeon's satisfaction in terms of the aesthetic outcome was also assessed based on the VAS system which did not statistically differ between the two groups as well as the patients' satisfaction (7.84±1.42 in group A, 7±1.61 in group B;  $p=0.014$ ) (Table 1).

## Discussion

Owing to a close link between nasal skin thickness and aesthetic outcomes, especially among patients with thick nasal skin, novel interventions like nasal tip defatting plus rhinoplasty surgery have been evolved. However, long-term outcomes of this method are not completely clear. Close observation of thickness changes in nasal skin following any reconstructive surgery could be possible using high-resolution ultrasonography and CT scanning. Therefore, the present study aimed to assess the nasal skin thickness reduction and postoperative surgeon's and patients' satisfaction with the cosmetic outcomes between rhinoplasty with and without defatting.

No significant difference was found in nasal tip skin thickness between the two methods in our study. In fact, thickness reduction of the nasal tip skin using the defatting method was not remarkable. However, rhinoplasty plus defatting method led to a significant decrease in supra-tip skin thickness postoperatively. In a similar study by Niazi et al. in 2018 (13), mid-term follow-ups revealed reduced skin thickness and contracture in the nasal tip. On the other hand, in another study by Nemati et al. in 2013 (14), defatting techniques had no effects on reducing tip and supra-tip skin thickness after rhinoplasty in moderate to thick skins. In their study, no postoperative complications were reported after a one-year follow-up.

Since patients' satisfaction (in terms of the aesthetic outcome) is the main goal of aesthetic interventions, combining defatting with open rhinoplasty could lead to higher satisfaction among patients as well as the surgeon based on our results.

Overall, tip defatting is one of the surgical approaches for thereconstruction of the nasal tip. Some core principles have been advocated in this procedure to achieve proper outcomes including maximal conservation of native tissue of nasal tip area (15). Nasal skin thickness is generally associated with subcutaneous and glandular tissues and the thickest skin is seen in the tip and supra-tip zones (16). Thicker skin with subcutaneous fatty tissues heals slower and is associated with more edema, and scar formation following nose jobs. For this reason, rhinoplasty candidates with thick skin are usually less satisfied with the outcomes (17).

In nasal cosmetic surgery, getting the best results re-

Table 1. Pre- and postoperative skin parameters between two groups of rhinoplasty with or without defatting procedure

Index	Rhinoplasty with defatting (Intervention group; A)	Rhinoplasty without defatting (Control group; B)	P-value
Number of Subjects	27	45	
Age, years	26.62±7.25	26.26±4.85	0.745
Male / Female	1(3.70%)/26(96.29%)	3(6.66%)/42(93.33%)	0.662
Tip thickness, mm:			
Before surgery	3.98±0.84	3.69±0.64	0.059
After surgery	3.24±1	3.25±0.625	0.960
Supra-tip thickness, mm:			
Before surgery	3.54±0.72	3.73±0.54	0.065
After surgery	2.86±0.60	3.25±0.71	0.016
Surgeon's satisfaction (After Surgery), 0-10	7.84±1.42	7±1.61	0.014
Patients' satisfaction (After Surgery), 0-10	8±1	7.5±1	0.021

Data are "Mean ± SD" or number (percentage) based on the type of variables.

quires precise attention to the tip skin and supra-tip substrates as well as the soft tissues in these zones. Skin defatting is one of the surgical options for this purpose (18). This method is not recommended for noses with thin skin, but several investigations have recommended removing the extra subcutaneous tissues of the nasal tip in thick skin (19-21).

Jomah et al. determined the thickness of nasal tip skin by CT scan and reported that nasal tip thickness of more than 3.4 mm was associated with poorer cosmetic outcomes, while those less than 3.1 seemed to have proper results (4).

According to Davis et al., thick-skinned noses greater than 5 mm measured by ultrasonography were considered ultrathick noses. It was also reported that SMAS resection should not be done for noses at a thickness of less than 3 mm because of the probable damage to the blood supply and causing excessive thinning or problems in the structure of the nose (22).

This research was conducted as a quasi-experimental study. We faced some limitations for enrolling participants and possible operator-related errors in ultrasonography. Generally, there is limited evidence to compare the clinical efficacy of open rhinoplasty alone and in combination with nasal tip defatting. Therefore, it is suggested to perform further clinical trials with larger sample size, including both genders. Also, further studies could be performed by randomization of allocation.

### Conclusion

Contrary to previous investigations, our findings showed no significant reduction in nasal tip skin thickness using the defatting technique, while the thickness of nasal supra-tip skin was significantly reduced in this method. Moreover, from the patients' and surgeon's points of view, such a procedure could result in higher postoperative satisfaction compared to open rhinoplasty surgery alone regarding postoperative aesthetic outcomes.

### Acknowledgements

We would like to gratefully record our appreciation to all patients who participated in this study.

### Conflict of Interests

The authors declare that they have no competing interests.

### References

- Garramone RR, Jr., Sullivan PK, Devaney K. Bulbous nasal tip: an anatomical and histological evaluation. *Ann Plast Surg.* 1995;34(3):288-90; discussion 90-1.
- Hafezi F, Naghibzadeh B, Nouhi A. Management of the thick-skinned nose: A more effective approach. *Ann Otol Rhinol Laryngol.* 2006;115(6):444-9.
- Cho GS, Kim JH, Yeo NK, Kim SH, Jang YJ. Nasal skin thickness measured using computed tomography and its effect on tip surgery outcomes. *Otolaryngol Head Neck Surg.* 2011;144(4):522-7.
- Jomah J, Elsafi RA, Ali K, Abdullah R, Gelidan AG. Nasal Skin Thickness Measurements Using Computed Tomography in an Adult Saudi Population. *Plast Reconstr Surg Glob Open.* 2019;7(9):e2450.
- Tasman AJ. Effect of nasal tip skin thickness on the outcome of tip refining surgery quantified previously. *Otolaryngol Head Neck Surg.*

- 2011;145(5):881.
- Tardy ME. *Rhinoplasty: the Art and the Science.* Philadelphia: Saunders;1997.
- Slupchynskij O, Cranford J. Quantitative Measurements of the Bulbous Tip in Ethnic Rhinoplasty. *Ann Plast Surg.* 2017;78(5):569-75.
- Saban Y, Andretto Amodeo C, Hammou JC, Polselli R. An anatomical study of the nasal superficial musculoaponeurotic system: surgical applications in rhinoplasty. *Arch Facial Plast Surg.* 2008;10(2):109-15.
- Bianchi B, Ferri A, Ferrari S, Copelli C, Sesenna E. Improving esthetic results in benign parotid surgery: statistical evaluation of facelift approach, sternocleidomastoid flap, and superficial musculoaponeurotic system flap application. *J Oral Maxillofac Surg.* 2011;69(4):1235-41.
- Chu E, Davis RE. SMAS Debulking for Management of the Thick-Skinned Nose. *JAMA Facial Plast Surg.* 2015;17(4):305-6.
- Davis RE, Wayne I. Rhinoplasty and the nasal SMAS augmentation graft: advantages and indications. *Arch Facial Plast Surg.* 2004;6(2):124-32.
- Dey JK, Recker CA, Olson MD, Bowen AJ, Panda A, Kostandy PM, et al. Assessing Nasal Soft-Tissue Envelope Thickness for Rhinoplasty: Normative Data and a Predictive Algorithm. *JAMA Facial Plast Surg.* 2019;21(6):511-7.
- Niazi F, Niazi S, Alizadeh Otaghvar H, Goravanchi F. Clinical evaluation of safety and complications of the nasal tip defatting in rhinoplasty. *Res Bull Med Sci.* 1970;23(1):e7.
- Nemati S, Banan R, Alizadeh A, Leili EK, Kerdari H. Ultrasonographic evaluation of long-term results of nasal tip defatting in rhinoplasty cases. *Laryngoscope.* 2013;123(9):2131-5.
- Rohrich RJ, Griffin JR, Ansari M, Beran SJ, Potter JK. Nasal reconstruction--beyond aesthetic subunits: a 15-year review of 1334 cases. *Plast Reconstr Surg.* 2004;114(6):1405-16; discussion 17-9.
- Tardy ME TJ. *Rhinoplasty.* 4th ed. Cummings CW FP, Harker, LA ea, editors. Elsevier Mosby: Philadelphia, PA; 2005.
- Tysome JR SH. Current trends in photographic imaging for rhinoplasty surgery. *Int J Otolaryngol.* 2006;5(2).
- Clark MP, Greenfield B, Hunt N, Hall-Craggs M, McGrouther DA. Function of the nasal muscles in normal subjects assessed by dynamic MRI and EMG: its relevance to rhinoplasty surgery. *Plast Reconstr Surg.* 1998;101(7):1945-55.
- Gurlek A, Fariz A, Aydogan H, Ersoz-Ozturk A, Eren AT. Effects of different corticosteroids on edema and ecchymosis in open rhinoplasty. *Aesthetic Plast Surg.* 2006;30(2):150-4.
- Letourneau A, Daniel RK. The superficial musculoaponeurotic system of the nose. *Plast Reconstr Surg.* 1988;82(1):48-57.
- Sun GK, Lee DS, Glasgold AI. Interdomal fat pad: an important anatomical structure in rhinoplasty. *Arch Facial Plast Surg.* 2000;2(4):260-3.
- Davis RE, Hrisomalos EN. Surgical Management of the Thick-Skinned Nose. *Facial Plast Surg.* 2018;34(1):22-8.