

# DIFFERENTIATION BETWEEN BENIGN, REACTIVE AND MALIGNANT CELLS IN SEROVAL BODY FLUIDS BY AgNOR STAINING

S. TORABI-NEZHAD, M.D., AND A. AZARIAN, M.D.

*From the Department of Pathology, Shiraz Medical  
School, Shiraz University of Medical Sciences, Shiraz, I.R. Iran.*

## ABSTRACT

Argyrophilic nucleolar organizer regions (AgNORs) were determined in 94 pleural, pericardial and peritoneal effusions. The results were correlated with cytologic diagnosis to determine the diagnostic potential of this technique. Cytologically the number of normal, reactive and malignant effusions were 32, 28 and 34 respectively.

The mean AgNOR counts for normal, reactive and malignant specimens were 1.365, 2.328 and 4.747 respectively. The cut-off points between normal-reactive and reactive-malignant specimens were 1.84 and 3.53 respectively. All of the malignant specimens (100%) had AgNOR counts above 3.53.

Neither reactive nor normal specimens had AgNOR counts above 3.53. 82.1% of reactive specimens had AgNOR counts above 1.84 and 87.5% of normal specimens had AgNOR counts below this point.

There was a statistically significant difference between the AgNOR counts in normal, reactive and malignant effusions ( $p < 0.001$ ).

We conclude that the AgNOR method is a specific diagnostic tool for serosal cavity effusions, especially when malignancy is suspected.

*MJIRI, Vol. 16, No. 2, 95-100, 2002.*

## INTRODUCTION

Nucleolar organizer regions (NORs) represent loops of ribosomal DNA, located in the nucleoli of chromosomes 13,14,15, 21, and 22 which are responsible for the transcription of ribosomal RNA, the main protein synthesis region.<sup>1,2,17,29</sup> Therefore it has been suggested that the number of NORs may reflect nuclear and cellular activity.<sup>1,17,23,29</sup> NORs are argyrophilic because their associated acidic proteins (i.e., C<sub>23</sub>, B<sub>23</sub> and possibly their RNA polymerase-I) contain abundant sulfhydryl and carboxy groups which precipitate silver ions.<sup>17</sup> NORs can therefore be visualized as intranuclear black dots by his-

tochemical staining with a colloid silver solution.<sup>29</sup>

Ploton et al. first modified the AgNOR technique for paraffin-embedded formalin fixed tissues.<sup>27</sup> Then Crocker and his colleagues reported the application of the AgNOR technique for diagnostic tumor pathology.

This method has been used for many types of benign and malignant lesions including breast,<sup>29</sup> colon,<sup>34</sup> cervix,<sup>4</sup> endometrium,<sup>6</sup> melanocytic skin lesions,<sup>23</sup> non-Hodgkin's lymphoma,<sup>24</sup> acute leukemia,<sup>25</sup> chordoma<sup>28</sup> and prostate.<sup>17</sup>

Ayres et al. were the first scientists who applied the AgNOR technique on paraffin-embedded mesothelial biopsy (pleura) specimens to differentiate malignant from normal and reactive mesothelial cells in 1988.<sup>2</sup>

The first application of this technique on human effusion for differentiating between malignant, normal and reactive mesothelial cells was performed by Derenzini et al. in 1989.<sup>15</sup>

**Correspondence:** S. Torabi-Nezhad, M.D., Department of Pathology, Shiraz Medical School, Shiraz University of Medical Sciences, Shiraz, I.R. Iran.

Cytologic evaluation of serosal cavity effusions for malignancy is used routinely in the diagnosis, prognosis and therapeutic management of malignant neoplasms.<sup>9,35,36</sup> Studies, however, have shown that such evaluation renders a high false negative rate.<sup>9,26,31</sup>

In this study we have investigated the utility of the AgNOR technique as an adjunct to cytologic diagnosis in serosal effusions to differentiate between benign mesothelial cells, reactive mesothelial cells and malignant cells.

## MATERIAL AND METHODS

Pleural, peritoneal and pericardial effusion slides were selected from the files of cytology departments of Shahid Beheshti, Nemazee and Shahid Faghihi hospitals, from 1980 to 1999. 94 specimens of those were selected and classified as metastatic carcinoma, reactive and normal. 34 cases were malignant, 15 of them from pleural effusions (5 of the breast, 4 of the GI tract, 1 of the endometrium, 3 of the lung and 2 of the thyroid), 18 from peritoneal fluids (12 of the GI tract, 1 of the pancreas, 4 of the ovaries and 1 of the liver) and one from pericardial effusion of a patient with metastatic adenocarcinoma of the GI tract.

28 cases were reactive effusions including 19 pleural, one pericardial and eight peritoneal fluids.

32 cases were from normal effusions including 17 pleural, one pericardial and 14 peritoneal fluids.

The AgNOR staining was performed on air dried smears.

The procedure was as follows:

### A: Materials for AgNOR staining

- 1- Silver nitrate
- 2- Gelatin
- 3- Formic acid
- 4- 3:1 mixture of absolute ethanol: acetic acid
- 5- Deionized distilled water
- 6: Distilled water
- 7: Xylene

### B: Making of AgNOR solution

AgNOR solution: 2 parts of solution A + 1 part of solution B

Solution A: 50% aqueous silver nitrate.

Solution B: 2g gelatin and 1mL formic acid in 100mL deionized distilled water.

### C: Method of staining

Air-dried smears were fixed for 15 minutes in a 3:1 mixture of absolute ethanol: acetic acid and progressively rehydrated. The slides were then washed three times in deionized distilled water and placed in a freshly prepared

staining solution for 30 minutes at room temperature in the dark, dehydrated with xylene and then counted.

### D: Method of AgNOR counting

In light microscopic examination, 200 random nuclei in each slide were counted, using a 100x oil-immersion objective and a 10 ocular. Only nuclei of mesothelial or epithelial cells were evaluated.

Inflammatory cells (PMNs, lymphocytes and macrophages) were excluded. All argyrophilic black dots in nucleolar and extranucleolar areas were counted and the mean was calculated in each case.

### E: Pap and Wright stain

Before AgNOR staining and for confirming the previous results of pap and Wright methods, the pap and wright stained slides of each case were evaluated again.

### F: Screening of cases

The pap and Wright stained slides with good preparation (staining and fixation) for the three groups of our study (normal, benign reactive and malignant) were selected.

We also considered that the number of mesothelial cells in normal and benign reactive groups be adequate for evaluation (>200). Then the counterpart air-dried slides for AgNOR staining were prepared.

### G: Comparing of AgNOR with pap and Wright methods

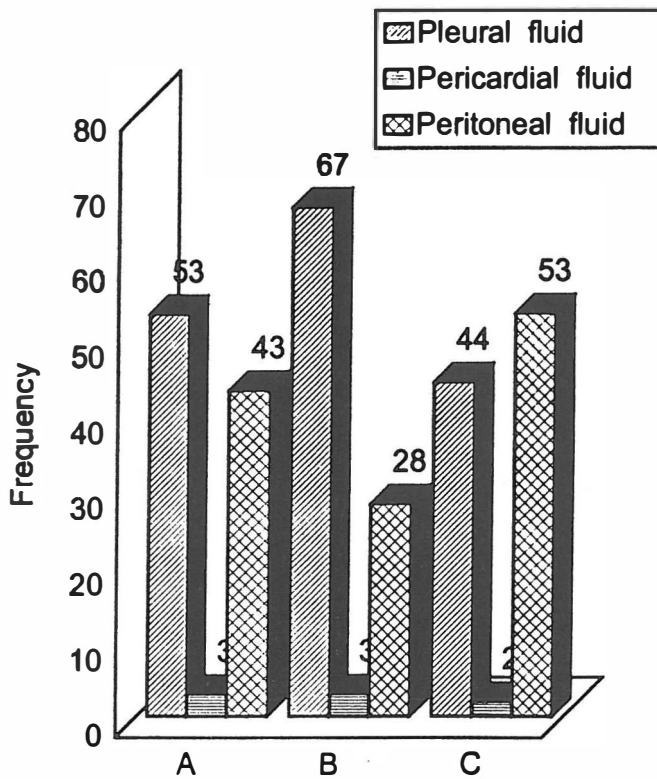
After AgNOR staining, the mean number, distribution and size of AgNOR black dots on each nucleus were counted, evaluated and compared with the counterpart pap and Wright results.

## RESULTS

Cytomorphologically 32 cases (34%) were normal, 28 (29.8%) reactive and 34 (36.2%) malignant. The mean ages for each group of normal, reactive and malignant effusions were 40.78, 54.07 and 54.87 years respectively.

The sex distribution in each group was as follows: Normal effusion: Female: 53.1%, Male: 46.9%; Reactive effusion: Female: 50%, Male: 50%; Malignant effusions: Female: 52.9%, Male: 47.1%.

Fig. 1. shows the abundance of different types of body effusions in each group. The total AgNOR counts in the 32 normal samples ranged from 0.7 to 2.1 (mean:  $1.365 \pm 0.378$  SD) (Figs. 2-3). The range of AgNOR counts in the reactive effusions was from 1.2 to 3.1 (mean:  $2.328 \pm 0.502$  SD) (Figs. 2-3). The range of AgNOR counts in malignant effusions was from 3.9 to 6.5 (mean:  $4.747 \pm 0.657$  SD), (Fig. 2-3). The cut-off points between normal-reactive and reactive-malignant



**Fig. 1.** The abundance of different types of body effusions in three groups of normal, reactive and malignant patients.

A: Normal mesothelial cells  
B: Reactive mesothelial cells  
C: Malignant cells.

samples were 1.84 and 3.53 respectively. 34 (100%) of the malignant effusions had AgNOR counts above 3.53.

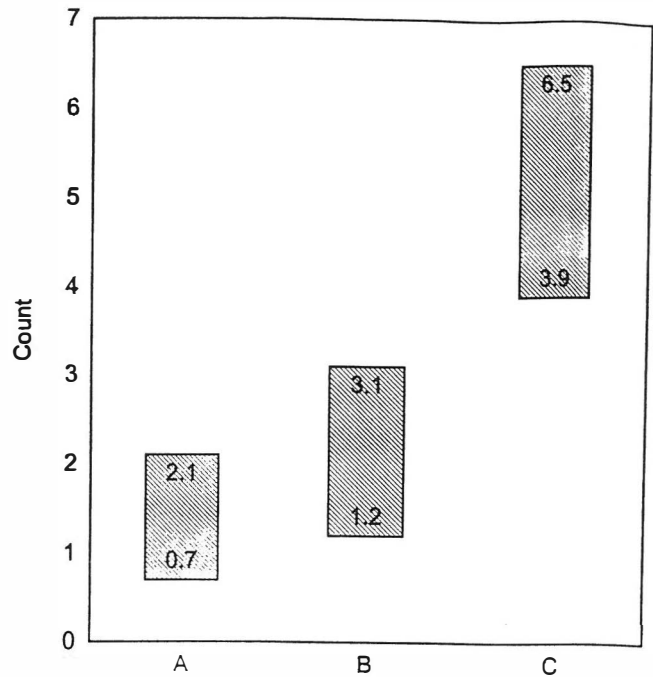
23 (82.1%) of the reactive samples had AgNOR counts above 1.84, and 5 (17.9%) of them showed overlapping with normal effusions. None of these samples had AgNOR counts above 3.53. 28 cases (87.5%) of normal effusions had AgNOR counts below 1.84 and 4 of them (12.5%) showed overlapping with reactive samples. None of these effusions had AgNOR counts above 3.53.

There was a statistically significant difference between the AgNOR counts in normal, reactive and malignant effusions ( $p < 0.001$ ).

The AgNOR black dots were more irregularly distributed and variably sized in cancer cells than in reactive or normal mesothelial cells. (Figs. 4-7).

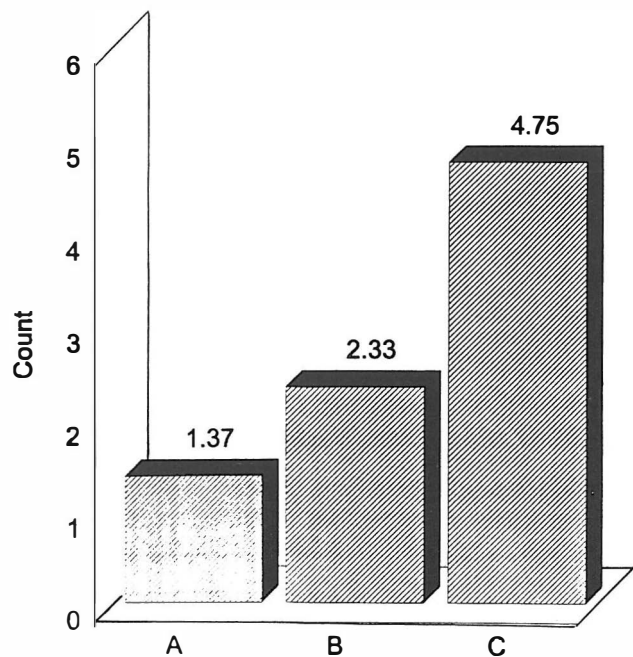
## DISCUSSION

In cytologic preparations of serosal fluids, the diagnosis of malignancy is frequently difficult, because malignant cells frequently lose their in situ organization and their relationship with surrounding tissues that normally renders the nature of the lesion to be easily recognisable.



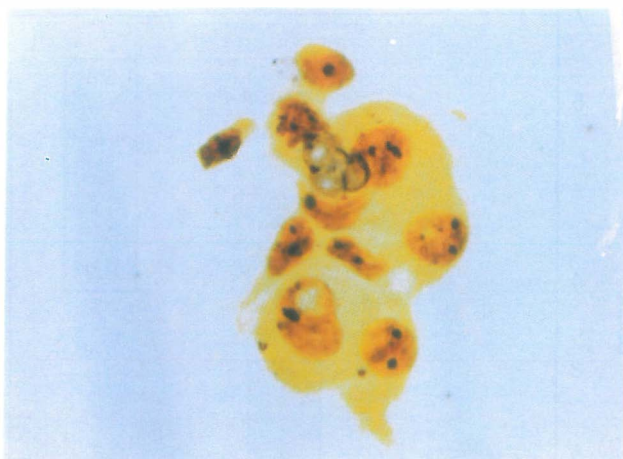
**Fig. 2.** Range of AgNOR count in normal, reactive and malignant body fluids.

A: Normal mesothelial cells  
B: Reactive mesothelial cells  
C: Malignant cells.

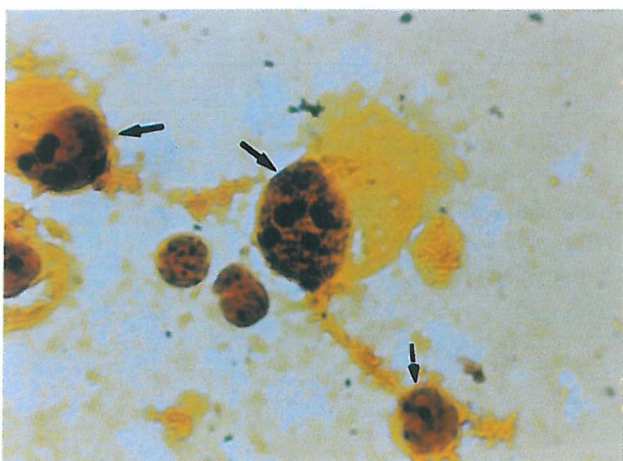


**Fig. 3.** Mean AgNOR count in three groups of normal, reactive and malignant body fluids.

A: Normal mesothelial cells  
B: Reactive mesothelial cells  
C: Malignant cells.



**Fig. 4.** A cluster of reactive mesothelial cells. Note black dots on nuclei (AgNOR stain, x1000).



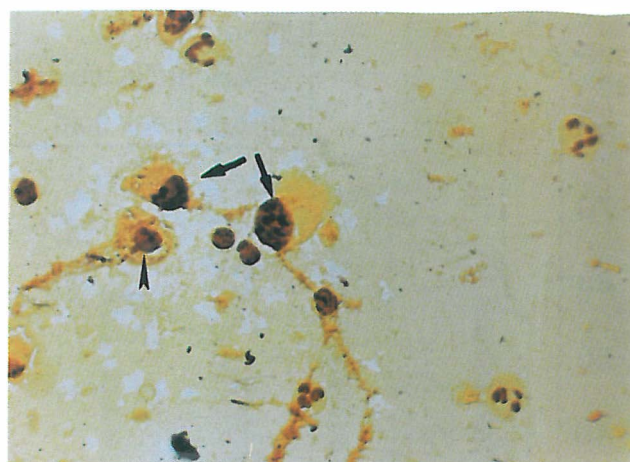
**Fig. 5.** Some malignant cells (arrow). Note numerous irregular black dots on cancerous nuclei (AgNOR stain, x1000).

Indeed, it is not always possible to distinguish neoplastic cells from reactive mesothelial cells on purely morphologic grounds.<sup>15</sup>

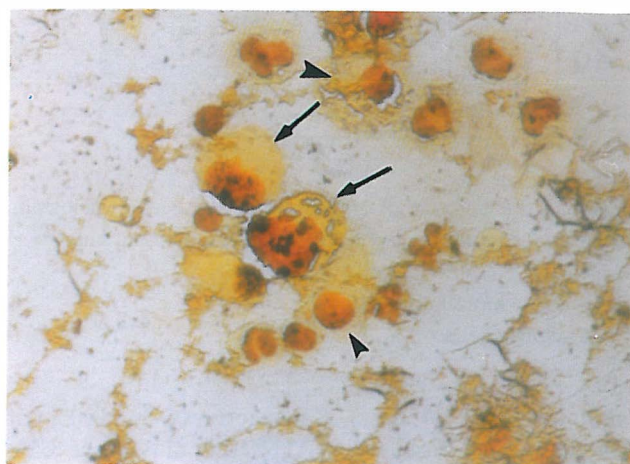
Detection of proliferating cell nuclear antigen (PCNA) is a technique which can be used for differentiating carcinoma cells from reactive mesothelial cells. PCNA is a non-histone nuclear protein which is an auxiliary protein for DNA polymerase and a marker for cell proliferation.<sup>3</sup>

Many studies have reported the use of other immunocytochemical techniques to differentiate carcinoma cells from reactive mesothelial cells.<sup>18,19,33</sup>

To solve this problem, many scientists have recently shown interest in the AgNOR technique.<sup>15</sup> The silver-staining method used in the present investigation was initially used as a very simple method for visualizing the NORs in metaphase chromosomes<sup>20,21</sup> (NORs are DNA loops encoding riboso-



**Fig. 6.** Some malignant cells (arrow), a mesothelial cell (arrow head), a few lymphocytes and PMNs. Note irregular black dots on malignant nuclei (AgNOR stain, x400).



**Fig. 7.** Two malignant cells (arrow), some mesothelial cells (arrow head), a few lymphocytes and PMNs. Note numerous, irregular black dots on malignant nuclei (AgNOR stain, x400).

mal RNA production).<sup>15</sup>

Many studies have demonstrated that silver-staining methods selectively stain acidic proteins (AgNOR proteins) associated with the ribosomal sequences. The application of silver staining for AgNOR proteins to interphase nuclei showed the localization of the ribosomal genes in the fibrillar components of the nucleolus (fibrillary centers and dense fibrillary component) which thus represent the interphase counterpart of metaphase NORs.<sup>20,21</sup>

It has long been known that malignant cells have hypertrophic and irregular shaped nucleoli with irregular distribution of the nucleolar components.<sup>7,8-22</sup> These morphologic abnormalities can be quantified using the distribution of interphase NORs in nucleoli as a parameter.<sup>14,15</sup>



AgNOR staining was first applied to distinguish benign nevi from melanoma and then to distinguish other benign from malignant lesions.<sup>12,13</sup> Many authors believe that an increased number of interphase NORs is a good clue to differentiate malignant from benign cells. In addition to an increased number of NORs, malignant cells were characterized by irregularly scattered and heterogen sized NORs. This may also help for differentiation between benign and malignant cells.

Studies on body effusions showed a significant difference in AgNOR numbers between malignant cells (mesothelial versus non-mesothelial), normal and reactive mesothelial cells.<sup>3,9,10,11,15,30,32</sup>

Our study shows that the interphasic NOR distribution pattern permits a clear distinction to be made between neoplastic cells, benign reactive and normal mesothelial cells in human effusions.

NORs in neoplastic cells are very numerous and have heterogeneity in size and irregular distribution throughout the nucleus.

Reactive mesothelial cells have a more regular distribution of the NORs than neoplastic cells and significantly less numbers of AgNOR dots than neoplastic cells.

In these three groups (normal, benign reactive and malignant) the normal mesothelial cells have the least AgNOR counts with uniformly sized, small black dots. The difference between normal, reactive mesothelial and neoplastic NORs was also demonstrated by a quantitative analysis of the mean NOR areas.

Therefore, the different quantity of interphasic NORs in normal, reactive mesothelial cells and metastatic neoplastic cells might be explained by different proliferative rates of these cells.

The present study indicates that silver-staining for AgNOR proteins should be used routinely in diagnostic cytology. Also this reliable method gives information about the NOR distribution pattern that permits a diagnosis of malignancy even if the tumor cells represent only a small portion of all cells in the effusion.

## REFERENCES

1. Albert B, Bray D, Lewis J, et al: Molecular biology of the cell. New York: Garland Publishing, pp. 424-426, 1983.
2. Ayres JG, Crocker JG, Skilbeck NQ: Differentiation of malignant from normal and reactive mesothelial cells by argyrophilic technique for nucleolar organizer region associated proteins. *Thorax* 43:366-70, 1988.
3. Bethwaite PB, Delahunt B, Holloway LJ, et al: Comparison of silver staining nucleolar organizer region (AgNOR) counts and proliferating cell nuclear antigen (PCNA) expression in reactive mesothelial hyperplasia and malignant mesothelioma. *Pathology* 27: 1-4, 1995.
4. Bharucha H, Mc Cluggage G, Lee J, et al: Grading cervical dysplasia with AgNORs using a semiautomated image analysis system. *Analytical and Quantitative Cytology and Histology* 15(5):323-8, 1993.
5. Naylor B: Pleural, peritoneal and pericardial fluids. In: Bibbo M, (ed.), *Comprehensive Cytopathology*. Second edition, Philadelphia: W.B. Saunders, pp. 560-563, 1997.
6. Brustmann H, Riss P, Naude S: Nucleolar organizer regions as markers of endometrial proliferation. A study of normal, hyperplastic and neoplastic tissue. *Human Pathology* 26 (6): 664-7, 1995.
7. Bolognari A, Contini A: The role of the nucleolus in carcinogenesis. *Riv Biol Norm Pathol* 7: 43-68, 1981.
8. Busch H, Smetana K: Nucleoli of tumor cells, In: Smetana K, (ed.), *The Nucleolus*. New York: Academic Press, pp. 448-471, 1970.
9. Carrillo R, Sneige N, El-Naggar AK: Interphase nucleolar organizer regions in the evaluation of serosal cavity effusions. *Acta-Cytol* 38: 367-372, 1994.
10. Colecchia M, Agnelli T, Caronni E, et al: Utility of morphometry and NORs count in the differentiation of reactive and malignant mesothelial cells in pleural effusions. *Pathologica*; Jan-Feb 83 (1083): 89-97, 1991.
11. Colecchia M, Leopardi O: Evaluation of AgNOR count in distinguishing benign from malignant mesothelial cells in pleural fluids. *Path Res Pract* 188: 541-4, 1988.
12. Crocker J, Nav P: NORs in lymphomas. *J Pathol* 151: 111-18, 1987.
13. Crocker J, Skilbeck N: NORs associated proteins in cutaneous melanocytic lesions: a quantitative study. *J Clin Pathol* 40: 885-889, 1987.
14. Derenzini M, Hernandez-Verdun D, Pession A, et al: Structural organization of chromatin in NORs of nucleoli with a nucleonema-like and compact ribonucleoprotein distribution. *J Ultrastruct Res* 84: 161-172, 1983.
15. Derenzini M, Nardi F, Farabegoli F, et al: Distribution of silver-stained interphase NORs as a parameter to distinguish neoplastic from non-neoplastic reactive cells in human effusions. *Acta Cytologica* 33: 491-498, 1989.
16. Derenzini M, Romagnoli T, Mingazzini P, et al: Interphasic NOR distribution as a parameter to differentiate benign from malignant epithelial tumors of human intestine. *Virchows Archive (Cell Pathol)* 54: 334-340, 1988.
17. Deschenes J, Weidner N: NORs in hyperplastic and neoplastic prostate disease. *The American Journal of Surgical Pathology* 14 (12): 1148-1155, 1990.
18. Epenetos AA, Canti G, T-Papadimitriou J, et al: Use of two epithelium-specific monoclonal antibodies for diagnosis of malignancy in serous effusions. *Lancet* 2: 1004-1006, 1982.
19. Ghosh R, Gatter KC, Dunnill MS, et al: Immunohistochemical staining of reactive mesothelium, mesothelioma and lung carcinoma with a panel of monoclonal antibodies. *J Clin Pathol* 40: 19-25, 1987.

## AgNOR Staining of Serosal Body Fluids

20. Goessens G: Nucleolar structure. *Int Rev Cytol* 84: 107-158, 1984.
21. Howell WM: Selective staining of nucleolar organizer regions. In: Busch H, Rothblum L, (eds.), *The Cell Nucleus*. Volume 11, New York: Academic Press, pp. 89-142, 1982.
22. Koller PC: The nucleus of the cancer cells: a historical review. *Exp Cell Res (Suppl)* 9: 3-14, 1963.
23. Leong ASY, Gilham P: Silver staining of NORs in malignant melanoma and melanocytic nevi. *Human Pathol* 20 (3): 257-262, 1989.
24. Mankata S, Hendricks JB: Morphometric analysis of AgNORs in imprint and sections from Non-Hodgkin's lymphoma, an approach to standardization. *Analytical and Quantitative Cytology and Histology* 15 (5): 329-334, 1993.
25. Nakamura S, Takeda Y, Okabe Y, et al: Argyrophilic proteins of the NOR in acute leukemias and it's relation to the S-phase fraction of leukemic cells. *Acta Hematologica* 87: 6-10, 1992.
26. Pinto MM: DNA analysis of malignant effusion, comparison with cytologic diagnosis and CEA antigen content. *Analyt Quant Cytol Histol* 4: 222-226, 1992.
27. Ploton D, Manager M, Jeannesson P, et al: Improvement in staining and in the visualization of the argyrophilic proteins of the NOR at the optical level. *Histochem J* 18: 5-14, 1986.
28. Schoedel KE, Martinez AJ, Mahoney TM, et al: Chordomas, pathological features, polidy and silver NORs analysis. A study of 36 cases. *Acta Neuropathologica Berlin* 89 (2): 132-143, 1995.
29. Sivitidis E, Sims B: NORs, new prognostic variable in breast carcinomas. *J Clin Pathol* 43: 390-392, 1990.
30. Sujathan K, Kannan S, Pillai KR, et al: Significance of AgNOR count in differentiating malignant cells from reactive mesothelial cells in serous effusions. *Acta Cytologica* 40 (4): 724-728, 1996.
31. Taft P, Arizaga-Cruz J: A comparison of cell block, Papanicolaou and Millipore filter techniques for the cytologic examination of serous fluids. *Am J Clin Pathol* 34: 561-564, 1960.
32. Trevisan MS, Souza MI, Magna LA: NORs of mesothelial and carcinomatous cells in effusions. *Diagn Cytopathol* 9 (5): 492-7, 1993.
33. Woods JC, Spriggs AL, Harris H, et al: A new marker for human cancer cells: 3: Immunocytochemical detection of malignant cells in serous fluids with the Ca 1 antibody. *Lancet* 2: 512-515, 1982.
34. Yang P, Huang GS, Zhu XS: Role of NORs in differentiating malignant from benign tumors of the colon. *Journal of Clinical Pathology* 43: 235-238, 1990.
35. Yoshimura S, Scully R, Taft P, et al: Peritoneal fluid in patients with ovarian cancer. *Gynecol Oncol* 17: 161-167, 1984.
36. Zuna RE, Mitchel ML, Mulick KA, et al: Cytohistologic correlation of peritoneal washing cytology in gynecologic disease. *Acta Cytol* 33: 327-336, 1989.