

Basic Science in Medicine

PHENYTOIN AND THE REPRODUCTIVE SYSTEM

G.D. NAYERI KAMAN, Ph.D., AND F. MOTIOLLAH, M.Sc.

*From the Department of Physiology, School of Medicine,
Shiraz University of Medical Sciences,
Shiraz, I.R. Iran.*

ABSTRACT

In order to evaluate the effects of phenytoin on the reproductive system of rats in detail, 60 male rats were divided equally into 6 groups: 1-5 received 10 mg/kg/day phenytoin IP for 1,2,3,4 and 5 weeks, respectively. However, group 5 did not receive any phenytoin for the last 5th week. The control group (group 6) did not receive any treatment. The results revealed that phenytoin does not have any effect on body weight, weight of testes, seminal vesicle and prostate, serum testosterone and sperm count taken from left and right vas deferens. However, the percentage of total motile sperm and sperm with full and sluggish motility decreased and the percentage of low motile sperm increased in all experimental groups. Nevertheless, phenytoin caused atrophy and hypoplasia in seminiferous tubules and not Leydig cells. These pathological changes were dose-dependent and more pronounced in the left testis. But phenytoin caused more changes in sperm count and motility of the right testis. This phenomenon was discussed in relation to the existence of asymmetrical control by the hypothalamus, and compensation of the left testis. In summary, it could be concluded that phenytoin affected the seminiferous tubules directly and decreased the total number of motile sperm. It was also discussed that these effects are not reversible after termination of injection.

MJIRI, Vol. 16, No. 1, 35-40, 2002.

Keywords: Phenytoin, testosterone, sperm count and motility, genital system.

INTRODUCTION

Men with epilepsy experience more sexual dysfunction than do men in the general population.^{16,20} Altered sexual interest and reproductive dysfunction are usually common among men who have temporal lobe epilepsy.¹² It is well known that in patients with epilepsy the serum concentrations of several hormones may be different from those of the normal population of similar age.^{9,11} It has been shown that reproductive and sexual dysfunction in men with epilepsy have been attributed to androgen deficiency.¹⁰ Nevertheless, antiepileptic drugs may alter the

release and action of different hormones.¹ There are some reports showing that gonadal steroid function is altered in some patients treated with antiepileptic medications, which may also contribute to sexual dysfunction.^{4,13} Phenytoin is one of the anticonvulsant compounds which is used to treat patients with epilepsy and male patients with epilepsy receiving phenytoin commonly complain of diminished libido or impotence.¹⁹

However, it is not clear whether it is epilepsy per se, the antiepileptic drugs or both together and/or the function of the hypothalamus pituitary axis, that cause changes in serum hormone levels. Nevertheless, no data

Phenytoin and the Reproductive System

Table I. Mean±SE of serum testosterone level (ng/mL) during the experiment in the 5 groups. Day 0 indicates the level of testosterone before the experiment (control for each group). Note that there are no significant changes between groups.

Day	G1	G2	G3	G4	G5
0	1.50±0.24	1.80±0.92	1.48±0.24	1.48±0.25	1.70±0.92
1	1.40±0.36	1.50±0.40	1.46±0.40	1.45±0.36	1.40±0.37
4	1.15±0.50	1.10±0.49	1.20±0.50	1.15±0.49	1.15±0.48
7	0.51±0.16	0.76±0.18	0.50±0.17	0.80±0.18	0.76±0.19
13		1.17±1.90	1.05±0.60	1.71±1.80	1.05±0.60
19			1.54±1.28	1.50±1.30	1.54±1.28
25				1.81±0.61	1.81±0.63
31					1.32±0.55

are available so far concerning the question of possible effects of phenytoin on testicular endocrine function in detail. To fill this gap, the present study was designed to investigate the possible action of one of the widely used anti-epileptic drugs, namely phenytoin, on sperm count and motility, testosterone level as well as morphology of the reproductive organ of male rats. Nevertheless, because of the existence of asymmetrical hypothalamic control on the reproductive system,^{6,18} the influence of this asymmetrical control on phenytoin effects was also investigated.

MATERIAL AND METHODS

In the present study, 60 male rats of original Wistar stock weighing between 260 to 290g were used. They were housed individually in an air-conditioned room (22±2°C) with 12:12 hr light: dark cycle and were fed pelleted food and tap water *ad libitum*. Animals were randomly divided into 6 groups consisting of 10 animals. In five experimental groups, phenytoin was injected (10 mg/kg/day) intraperitoneally once a day for one week (group 1), two weeks (group 2), three weeks (group 3), four weeks (group 4 and group 5). However, group 5 did not receive any treatment for one week after the last injection. The control group (group 6) received no treatment at all.

Testosterone analysis

Serum testosterone level was assayed using a commercially available radioimmunoassay kit. Blood samples were taken from the rat's tail the day before (accepted as a control level) and one day after the starting of phenytoin injection and thereafter once per three days throughout the experiment in groups 1-5. The blood was quickly

Table II. Mean±SE of body weights at the beginning (BW1) and the end (BW2) of the experiment. No significant differences exist between groups. * $p < 0.05$ between BW1 and BW2 in each group.

Group	BW1(g)	BW2(g)
1	270.0±4.1	267.9±14.5
2	280.9±6.0	274.8±7.9
3	271.5±2.1	277.6±3.6
4	275.7±4.7	285.0±6.8*
5	281.5±3.6	298.8±6.2*
6	277.3±4.1	289.3±4.5*

centrifuged and the plasma was stored at -20°C until assayed.

Sperm analysis

At the end of the experimental period in each group, rats were anesthetized by ether and fixed on the surgical table in supine position. Then, the catheters were inserted into the ampulla of both vas deferens and 1.5 mL of semen was taken separately from each side. The sample was diluted immediately in 0.2 mL of normal saline and evaluated separately as below: To count the sperms, one drop of diluted sperm sample was placed on a Neubauer counting chamber. Then sperms were counted on one large square as it is used in counting WBC. to evaluate sperm motility, one drop of diluted semen sample was placed on the microscopic slide. Then, ten microscopic fields (×10) were randomly investigated to calculate percentages of sperm with full, sluggish and low motilities.

Histological evaluation

At the end of the surgery, both testes and seminal

vesicles as well as the prostate were removed and weighed. Then all these organs and the vas deferens were prepared for hematoxylin and eosin staining.

Statistical analysis

Applying ANOVA and Duncan's tests analyzed comparisons among multiple groups. Comparison between two groups was tested with paired Student's t-test. Results were considered significantly different at $p < 0.05$.

RESULTS

Testosterone

Table I shows the levels of testosterone in 5 experimental groups during the period of experiment. Note that the testosterone level of each animal before starting phenytoin injection (day 0) was accepted as the control level. There were no significant changes between control value and the values obtained during different days of the experiment in the 5 groups. There is also no significant difference in serum testosterone levels between groups.

Body weight

Table II shows the body weight of the animals in the beginning and at the end of the experiment in all groups. However, at the end of the experiment, body weight increased significantly in groups 4-6 in comparison with the beginning of the experiment.

Testis

There were no significant differences in the weight of both right and left testes between groups. However, weight of the left testes were significantly more than those of the right ones in all groups except group 1 (Table III). Nevertheless, when the ratio of testicular weight to body weight was calculated, the differences between right and left were still significant in groups 2-6 ($p < 0.05$).

Prostate and seminal vesicle

Weight of seminal vesicles and prostates and their ratios to body weight were examined in all groups (1-6). There were no significant differences in these parameters between the 6 groups (Table III).

Table III. Mean \pm SE of the weight of the right testis (RT), left testis (LT), seminal vesicle (SV) and prostate (P) and their ratio to body weight (BW). No significant differences exist between groups. * $p < 0.05$ between right and left sides.

Group	Right testis		Left testis		Seminal vesicle		Prostate	
	RT (g) $\times 10^{-2}$	RT/BW $\times 10^{-4}$	LT (g) $\times 10^{-2}$	LT/BW $\times 10^{-4}$	SV (g) $\times 10^{-2}$	SV/BW $\times 10^{-4}$	P (g) $\times 10^{-3}$	P/BW $\times 10^{-5}$
1	135 \pm 4	51 \pm 2	135 \pm 4	51 \pm 2	174 \pm 1	64 \pm 4	555 \pm 43	206 \pm 15
2	127 \pm 4*	46 \pm 2*	132 \pm 3	48 \pm 1	152 \pm 8	55 \pm 3	574 \pm 40	208 \pm 13
3	132 \pm 4*	47 \pm 2*	137 \pm 4	50 \pm 2	163 \pm 8	59 \pm 3	586 \pm 39	212 \pm 16
4	130 \pm 2*	46 \pm 1*	135 \pm 2	47 \pm 1	179 \pm 1	63 \pm 4	587 \pm 33	206 \pm 11
5	131 \pm 4*	44 \pm 2*	135 \pm 3	44 \pm 1	170 \pm 1	60 \pm 5	562 \pm 26	164 \pm 13
6	126 \pm 2*	46 \pm 1*	132 \pm 1	48 \pm 1	164 \pm 5	60 \pm 1	545 \pm 31	199 \pm 5

Table IV. Mean \pm SE of sperm counts per mm³ taken from the right and left vas deferens. * $p < 0.05$ between right and left sides.

Group	Right Count	Left Count
1	2300000+329533*	1218466+187333
2	1933333+207866*	1438066+204266
3	1798866+196933	1540000+193866
4	2018333+190400	1640666+155466
5	2001446+175000	1751333+239333
6	2403333+159066*	1750200+166066

Sperm count

There were no significant changes in sperm counts taken from both vas deferens between experimental and control groups. In the control group, the sperm count of the right vas deferens was significantly more than that of the left one. This significant difference also exists in groups 1 and 2 (Table IV).

Sperm motility

As shown in Table V, the percentage of total motile sperm and sperms with full and sluggish motility taken

Phenytoin and the Reproductive System

from the right and left vas deferens were significantly higher in the sham group (group 6) compared to those of the experimental groups. However, in this group, the percentage of sperm with low motility was significantly lower than those of groups 1-5 in both right and left sides. In addition, total motile sperm taken from the right vas deferens was higher than those of the left in groups 1 and 6 (Table V). However, this higher level of total motile sperm in the right side was not significant in the other experimental groups.

Histological results

Histological examination revealed that in the control and sham groups, the number of seminiferous tubules and shape of the Sertoli and Leydig cells and also the germ cell layer were normal. However, in all experimental groups, germ cell hypoplasia and atrophy were seen. So in the seminiferous tubules, the thickness of the germ cell layer was reduced and luminal space was increased and also in the atrophied germ cell, the nucleus had disappeared and the cells were degenerated. The degree of hypoplasia and atrophy of the germ cell layer increased with an increase in the duration of treatment. However these changes in the left testis were more obvious than the right one (Fig. 1). Histological examination of vas deferens revealed that the feature of the columnar ciliary epithelium, basement membrane and thickness of the smooth muscle in all experimental groups were normal compared with control and sham groups. In the prostate, the number of the glands, the interstitial tissue and the

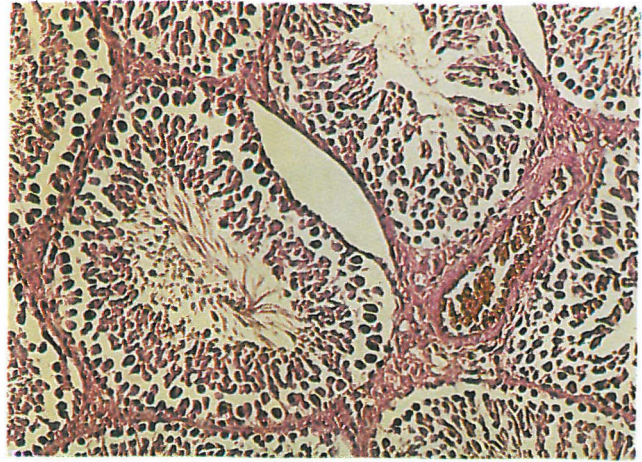


Fig. 1. Hypoplasia of seminiferous tubules after phenytoin injection. H&E staining, $\times 220$.

amount of secretion in each gland showed normal features in all experimental groups in comparison with the control and sham groups. The seminal vesicles of all rats were evaluated histologically. In all groups, the preparations showed that the number, shape and amount of secretion of the glands, as well as the features of the epithelial layer and smooth muscle were completely normal.

DISCUSSION

The present experiment revealed that in spite of atro-

Table V. Mean \pm SE of the percentages of total motile sperm and sperm with different motility taken from right and left vas deferens. Similar capital and small letters show significant differences between groups. * $p < 0.05$ between right and left sides in each group.

Group	Right				Left			
	Motile	Full	Sluggish	Low	Motile	Full	Sluggish	Low
1	Ba*	a	Ba	a	ba	a	ba	
	37.0 \pm 6.0	5.0 \pm 2.5	26.3 \pm 5.0	5.6 \pm 1.3	24.1 \pm 3.5	2.6 \pm 0.9	15.7 \pm 2.9	5.8 \pm 0.8
2	a	a	a	a	a	a	a	ba
	31.8 \pm 5.4	3.7 \pm 1.1	20.0 \pm 4.7	8.1 \pm 1.3	21.9 \pm 2.8	3.5 \pm 1.7	10.3 \pm 1.9	8.1 \pm 1.3
3	a	a	a		a	a	a	
	27.3 \pm 3.8	3.0 \pm 0.9	19.6 \pm 3.1	4.6 \pm 1.2	17.2 \pm 4.4	0.7 \pm 0.3	11.4 \pm 3.6	5.0 \pm 0.8
4	ab	a	ba	a	a	a	a	Ba
	18.2 \pm 5.0	4.0 \pm 1.4	8.7 \pm 3.8	5.5 \pm 0.6	17.0 \pm 2.9	2.5 \pm 1.1	7.4 \pm 1.7	7.1 \pm 1.4
5	ab	a	ba	a	Ba	a	Ba	B
	14.7 \pm 2.3	1.7 \pm 0.6	8.2 \pm 2.3	4.7 \pm 0.8	10.9 \pm 1.7	1.4 \pm 0.3	5.9 \pm 1.3	3.6 \pm 0.6
6	A*	A	A	A	A	A	A	A
	61.4 \pm 4.5	13.5 \pm 3.9	46.0 \pm 4.7	1.7 \pm 0.5	38.5 \pm 4.9	8.6 \pm 3.2	27.0 \pm 4.2	2.9 \pm 0.8

phy and hypoplasia of the seminiferous tubules, the sperm counts were unchanged in all experimental groups compared to the control group (Table IV). Nevertheless, it could be mentioned that sperm counts taken from right vas were significantly more than the left one in the control group and groups 1 and 2. However, this significance was not observed in groups 3-5, due to more decrease in sperm counts taken from the right side. The histological study revealed that the left testis in each experimental group showed more hypoplasia and atrophy compared to the right one and by increasing the duration of phenytoin injection, this pathological change became more pronounced. However, it seems that there should be a compensation for the left testis to prevent the decrease in sperm count in spite of having more atrophy (compare to the right testis). So, in spite of having less atrophy in the right testis, the sperm count decreased much more in the right side and the significant differences disappeared between right and left testes in groups 3-5. The existence of a central mechanism to control gonadal function by the hypothalamus asymmetrically and the existence of compensation have been recently shown by several authors.^{7,14,18} It has also been reported⁵ that atropine implanted into the left side of the preoptic-anterior hypothalamus area blocked ovulation and compensatory ovarian hypertrophy, whilst implants in the right side had no effect. Moran et al.¹⁵ also reported that the participation of the preoptic area or anterior hypothalamus area in the regulation of ovulation is asymmetric and lateralized. There are also⁸ some reports showing that the information arising in each side of the anterior and medial hypothalamus plays different roles in the ipsi- and contralateral ovary, when either the left or the right ovary was absent. Chavez et al. have also reported that the character of the information carried by the left and right vagus nerve is different, thus producing different compensation. This asymmetrical control has also been observed in the male rat by one of the authors.¹⁷ So, it is not surprising that the left testis compensated more than the right one.

However, when we studied the percentage of sperm with different motility, we noticed that the percentage of total motile sperm and sperm with full and sluggish motility in all experimental groups were significantly lower than these parameters in the control group in both left and right sides. Nevertheless, the percentage of sperm with low motility was higher in all experimental groups compared to the control (Table V). So, it seemed that the effect of phenytoin is mainly on sperm motility. As shown in Table V, total motile sperms in the right side were significantly more than the left in the control group and group 1. However, this significance vanished after long term injection of phenytoin (in groups 2-5). Nevertheless, the disappearance of significance was due to having less total motile sperm in the right side.

This observation also emphasizes the existence of hypothalamic asymmetrical control of testicular function and compensation of the left testis.

However, it must be mentioned that in the present experiment, serum testosterone levels were similar in all groups, so the effect of phenytoin was mainly on seminiferous tubules and did not have any effect on Leydig cells or prostate, seminal vesicle and vas deferens. Murialdo et al.¹⁶ also found no significant changes in testosterone level in phenytoin treated rats compared to untreated ones, in spite of a decrease in libido.

The present experiment revealed that in groups 4-6 body weight was significantly higher at the end of the experiment compared to the beginning. Nevertheless, this finding is not surprising because duration of the experiment for these groups were more than the others (25-31 days). However, Cohen et al.³ also reported that phenytoin did not have any effect on natural growth of the rat.

According to our results, there were no significant changes in right and left testis weight between different groups. But, there was a significant increase in left testis weight compared to the right ones in all groups except group 1. These differences exist when the ratio of testis weight to body weight was examined too (Table III). So, it seems that there should be a control mechanism to keep the weight of left testis unchanged, in spite of having more atrophy in the left testis.

In summary, it should be concluded that the effect of phenytoin is directly on the seminiferous tubules to produce hypoplasia and atrophy and decrease the percentage of total motile sperm. Nevertheless, the hypothalamic asymmetrical control, somehow, reduces the effect of phenytoin on the left testis to cause less decrease in motile sperm. It should also be mentioned that phenytoin does not have any effect on Leydig cells, and serum testosterone was unchanged in all experimental groups compared to the control group.

ACKNOWLEDGEMENT

The authors are to acknowledge Dr. P.V.N. Kumar, Dept. of Pathology, Shiraz Medical School, for checking the histological preparations and Dr. S.M.S. Moosavi, Dept. of Physiology, Shiraz Medical School, for valuable comments on the manuscript.

REFERENCES

1. Brunet M, Rodamilans M, Martinez-Osaba MJ, Santamaria J, To-Figueras J, Torra M, Corbella J, Rivera F: Effects of long-term antiepileptic therapy on the catabolism of testosterone. *Pharmacol Toxicol* 76 (6): 371-375, 1995.
2. Chavez R, Cruz ME, Dominguez R: Differences in the ovu-

Phenytoin and the Reproductive System

- lation rate of the right or left ovary in unilaterally ovariectomized rats: effect of ipsi- and contralateral vagus nerves on the remaining ovary. *J Endocrinol* 113 (3): 397-401, 1987.
3. Cohn DF, Homonnai ZT, Paz FG: The effect of anticonvulsant drugs on the development of male rats and their fertility. *J Neurol Neurosurgery Psychiatry* 45 (9): 844-6, 1982.
 4. Cramer JA, Jones EE: Reproductive function in epilepsy. *Epilepsia* 32 (Supple 6): S19-26, 1991.
 5. Cruz ME, Castro J, Dominguez R: A comparative analysis of the neuroendocrine mechanisms regulating ovulation affected by a unilateral implant of atropine in the preoptic-anterior hypothalamic area, in intact and hemiovariectomized adult rats. *J Endocrinol* 133 (2): 205-10, 1992.
 6. Cruz ME, Jaramillo LP, Dominguez R: Asymmetric ovulatory response induced by a unilateral implant of atropine in the anterior hypothalamus of the cyclic rat. *J Endocrinol* 123 (3): 437-9, 1989.
 7. Cruz ME, Moran JL, Jaramillo LP, Dominguez R: Differences in spontaneous ovulation in rats with unilateral lesion of the hypothalamus. *Brain Res Bull* 24 (6): 739-42, 1990.
 8. Cruz ME, Moran JL, Jaramillo LP, Dominguez R: Differential effects of a unilateral hypothalamic lesion on ovulation and compensatory ovarian hypertrophy in hemiovariectomized adult rats. *J Endocrinol* 124 (1): 37-41, 1990.
 9. Haidukewych D, Rodin E: Chronic antiepileptic drug therapy: classification by medication regimen and incidence of decreases in serum thyroxine and free thyroxine index. *Ther Drug Monit* 9 (4): 392-398, 1987.
 10. Herzog AG: Reproductive endocrine considerations and hormonal therapy for men with epilepsy. *Epilepsia* 32: 37-43, 1991.
 11. Herzog AG: Hormonal changes in epilepsy. *Epilepsia* 36 (4): 323-6, 1995.
 12. Herzog AG, Siebel MM, Schomer DL, Vaitukaitis JL, Geschwind N: Reproductive endocrine disorders in men with partial seizures of temporal lobe origin. *Arch Neurol* 43: 347-350, 1986.
 13. Isojarvi JIT, Pakarinen AJ, Ylipalosaari PJ, Myllyla VV: Serum hormones in male epileptic patients receiving anticonvulsant medication. *Arch Neurol* 47: 670-676, 1990.
 14. Lopez E, Cruz ME, Dominguez RI: Asymmetrical effects of the unilateral implant of pilocarpine on the preoptic-anterior hypothalamic area on spontaneous ovulation of the adult rat. *Arch Med Res* 28 (3): 343-8, 1997.
 15. Moran JL, Cruz ME, Dominguez R: Differences in the ovulatory response to unilateral lesions in the preoptic or anterior hypothalamic area performed on each day of the estrous cycle of adult rats. *Brain Res Bull* 33 (6): 663-8, 1994.
 16. Murialdo G, Galimberti CA, Fonzi S, Manni R, Costelli P, Parodi C, Solinas P, Amoretti G, Tartara A: Sex hormones and pituitary function in male epileptic patients with altered or normal sexuality. *Epilepsia* 36 (4): 36-5, 1995.
 17. Nayeri Kaman GD, Nasiri Nejad F: The possibility of hypothalamic anterior nuclei function in asymmetric control of testicular function. *Novel feats in neuroendocrinology. A stellitic symposium of the third congress of FAOPS. Nov 13-14, Xian, China. p. 33, 1994.*
 18. Sanchez MA, Lopez-Garcia JC, ME, Tapi R, Dominguez R: Asymmetrical changes in the choline acetyltransferase activity in the preoptic-anterior hypothalamic area during the oestrous cycle of the rat. *Neuroreport* 12; 5 (4): 433-4, 1994.
 19. Taneja N, Kucheria K, Jain S, Maheshwari MC: Effects of phenytoin on semen. *Epilepsia* 35 (1): 136-140, 1994.
 20. Toone B, Sexual disorders in epilepsy. In: Pedley TA, Meldrum BS, (eds), *Recent Advances in Epilepsy*. Edinburgh: Churchill Livingstone, pp. 233-259, 1986.