



Comparison of Optic Nerve Sheath Diameter (ONSD) in Low-Pressure Versus Normal Pressure Pneumoperitoneum in Laparoscopic Cholecystectomy: A Randomized Clinical Study

Sohrab Salimi¹, Behzad Nemati Honar², Ardeshtir Tajbakhsh¹, Elham Memary¹, Alireza Mirkheshti^{1*}, Mohammad Amin Elahi Najafi³

Received: 16 Aug 2021

Published: 9 May 2022

Abstract

Background: Low pressure laparoscopic cholecystectomy has been advocated due to reduction in postoperative pain, ventilation problems, hemodynamic complications, and potential for reduction in surgical events. No reported data have been found focusing on the effects of low-pressure laparoscopic cholecystectomy on intracranial pressure (ICP). The aim of this study was to investigate the effect of low-pressure laparoscopic cholecystectomy on intracranial pressure measured by optic nerve sheath diameter (ONSD) in Imam Hossein Medical Center, Tehran, Iran.

Methods: The patients classified as American Society of Anesthesiologists physical status I or II undergoing elective laparoscopic cholecystectomy due to benign gallbladder disease were randomly assigned to low-pressure laparoscopy (LPL) group or normal pressure laparoscopy group (NPL). ONSD was measured at 3 different times: (1) before induction of anesthesia; (2) after initiation of gas insufflation; and (3) after the termination of gas insufflation. The collected data were entered into SPSS software (V 24). Data were demonstrated with frequency (percentage) or mean \pm standard deviation. We used the Mann-Whitney test to compare the means of continuous variables. The Friedman test was used to compare the mean of variables over time in each of the 2 groups. The significance level in all analyses was considered at <0.05 .

Results: ONSD after the termination of gas insufflation was significantly lower in the LPL group with the mean of 4.97 ± 0.83 mm than the NPL group with the mean of 5.62 ± 1.32 mm ($p=0.018$). ONSD before induction of anesthesia or immediately after gas insufflation did not differ significantly between LPL and NPL groups. Duration of anesthesia and surgery, mean arterial pressure, the total dose of propofol ($p=0.600$), and fentanyl ($p=0.201$) did not show significant differences between the 2 groups.

Conclusion: ONSD was lower with low-pressure laparoscopic cholecystectomy after the termination of gas insufflation, which emphasized the neural protective effect of low intraperitoneal pressure. Further studies are needed to evaluate this diagnostic tool in different populations, especially in patients with increased ICP undergoing laparoscopic interventions.

Keywords: Optic Nerve Sheath Diameter, Low-Pressure, Normal Pressure, Pneumoperitoneum, Laparoscopic Cholecystectomy

Conflicts of Interest: None declared

Funding: None

***This work has been published under CC BY-NC-SA 1.0 license.**

Copyright© Iran University of Medical Sciences

Cite this article as: Salimi S, Nemati Honar B, Tajbakhsh A, Memary E, Mirkheshti A, Elahi Najafi MA. Comparison of Optic Nerve Sheath Diameter (ONSD) in Low-Pressure Versus Normal Pressure Pneumoperitoneum in Laparoscopic Cholecystectomy: A Randomized Clinical Study. *Med J Islam Repub Iran*. 2022 (9 May);36:47. <https://doi.org/10.47176/mjiri.36.47>

Introduction

Elevated intracranial pressure (ICP) is a source of complications in the perioperative period. Therefore, maintain-

ing ICP in the physiologic range could overcome some complications (1). Clinical signs and symptoms are often

Corresponding author: Dr Alireza Mirkheshti, A_mirkheshti@sbmu.ac.ir

¹ Department of Anesthesiology, Faculty of Medicine, Shahid Beheshti University of Medical Sciences, Tehran, Iran

² Department of Surgery, Faculty of Medicine, Shahid Beheshti University of Medical Sciences, Tehran, Iran

³ Oncology Research institute, Yazd Azad Medical University, Yazd, Iran

↑What is “already known” in this topic:

Low-pressure laparoscopic cholecystectomy has some advantages, such as better postoperative outcomes in comparison with normal pressure laparoscopic cholecystectomy. The effect of low-pressure laparoscopy on the intracranial pressure by measuring the optic nerve sheath diameter (ONSD) is a novel issue.

→What this article adds:

This study showed that ONSD in low-pressure laparoscopic cholecystectomy was lower than normal pressure cases, which emphasized the neural protective effect of low intraperitoneal pressure during laparoscopic cholecystectomy.

presented late and general anesthesia could mask its presentations. Noninvasive methods to monitor ICP reduce risks of complications (2). Several methods have been proposed to measure ICP. The standard method is intracranial catheter but this modality is invasive and has some contraindications, such as coagulopathy or thrombocytopenia, and needs neurosurgical expertise (3). Therefore, other noninvasive methods have been proposed, including computed tomography scan of the head, ophthalmoscopy, and transcranial doppler (3), which have some limitations for performing in the operating room.

Anatomically, the optic nerve sheath (ONS) diameter can be estimated by measuring the outer diameter of the subarachnoid space (4). Hence, elevated ICP is transmitted to optic nerve sheath, which could be measured by ultrasonography (5). The optic nerve sheath diameter (ONSD), which is measured at a fixed distance behind retina is being used to evaluate ICP in patients with traumatic brain injuries (1). This method does not have any adverse effect, but, theoretically, excessive pressure could cause orbital damage. Therefore, the examination should be as short-run as possible (1, 2, 6). In previous studies, the role of ONSD has been described as a noninvasive method to measure ICP in patients with different pathologic features (3, 7-10).

On the other hand, one of the first steps in laparoscopic cholecystectomy is to insufflate pneumoperitoneum using carbon dioxide. Traditionally this insufflation causes a pressure between 12 to 16 mmHg in peritoneum (11). The elevated intraabdominal pressure can increase the absorption of carbon dioxide and cause the respiratory acidosis. Also, the diaphragm moves upward, decreasing pulmonary compliance and increasing the airway pressure. It can compress splanchnic vasculature, causing the increased venous return. Another impact would be an increase in systemic and pulmonary vascular resistance (11). The increased intraabdominal pressure can also elevate the intracranial pressure. Intrathoracic pressure could be a mediator for the aforementioned effect (12). Animal studies showed that low abdominal pressure did not cause changes in ICP. In contrast, the standard laparoscopic pressure induces a significant increase in intracranial pressure (12).

To overcome these problems, low-pressure laparoscopic techniques are suggested as an alternative to conventional laparoscopies (11). Although these new techniques limit the cardiovascular changes, which were mentioned above, it could limit the surgeon's view of the organs (11). On the other hand, it has been proposed that the lack of sight could be overcome by deep neuromuscular blockage (13). Moreover, low-pressure laparoscopies could reduce the time of surgery, postoperative pain, and surgical complications, including herniation and adhesion formation (13, 14) that result in the better postoperative healing (13).

In this study we investigated the effect of low-pressure laparoscopic cholecystectomy on the intracranial pressure. In order to measure ICP, we used the optic disk ultrasonography technic by an expert anesthesiologist.

Methods

This randomized clinical trial was performed on 60 pa-

tients who were candidates for laparoscopic cholecystectomy under general anesthesia in Imam Hossein hospital in Tehran, Iran, from January 2019 to July 2020.

This study has been approved by the ethics committee of Shahid Beheshti University of Medical Sciences under the code of: IR.SBMU.MSP.REC.1396.97 and informed consent was taken from every patient.

Study Participants

Using the sample volume formula in comparison between the 2 groups, at 95% CI, with the test power of 80%, and taking into account the results of previous studies based on ONSD SD in the 2 groups equal to 0.03 and 0.06, respectively, and the mean difference of ONSD as 0.041, the sample size in each group was calculated as 30 people in each group (N = 60) who were selected by simple random sampling.

The inclusion criteria were age 20-60 years, ASA class I or II, and laparoscopic cholecystectomy. Patients with a history of glaucoma, corneal disease, eye surgery, cerebrovascular diseases, any type of neurological diseases, chronic kidney diseases, and cirrhosis with ascites were excluded from the study. Patients should not have allergy to any medication used for standard general anesthesia or the current use of analgesics or psychoactive drugs. Also, patients without any neurologic or ophthalmic disease were included in this study. The exclusion criteria were the time of surgery more than 2 hours or the change in the surgical plan to open cholecystectomy (Fig. 1).

Study Protocol

After obtaining the code of ethics from the ethics committee of Shahid Beheshti University of Medical Sciences, Tehran, Iran, and obtaining written consent from eligible patients, they were divided into 2 groups of low-pressure laparoscopy (LPL) and normal-pressure laparoscopy (NPL) pressure using the computer-generated random number technique. All patients had general anesthesia under the volume control mode as the tidal volume was adjusted 6-8cc/kg, respiratory rate = 11-12/min, I/E: 1/2, and peak pressure = 30 CmH₂O. Moreover, the end tidal co2 was maintained between 25 to 30 CmH₂O.

All the monitors that displayed the information of intra-abdominal pressure were covered for the anesthesiologist, surgeons, and the research physician before arrival at the operating room. The surgery nurse installed the pneumoperitoneum insufflation pressure at 6 to 8 mmHg (LPL) or 12 to 14 mmHg (NPL).

Ocular ultrasounds were performed using the Sonosite S-Nerve (SonoSite Inc) machine with a 5-10 MHz linear probe. An expert anesthesiologist who had been trained by a radiologist for performing ocular ultrasound exams and was unaware of the intraperitoneal gas pressure performed all scans in supine position. These scans were conducted on a closed eyelid using a plentiful amount of conductive gel. To get an axial cross-sectional image of the optic nerve entering the fundus, a linear probe was applied. The technician positioned the globe superiorly and inferiorly to make it easier to examine the nerve's margins. The ONSD was measured 3 times for every eye and the mean of 6

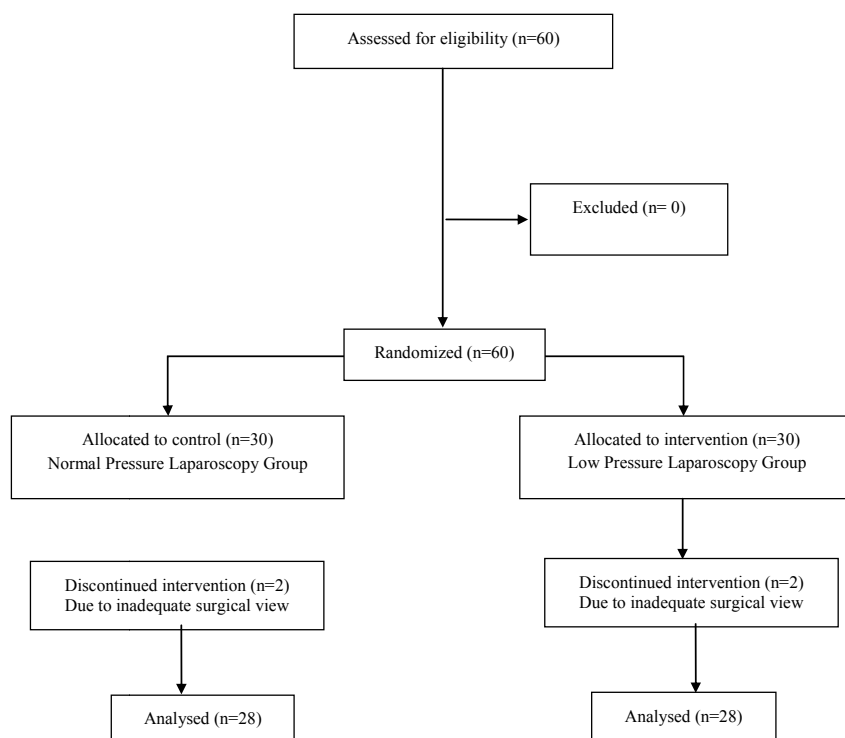


Fig. 1. CONSORT flowchart

measurements was documented. The patients were warned to avoid artifacts so they could look straightly ahead and ensure that the visual axis was centered with the optic nerve perpendicular to the fundus, as the only images with centered optic nerve and clear optic sheath margins were acceptable. This measurement was performed in 3 different time points. The first was measured while the patient entered the operating room and before prescribing pre-medication. The second was measured 1 minute after the initiation of gas insufflation for laparoscopy. The third was measured 1 minute after the termination of gas insufflation.

All surgical procedures were performed under general anesthesia with full monitoring in place (ECG, NIBP, Pulse oximetry, Capnography, BIS) by midazolam 1 mg, Fentanyl 2 μ g/kg, lidocaine 40 mg, propofol 2 mg/kg, and atracurium 0.6 mg/kg. General anesthesia was maintained by propofol 150 μ g/kg/min, atracurium 0.15 mg/kg every half an hour and fentanyl 1 μ g/kg every 30 minutes. Propofol infusion was titrated for maintaining the BIS between 40 and 60. Hemodynamic parameters (mean arterial pressure [MAP] and heart rate [HR]) were recorded every 5 min. The total dose of propofol as maintenance medication was documented. Ventilator set up was the same in both groups. Pain management was done by patient-controlled analgesia with morphine sulfate (bolus 1 mg, lock-out 6 minutes) and acetaminophen (total 3000 mg daily), which was installed and maintained by acute pain service of our organization.

The head of the study team who was an anesthesiology faculty member generated the random allocation sequence and assigned participants to interventions. All participants

were enrolled in our study by a fixed anesthesiology resident who was working in the operating room. All patients and the other anesthesiologist who measured the ONSD were unaware of the intraperitoneal gas pressure. The dose of anesthetics and analgesics were adjusted by the third anesthesiologist according to the BIS score and the hemodynamic parameters. The PONV were assessed in postanesthesia care unit by a fixed trained anesthesiology resident who did not have any information about the procedure.

Statistical Analysis

Finally, the collected data were entered into SPSS software (V 24). Data were demonstrated using frequency (percentage) or mean \pm SD, as inferential statistics, respectively. The chi square test was used to compare frequency distribution of sex between the 2 groups. To compare the mean of age, weight, body mass index (BMI), duration of surgery, systolic blood pressure (SBP), diastolic blood pressure (DBP), and mean blood pressure (MAP) between the 2 groups, an independent t test was used. Also, according to the results of the Shapiro-Wilk test, indicating a nonnormal distribution of variables, we used the Mann-Whitney test to compare the means of continuous variables between the 2 groups. The Friedman test was used to compare the mean of variables over time in each of the 2 groups. Significance level in all analyses was considered as < 0.05 .

Results

In the present study, from 28 patients in the LPL group, there were 16 women (57.1%) and 12 men (42.9%), with a

<http://mjiri.iums.ac.ir>

Med J Islam Repub Iran. 2022 (9 May); 36:47.

mean age of 49.32 ± 10.2 years; and from 28 patients in the NPL group there were 15 women (53.6%) and 13 men, with a mean age of 50.67 ± 12.1 years. In addition, there was no significant difference between the 2 groups in terms of age ($p=0.653$), sex ($p=0.718$), weight ($p=0.422$), BMI ($p=0.254$), systolic blood pressure ($p=0.074$), diastolic ($p=0.212$), mean arterial ($p=0.060$), and duration of surgery ($p=0.668$) (Table 1).

The ONSD did not differ between the 2 groups before induction and immediately (1 min) after gas insufflation ($p=0.148$ and 0.071 , respectively). However, this parameter in the NPL group was significantly higher than that in the LPL group (LPL group: 4.97 ± 0.83 vs NPL group: 5.62 ± 1.32 ; $p=0.018$). On the other hand, according to the Friedman test, the increase in ONSD during the intervention was not significant in each of the groups ($p>0.05$) (Table 2).

The total dose of propofol ($p=0.600$) and fentanyl ($p=0.201$) as maintenance drugs did not have significant difference between the 2 groups as illustrated by Table 3.

Discussion

The present study revealed that low-pressure laparoscopic cholecystectomy prevented the rise of ONSD at the end of gas insufflation. As described earlier, the ONSD is directly related to the ICP. Therefore, we can theorize that ICP may increase in laparoscopic procedures using intra-abdominal pressure of 12 mmHg or more. As the mean duration of surgery (from the gas insufflation until gas desufflation) was around 30 minutes, this effect needed

time to take effect. This is inconsistent with our finding that immediately after gas insufflation the ONSD did not differ between and within the 2 groups.

Laparoscopy has been introduced as a mean to decrease surgical stress responses in patients, hence, this approach could have its own complications. Elevated ICP due to increased intra-abdominal pressure may end to cerebral edema by creating temporary neurological dysfunction that patients often experience at the emergence time from prolonged laparoscopic operations, particularly those cases who require long periods of Trendelenburg position. (15) These types of complications had not been seen with conventional open cholecystectomy. Therefore, to investigate this theory, we enrolled patients with ASA class I and II undergoing laparoscopic cholecystectomy to investigate its effect on ICP.

Low-pressure laparoscopic intervention has been reviewed to decrease surgery time, postoperative pain, ventilation and hemodynamic problems, and improving postoperative healing (13). However, to the best of our knowledge, its effect on ICP and cerebral perfusion pressure (CPP) has not been completely studied yet. It could be theorized that laparoscopic intervention increases ICP with a Valsalva-like phenomenon, which cause engorgement of cerebral vasculature. This effect would cause deterioration of CPP in high-risk patients, and therefore may create cerebral ischemia (16). Kamine et al investigated that intracranial pressure significantly increases during abdominal insufflation and this effect correlates with laparoscopic insufflation pressure. They concluded that maxi-

Table 1. Demographic and Clinical Characteristics of the Study Patients

Characteristics	LPL Group (n = 28)	NPL Group (n = 28)	P Value
Age (y)	49.32 ± 10.2	50.67 ± 12.1	0.653 ^{††}
Sex			
Female	16 (57.1)	15 (53.6)	
Male	12 (42.9)	13 (46.4)	0.718 [†]
Weight, kg	63.2 ± 9.6	65.1 ± 7.9	0.422 ^{††}
BMI, kg/m ²	23.03 ± 4.10	24.33 ± 4.33	0.254 ^{††}
Duration of surgery, min	32.5 ± 8.2	31.6 ± 7.4	0.668 ^{††}
SBP, mmHg	129.25 ± 35.12	126.36 ± 30.31	0.074 ^{††}
DBP, mmHg	82.32 ± 5.25	84.11 ± 5.36	0.212 ^{††}
MAP, mmHg	101.40 ± 6.36	104.70 ± 6.51	0.060 ^{††}

Data presented as mean \pm SD or NO (%).

[†] Used a chi square test.

^{††} Used an independent sample t test.

Table 2. ONSD Measurement

ONSD, mm	LPL Group	NPL Group	P Value [†]
Before induction	4.91 ± 0.42 (4.5-5.00)	5.10 ± 0.66 (4.7-5.05)	0.148
1 minute after gas insufflation	4.92 ± 0.50 (4.6-5.08)	5.20 ± 0.71 (4.7-5.00)	0.071
After gas termination	4.97 ± 0.83 (4.6-5.10)	5.62 ± 1.32 (4.8-5.15)	0.018
P value ^{††}	0.148	0.791	

Data are shown as mean \pm SD and median (IQR).

[†] Used the Mann-Whitney test.

^{††} Used the Friedman test.

Table 3. Differences in Maintenance Drugs

Variables	LPL Group	NPL Group	P Value [†]
Total Propofol Dosage, mg	193.92 ± 31.13	198.54 ± 37.91	0.600
Total Fentanyl Dosage, μ g	205.34 ± 31.43	225.00 ± 85.54	0.201

Data are shown as mean \pm SD.

[†] Used of Mann-Whitney test.

mum ICP measured was a potentially dangerous 25 CmH₂O. Laparoscopy should be applied cautiously in the patients by a baseline rise of ICP or head trauma (16). We believed that by using low-pressure laparoscopic procedure we could decrease the effect of intra-abdominal pressure on ICP.

In their study, Ilhan et al measured intraocular pressure binocularly in patients under laparoscopic procedures at 3 different times of pre, intra, and postoperation using a contact tonometer. They determined that when intra-abdominal pressure was ≥ 12 mmHg, it was increased, and that intraocular pressure measurement could be a suitable methodology for estimating intra-abdominal pressure (17). Our study was similar to Eun et al study, as we focused on ocular parameters in laparoscopic procedures but the difference was that we assessed the nerve sheath diameter as an indicator of the intracranial pressure and they measured the ocular pressure as an indicator of intra-abdominal pressure. The role of the ONSD measurement in the rise of ICP during laparoscopic procedures have been emphasized in some studies (18-20), however, to the best of our knowledge, our study on the low-pressure versus normal pressure pneumoperitoneum in the laparoscopic surgeries is a novel survey, which has not been assessed yet.

One of the limitations of our study was small sample size and data distribution was not normal. However, given this point, these results may not be generalizable to the community, however, there is a need for further studies with a larger sample size. However, pneumoperitoneum is also undesirable in patients with increased ICP (tumor, hydrocephalus, and head trauma), hypovolemia, ventriculo-peritoneal shunts, and peritoneogenetic shunt. Therefore, increasing the sample size in these studies is very difficult. Presenting the results of this study at a smaller level may encourage researchers to perform a similar study in a larger sample size in the future.

Finally, we propose that additional studies be conducted to determine the effect of time and position on the ONSD in patients undergoing protracted laparoscopic procedures with low and standard pneumoperitoneum pressures, particularly in the steep Trendelenburg position. Such investigations can help to decrease the probable intra- and post-operative complications caused by the rise of ICP in laparoscopic procedures and improve patient safety during these types of operations.

Conclusion

Based on the relationship between ONSD and intracranial pressure, we speculate that using low pneumoperitoneal pressure during laparoscopic procedures will reduce the likelihood of ICP rise and, as a result, the risk of related complications will be lower than with standard pneumoperitoneal laparoscopic procedures. However, additional research is needed in the future.

Acknowledgment

The authors thank the residents and anesthesia technicians for their assistance in all aspects of the study.

ETHICAL APPROVAL: This study was approved by

the ethics committee of Shahid Beheshti University of Medical Sciences under the code of: IR.SBMU.MSP.REC.1396.97.

Conflict of Interests

The authors declare that they have no competing interests.

References

1. Chacko J. Optic nerve sheath diameter: An ultrasonographic window to view raised intracranial pressure? *Indian J Crit Care Med.* 2014;18(11):707-8.
2. Helmke K, Hansen HC. Fundamentals of transorbital sonographic evaluation of optic nerve sheath expansion under intracranial hypertension II. Patient study. *Pediatr Radiol.* 1996;26(10):706-10.
3. Soldatos T, Karakitsos D, Chatzimichail K, Papathanasiou M, Goulamos A, Karabinis A. Optic nerve sonography in the diagnostic evaluation of adult brain injury. *Crit Care.* 2008;12(3):R67.
4. Hansen HC, Helmke K. Validation of the optic nerve sheath response to changing cerebrospinal fluid pressure: ultrasound findings during intrathecal infusion tests. *J Neurosurg.* 1997;87(1):34-40.
5. Lochner P, Brio F, Zedde ML, Sanguigni S, Coppo L, Nardone R, et al. Feasibility and usefulness of ultrasonography in idiopathic intracranial hypertension or secondary intracranial hypertension. *BMC Neurol.* 2016;16:85.
6. Barnett SB, Ter Haar GR, Ziskin MC, Rott HD, Duck FA, Maeda K. International recommendations and guidelines for the safe use of diagnostic ultrasound in medicine. *Ultrasound Med Biol.* 2000;26(3):355-66.
7. Frumin E, Schlang J, Wiechmann W, Hata S, Rosen S, Anderson C, et al. Prospective analysis of single operator sonographic optic nerve sheath diameter measurement for diagnosis of elevated intracranial pressure. *West J Emerg Med.* 2014;15(2):217-20.
8. Girisgin AS, Kalkan E, Kocak S, Cander B, Gul M, Semiz M. The role of optic nerve ultrasonography in the diagnosis of elevated intracranial pressure. *Emerg Med J.* 2007;24(4):251-4.
9. Hansen HC, Lagreze W, Krueger O, Helmke K. Dependence of the optic nerve sheath diameter on acutely applied subarachnoidal pressure - an experimental ultrasound study. *Acta Ophthalmol.* 2011;89(6):e528-32.
10. Tamburrelli C, Salgarello T, Caputo CG, Giudiceandrea A, Scullica L. Ultrasonographic evaluation of optic disc swelling: comparison with CSLO in idiopathic intracranial hypertension. *Investig Ophthalmol Vis Sci.* 2000;41(10):2960-6.
11. Gurusamy KS, Vaughan J, Davidson BR. Low pressure versus standard pressure pneumoperitoneum in laparoscopic cholecystectomy. *Cochrane Database Syst Rev.* 2014(3):CD006930.
12. Rosin D, Brasesco O, Varela J, Saber AA, You S, Rosenthal RJ, et al. Low-pressure laparoscopy may ameliorate intracranial hypertension and renal hypoperfusion. *J Laparoendosc Adv Surg Tech A.* 2002;12(1):15-9.
13. Istre O. Intra-Abdominal Space at Different Pressures and Level of Block, Consequences and Benefit of Low Pressure During Laparoscopy. *J Minim Invasive Gynecol.* 2015;22(6S):S108.
14. Sarli L, Costi R, Sansebastiano G, Trivelli M, Roncoroni L. Prospective randomized trial of low-pressure pneumoperitoneum for reduction of shoulder-tip pain following laparoscopy. *Br J Surg.* 2000;87(9):1161-5.
15. Paul Hayden SC. Anaesthesia for laparoscopic surgery. *BJA Educ.* 2011;11(5):177-80.
16. Kamine TH, Papavassiliou E, Schneider BE. Effect of abdominal insufflation for laparoscopy on intracranial pressure. *JAMA Surg.* 2014;149(4):380-2.
17. Ece I, Vatansev C, Kucukkartallar T, Tekin A, Kartal A, Okka M. The increase of intra-abdominal pressure can affect intraocular pressure. *BioMed Res Int.* 2015;2015:986895.
18. Eun Jung Kim, Bon-Nyeo Koo, Seung Ho Choi, Kyoungun Park, Min-Soo Kim. Ultrasonographic optic nerve sheath diameter for predicting elevated intracranial pressure during laparoscopic surgery: a systematic review and meta-analysis. *Surg Endos.* 2018 Jan;32(1):175-182.
19. Maddalena De Bernardo, Livio Vitiello, Nicola Rosa. *Ultrasound*

- optic nerve sheath diameter evaluation in patients undergoing robot assisted laparoscopic pelvic surgery. *J Robot Surg.* 2019;13:709–710.
20. Geng W, Chen Ch, Sun X, Huang Sh. *BMC Anesthesiol.* 2021;21(1):30.