Medical Journal of the
Islamic Republic of Iran

Volume 15
Number 3
Fall 1380
November 2001

Original Articles

INJECTION OF BOTULINUM TOXIN IN THE TREATMENT OF ACHALASIA: A RANDOMIZED, DOUBLE BLIND, CONTROLLED CLINICAL TRIAL

H. FOROOTAN PISHBIJARI, M.D., S.A. MORTAZAVI TABATABAEI, M.D., AND M. JANGODAZ, M.D.

From the Gastrointestinal Endoscopy Department, Imam Khomeini Hospital, Tehran University of Medical Sciences, Tehran, I.R. Iran.

ABSTRACT

Our aim was to evaluate the short and long term efficacy of botulinum toxin therapy in Iranian patients with achalasia.

In a randomized, double blind trial, 20 patients with achalasia, referring to Imam Khomeini Hospital, received either 80 units of botulinum toxin (BT) or placebo (PL) from 1995 to 1998. Two weeks later, the response to treatment was assessed on the basis of changes in the symptom score (measured on a scale from 0 to 9). Patients who received PL initially were subsequently treated with BT. After two weeks and six months, assessment was repeated.

Two weeks after treatment, clinical evaluation revealed that in the BT group all clinical symptoms were improved and the total symptom score had significantly decreased from 6.2±1.4 to 1.9±1.66 ($p<0.05$) and no significant changes were seen in the clinical score of the PL group. No significant differences were seen in the BT group comparing thoracic pain after the first two weeks. Two weeks after the first injection, patients who did not show clinical improvement received toxin with the same previous dose and re-evaluation was performed two weeks after the second injection and six months after the first injection.

After six months mean symptom score was 3.4±1.9 ($p<0.005$) in the BT group and 2.4±1.51 ($p<0.005$) in the PL group. At this time clinical responses persisted in 12 patients (60%).

In conclusion, injection of botulinum toxin into the lower esophageal sphincter is an effective, safe and simple method of treatment for achalasia, especially in patients who cannot use other methods.

MJIRI, Vol. 15, No. 3, 123-127, 2001.

Keywords: Achalasia, botulinum toxin, Treatment, Clinical response.

Correspondence: H. Forootan Pishbijari, Associate Professor of Gastroenterology, Tehran University of Medical Sciences, GI Endoscopy Section, Imam Khomeini Hospital, Keshavarz Blvd., Tehran, Iran.

INTRODUCTION

Achalasia, one of the most prevalent esophageal mo-

[Downloaded from mjiri.iums.ac.ir on 2026-11-23]

tor disorders, was described by Thomas Willis in 1672 for the first time.[1] Three treatment methods for achalasia were available until 1995: myotomy of the inferior esophageal sphincter, balloon dilatation, and botulinum toxin. The aim of these treatment methods is to lower the resting lower esophageal sphincter pressure.[2,3]

Treatment with oral medications has had limited results but balloon dilatation and myotomy have had valuable results of about 60 to 95 percent and are currently the standard methods of treatment. Despite the usefulness of these therapeutic methods, both have complications including esophageal perforation in 2-5%,[4] repeated dilatations and reflux after myotomy.

Botulinum toxin has been so far recognized as an inhibitor of neuronal impulse transfer to skeletal muscles by blocking acetylcholine release from the end of nerves.[5,6] Today local injection of botulinum toxin is used as a treatment for local hyperactivity,[5,7,8] skeletal muscle spasm such as strabismus and different types of dystonia. The result of these treatments is good without any serious side effects.[9] The role of botulinum toxin in reducing the tone of the lower esophageal sphincter has been shown clearly in piglets.[10]

Recently, Pasricha and his colleagues have used direct injection of botulinum toxin for treatment of this disease and reported a response of about 90% in the first stage and 66% on long term.[11,12]

It seems that age and type of disease are important anticipatory factors for determining response to treatment, in a manner that, response to toxin in patients older than fifty suffering from severe achalasia is less than patients under fifty years old and those having the classic type of achalasia.[13]

Regarding convenience, lower risk and the outpatient treatment setting of this method, we studied the efficacy of this method on Iranian patients.

MATERIAL AND METHODS

In a double blind randomized placebo controlled clinical trial, patients older than 18 years suffering from achalasia were studied to investigate the therapeutic effects of botulinum toxin injection. Patients having a history of gastroesophageal reflux, history of gastrointestinal ulcers such as esophageal ulcer, Barrett esophagus, serious cardiopulmonary diseases and secondary achalasia such as esophageal cancer were excluded from the study.

Since we could not perform esophageal manometry in this center, diagnosis of disease was made according to clinical, radiologic and endoscopic criteria of achalasia.

After receiving written consent, patients were randomly allocated into two treatment groups, one receiving injection of botulinum toxin (BT) and the other receiving injection of placebo (PL).

Before starting treatment, a researcher, who was not aware of the patients' groups, recorded clinical data such as clinical symptoms, time of onset of symptoms and weight loss.

The symptomatic response was evaluated on the basis of a modified symptom score of Eckardt et al,[2] which was the sum of the individual scores for the three cardinal symptoms of achalasia (Table I). In the BT group, 80 units (4 cc) of botulinum toxin (Dysport, England) was injected by a 5 mL sclerotherapy needle in four separate points in the inferior esophageal sphincter, and in the placebo group the same quantity of normal saline was injected with the same method during endoscopy.

After injection patients were under close observation for vital signs, pulmonary insufficiency and other complications for at least 6 hours. Patients were visited after two weeks for clinical evaluation. Response to treatment was defined as a 50% decrease in their basic clinical scores. The PL group and those who did not respond to treatment were treated again with 80 units of toxin with the same method described above. If no response was observed after two weeks, treatment was terminated and all patients were evaluated six months after the first injection (Fig. 1).

Data analysis was accomplished with SPSS for windows software, Release 9, using Wilcoxon signed-rank & Mann-Whitney two-sample tests.

Table I. Clinical scoring of patients according to clinical symptoms (From Eckardt et al.).[2]

Frequency / Symptoms	None	Some days	Daily	At each meal
Dysphagia	0	1	2	3
Regurgitation	0	1	2	3
Chest Pain	0	1	2	3

[Downloaded from mjiri.iums.ac.ir on 2026-11-23]

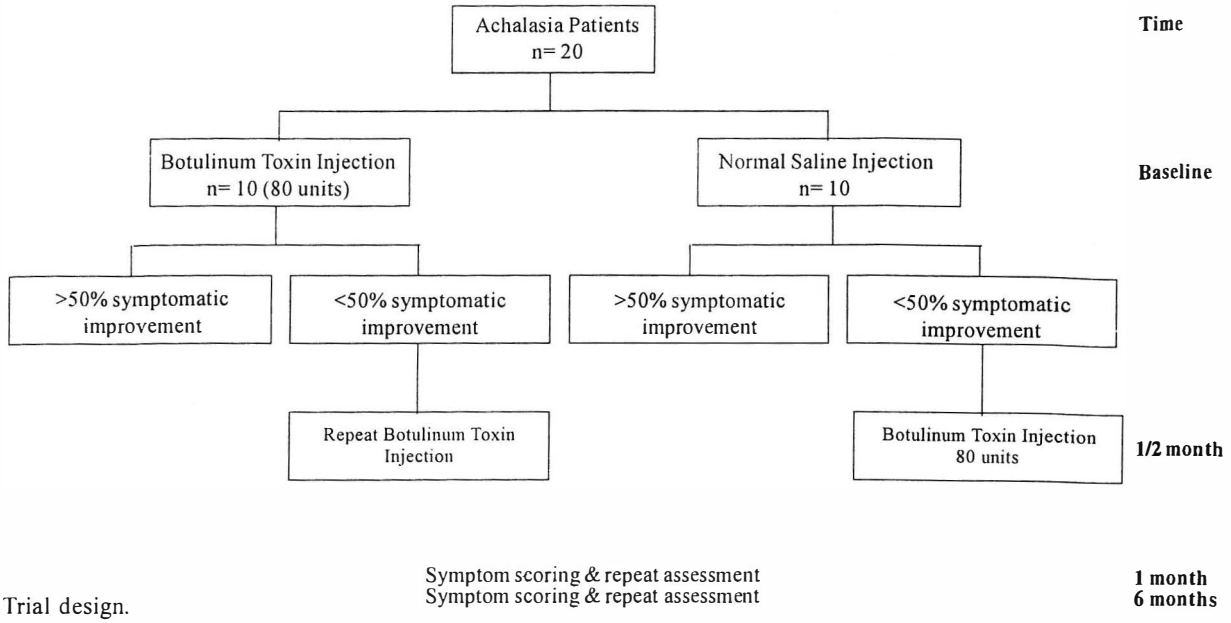

Fig. 1. Trial design.

RESULTS

Twenty patients, 9 men and 11 women aged 35.5±15.76 years (mean±SD) entered the study. Mean duration of symptoms was 3.35±2.69 and 3.05±1.67 years for groups BT and PL, respectively. Weight loss of patients in both groups varied from 2 to 25 kg. Total clinical scores including the scores of three symptoms: dysphagia, regurgitation and thoracic pain were 6.2±1.4 and 6.1±0.88 in groups BT & PL respectively.

Two weeks after injection of toxin in the BT group, 8 patients out of 10 responded clinically. In the PL group, no patient showed a clinical response. In the BT group dysphagia was relieved in 90% of patients, regurgitation in 80%, and thoracic pain in 57%, and 80% of patients were treated regarding total clinical scores. In the placebo group no improvement in clinical symptoms was seen except in thoracic pain that was relieved in 10% of patients. Table II illustrates a comparison of the results in the two groups, two weeks after the first injection of botulinum toxin.

At this stage, the two patients in the BT group who had not responded to therapy and all patients in the PL group received botulinum toxin injection, and all patients were evaluated two weeks after this treatment. The clinical response persisted in 7 patients in the BT group while one patient showed relapse of symptoms. The two non-responders in the BT group still did not respond to the second injection and showed no clinical response. In the PL group, acceptable symptomatic relief was observed

Table II. Comparison of clinical symptom average in BT & PL groups at baseline and two weeks after injection.

Treatment Groups / Symptoms	BT Group Baseline	PL Group Baseline	BT Group 2 weeks after injection	PL Group 2 weeks after injection	p value*
Dysphagia	3±0	2.9±0.32	0.7±0.67	2.9±0.32	0.0001
Regurgitation	2.2±0.79	1.9±0.74	0.7±0.82	1.9±0.74	0.0002
Chest Pain	1±0.94	1.3±0.48	0.5±0.71	1.2±0.42	0.12
Total Symptom Scoring	6.2±1.4	6.1±0.88	1.9±1.66	6±1.44	0.0001

*: P values are for comparison between BT & PL groups two weeks after injection.

[Downloaded from mjiri.iums.ac.ir on 2026-11-23]

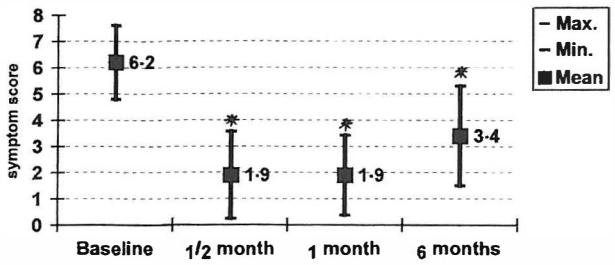

Fig. 2. The mean±SD of symptom scores at baseline, 1/2 month, 1 month and 6 months after injection of botulinum toxin in the BT group. P values are for comparisons with baseline values (*: p= 0.005).

in 8 patients two weeks after their botulinum toxin injection.

The mean symptom score at 6 months between the BT and PL group was 3.4±1.9 (Fig. 2) and 2.4±1.51, respectively, which is remarkably lower than their baseline scores for both groups (p value= 0.0051).

Fig. 2 shows the global symptom score of the BT group at baseline and at 1/2, 1 and 6 months after treatment.

By six months, 12 patients were still in remission.

No significant statistical differences were seen in comparing the mean score of each clinical symptom and the total symptom score with sex and age of patients at 1/2, 1 and 6 months after treatment.

DISCUSSION

According to the results achieved, the mean score of all symptoms, as well as the total clinical score of patients receiving botulinum toxin injection, showed remarkable reduction after two weeks compared to scores before injection and also to the placebo group; so that actually, no clinical response was seen in the placebo group and this shows the effects of botulinum toxin in elimination of clinical symptoms in achalasia patients. Some decrease in mean score of thoracic pain was seen, but the difference was not statistically significant in the BT group.

Relapse of symptoms after six months is evident, and clinical score and symptoms showed a direct relationship with duration of follow up, in a manner that the clinical score and symptoms increased gradually after injection. After six months, 60% of patients had an acceptable clinical response. Clinical response has been between 50-70% in similar studies.[14-17]

Relapse is expected to increase one year after injection, and as confirmed by some previous researches, has the same manner as in other musculoskeletal disorders.[20]

The relationship between therapeutic response and patient age is controversial; some reports show better therapeutic responses in patients aged over fifty years,[12,21] while others show no relationship.[14,22] In our study, although the number of patients in this age group was three, no significant relationship was seen between age of patients and their therapeutic response. Previous studies on therapeutic effects of botulinum toxin in the treatment of achalasia have not proved that lack of response in some patients is because of resistance to botulinum toxin[9] or individual factors of patients. Recent studies have mentioned better long-term results of pneumatic dilatation compared to botulinum toxin.[18,23]

In conclusion, the role of botulinum toxin in treating achalasia needs more extensive research but our study proved that botulinum toxin injection is an effective method in the treatment of achalasia with a low risk, particularly in patients who cannot use other methods.

REFERENCES

1. Rodriguez Cruz E, Sheehan C, Fraiberg E, Hasan S: Botulinum toxin A for the treatment of achalasia. Bol Asoc Med PR 89: 57-9, 1997.
2. Eckardt VF, Aignherr C, Bernhard G: Predictors of outcome in patients with achalasia treated with pneumatic dilation. Gastroenterology 103: 1732-8, 1992.
3. Csendes A, Braghetto I, Burdiles P, Csendes P: Late results of a prospective randomized trial comparing forceful dilation and esophagomyotomy in patients with achalasia. Gut 79: 144-154, 1989.
4. Katz PO, Richter JE, Cowan R, Castell DO: Apparent complete lower esophageal sphincter relaxation in achalasia. Gastroenterology 90: 978, 1986.
5. Schantz EJ, Jonnson EA: Properties and use of botulinum toxins and other microbial neurotoxin in medicine. Microbiol Rev 56: 80-99, 1992.
6. Pamphlett R: Early terminal and nodal sprouting of motor axons after botulinum toxin. J Neuronal Sci 92: 181-192, 1989.
7. MacKenzie I, Burnstock G, Dolly JO: The effects of purified botulinum neurotoxin type A on cholinergic and non-adrenergic atropine-resistant autonomic neurovascular transmissions. Neuroscience 7: 997-1006, 1982.
8. Paul MI, Cook MA: Lack of effect of botulinum toxin on non-adrenergic, non-cholinergic inhibitory response of guinea pig fundus *in vitro*. Can J Physical Pharmacol 58: 88-92, 1980.
9. Jankovic J, Brin MF: Therapeutic uses of botulinum toxin. N Engl J Med 324: 1186-94, 1991.
10. Pasricha PJ, Ravich WJ, Kaloo AN: Effects of intrasphincteric botulinum toxin on the lower esophageal

[Downloaded from mjiri.iums.ac.ir on 2026-11-23]

sphincter in piglets. Gastroenterology 105: 1045-9, 1993.
11. Pasricha PJ, Rai R, Ravich WJ, et al: Treatment of achalasia with intrasphincteric injection of Botulinum toxin. Ann Int Med 121: 590-591, 1994.
12. Pasricha PJ, Ravich WJ, Hendrix TR, et al: Intrasphincteric Botulinum toxin for the treatment of achalasia. N Engl J Med 332: 774-8, 1995.
13. Pasricha PJ, Rai R, Ravich WJ, et al: Botulinum toxin for achalasia: long term outcome and predictors of response. Gastroenterology 110: 1410-15, 1996.
14. Kolbasnik J, Waterfall WE, Fachnie B, et al: Long-term efficacy of botulinum toxin in classical achalasia: a prospective study. Am J Gastroenterol 12: 3434-9, 1999.
15. Schiano TD, Parkman HP, Miller LS, et al: Use of botulinum toxin in the treatment of achalasia. Dig Dis 16: 14-22, 1998.
16. Cuilliere C, Ducrotte P, Zerbib F, et al: Achalasia: outcome of patients treated with intrasphincteric injection of botulinum toxin. Gut 41: 87-92, 1997.
17. Greaves RR, Mulcahy HE, Patchett SE, et al: Early experience with intrasphincteric botulinum toxin in the treatment of achalasia. Aliment Pharmacol Ther 13: 1221-5, 1999.
18. Prakash C, Freedland KE, Chan MF, Clouse RE: Botulinum toxin injections for achalasia symptoms can approximate the short term efficacy of a single pneumatic dilation: a survival analysis approach. Am J Gastroenterol 94: 328-33, 1999.
19. Vaezi MF, Richter JE, Wilcox CM, et al: Botulinum toxin versus pneumatic dilation in the treatment of achalasia: a randomized trial. Gut 44: 231-9, 1999.
20. Jankovic J, Schwartz KS: Clinical correlates to response to botulinum toxin injections. Arch Neurol 48: 1253-6, 1991.
21. Annese V, Bassotti G, Coccia G, et al: Comparison of two different formulations of botulinum toxin A for the treatment of esophageal achalasia. Aliment Pharmacol Ther 13: 1374-50, 1999.
22. Fishman VM, Parkman HP, Schiano TD, et al: Symptomatic improvement in achalasia after botulinum toxin injection of the lower esophageal sphincter. Am J Gastroenterol 91: 1724-1730, 1996.
23. Muehldorfer SM, Schneider TH, Hochberger J, et al: Esophageal achalasia: intrasphincteric injection of botulinum toxin A versus balloon dilation. Endoscopy 31: 517-21, 1999.

[Downloaded from mjiri.iums.ac.ir on 2026-11-23]

[Downloaded from mjiri.iums.ac.ir on 2026-11-23]