Original Article
http://mjiri.iums.ac.ir
Medical Journal of the Islamic Republic of Iran (MJIRI)

Med J Islam Repub Iran. 2022 (18 May);36.51. https://doi.org/10.47176/mjiri.36.51

Calcaneostop Provides Favorable Short-term Outcomes in Patients With Flexible Flatfoot

Alireza Ghaznavi[1], Seyed Mani Mahdavi[1], Mehdi Moghtadaei[1], Seyed Nima Taheri[1], Ali Yeganeh[1], Amer Karimpour[1], Mohammad Soleimani[2]*

Received: 4 Nov 2021 Published: 18 May 2022

Abstract

Background: Flatfoot is a relatively frequent deformity seen in almost 5% of children. It is classified into flexible and rigid flatfoot. Symptomatic flexible flatfoot (FFF) can be managed using several procedures, and calcaneostop is one of the procedures that has gained popularity recently. This study aimed to evaluate the outcome of the calcaneostop procedure using screws.

Methods: We retrospectively evaluated 57 feet in 44 consecutive patients with FFF undergoing calcaneostop surgery. The same pediatric orthopedic surgeon performed all surgeries. Following a 10-mm incision on the sinus tarsi, a partial thread 6.5 cancellous screw size 40 was inserted. Achilles tendon lengthening was performed on all patients, and a short leg cast was applied. Pain relief, complications, and the change in the talocalcaneal (Kite), talometatarsal (Meary's), and calcaneal inclination (Pitch) angles were evaluated on plain radiographs using a paired t test.

Results: Pain relief was achieved in 55 (96.5%) cases, and 2 (3.5%) patients experienced pain after surgery. Other complications, including nerve damage, infection, screw loosening, fracture, or position loss, were not observed. The mean preoperative and postoperative Meary's, Kite, and Pitch angles were 15.74 ± 2.02 (12.30-21.60), 8.72 ± 1.03 (7.20-10.60), 31.23 ± 1.97 (27.80-37.30), 21.30 ± 1.98 (18.50-24.60), 12.40 ± 1.64 (8.50-16.60), and 18.52 ± 1.97 (15.90-22.60), respectively. A significant improvement was observed in each angle following surgery ($p<0.001$).

Conclusion: Calcaneostop is an inexpensive and simple procedure that avoids the involvement of several joints and uses a simple incision leaving a small scar. This procedure is remarkably successful and can be quite convenient.

Keywords: Flatfoot, Subtalar Joint, Calcaneus, Tendon Lengthening

Conflicts of Interest: None declared
Funding: None

***This work has been published under CC BY-NC-SA 1.0 license.**
Copyright© Iran University of Medical Sciences

Cite this article as: Ghaznavi A, Mahdavi SM, Moghtadaei M, Taheri SN, Yeganeh A, Karimpour A, Soleimani M. Calcaneostop Provides Favorable Short-term Outcomes in Patients With Flexible Flatfoot. *Med J Islam Repub Iran.* 2022 (18 May);36:51. https://doi.org/10.47176/mjiri.36.51

Introduction

Flatfoot or pes planus is defined as the flattening of the medial longitudinal arch and is a rather frequent deformity in infants and children (1, 2). Flatfoot is classified into rigid flatfoot and flexible flatfoot (FFF). Nearly 5% of all children are diagnosed with FFF, and it is usually asymptomatic; however, fatigue and pain are also possible symptoms (1, 3-7). The morphological characteristics include subtalar joint eversion, flattening of the medial longitudinal arch, calcaneus valgus, and forefoot abduction in weight-bearing, while the medial arch is normal when the

Corresponding author: Dr Mohammad Soleimani, soleymani.mo@iums.ac.ir

1. Department of Orthopedic Surgery, Rasoul-e-Akram Hospital, Iran University of Medical Sciences, Tehran, Iran
2. Department of Epidemiology, School of Public Health, Iran University of Medical Sciences, Tehran, Iran

↑What is "already known" in this topic:
Flatfoot is a prevalent disease, and calcaneostop, among other treatments, has been suggested to treat it, with promising results. Calcaneostop is a simpler procedure for both the patient and the surgeon.

→What this article adds:
Calcaneostop is a relatively new procedure, and the number of studies reporting its results is limited, especially in the Iranian population. Our results suggest excellent outcomes and negligible complications following calcaneostop.

foot is not weight-bearing (1, 8, 9). Furthermore, the condition can lead to Achilles tendon shortening (10).

If left untreated, flatfoot can result in multiple complications such as hallux valgus, arthritis, posterior tibial tendon dysfunction, persistent pain in the medial longitudinal arch, metatarsalgia, and knee and low back pain (11, 12). Conservative or operative treatment is available for FFF. Generally, conservative treatment is the primary treatment, and operative treatment is reserved for patients for whom conservative treatment has failed or for symptomatic patients (13-15). Surgical operations can be categorized into 3 main groups: arthrodesis, reconstruction, and arthroereisis. Arthroereisis have become the primary procedure in the past few decades, and while there are questions about the long-term outcome of reconstructions, arthrodesis remains the option for failed primary operations (13, 16-19).

Arthroereisis is a minimally invasive procedure that restricts subtalar joint pronation through using an implant in the sinus tarsi (4, 20). A variety of procedures with different implants are suggested to accomplish this goal (1, 4, 6, 19, 21-25). Calcaneostop is one of these procedures that have gained interest in the past few years and limits the subtalar joint utilizing proprioceptive foot receptors (4).

In this case-series study, we aimed to evaluate the outcome of the calcaneostop procedure using cancellous screws.

Methods

This retrospective case series was undertaken from April 2018 to April 2020 in Rasoul-eAkram hospital, Tehran, Iran. We evaluated patients with symptomatic FFF undergoing a calcaneostop procedure. This study was approved by our institute's review board and the ethics committee of Iran University of Medical Sciences. The inclusion criteria were patients between 5 and 15 years old and symptomatic FFF. Exclusion criteria were rigid pes planus, asymptomatic FFF, no prior conservative treatment, and neurological, neuromuscular, or posttraumatic disorders.

The same pediatric orthopedic surgeon performed all surgeries. The patient had a supine position under general anesthesia, and the foot was placed in the inversion position. Following a 10-mm lateral incision precisely on sinus tarsi and drilling, under C-ARM guide, a 6.5-mm partial thread cancellous screw size 40 was inserted perpendicular to a line drawn from the tibia, medial to the lateral wall of the calcaneus. Tendon lengthening was performed using percutaneous Achilles tenotomy with the step-cut method. After the surgery, a short leg cast was applied for all patients for 4 weeks with full weight-bearing. The minimum follow-up time was 12 months.

We used Talocalcaneal (Kite), Talometatarsal (Meary's), and Calcaneal inclination (pitch) angles on plain radiographs. After checking for normality of data using Kolmogorov-Smirnov and Shapiro-Wilk tests and ruling out having outliers in the dataset (26), we compared preoperative and postoperative angles using a paired t test. Qualitative data are reported with numbers and percentages. Quantitative data are reported through mean ± standard deviation. We used SPSSVersion 16 (SPSS Inc) to analyze data. The significance level was set at $P < 0.05$.

Results

A total of 57 feet in 44 patients were evaluated. Based on the reported results in Table 1, of the total 44 patients, 27 (61.4%) were men and 17 (38.6%) women. There were 18 (40.9%) right legs and 26 (59.1%) left legs in the study. The mean age was 10.23 ± 2 (5-15). Pain relief was achieved in 55 (96.5%) cases. Postoperatively, patients demonstrated clinical improvement in addition to radiographic improvement (Fig. 1).

Radiographic Evaluation

The mean preoperative Meary's angle (Fig. 2) was 15.74 ± 2.02 (12.30-21.60), which decreased to 8.72 ± 1.03 (7.20-10.60) postoperatively, which lies within the normal range (27).

The mean preoperative and postoperative Kite angles (Fig. 3) were 31.23 ± 1.97 (27.80-37.30) and 21.30 ± 1.98 (18.50-24.60).

The mean preoperative calcaneal inclination angle (Fig. 4) was 12.40 ± 1.64 (8.50-16.60) and the postoperative calcaneal inclination angle was 18.52 ± 1.97 (15.90-22.60) (Table 2).

Complications

In 2 cases (3.5%), the patients experienced pain after surgery and were managed through screw removal after 6 months, and no additional surgery was performed on these patients (Table 1). Other complications, such as nerve damage, infection, screw loosening or fracture, or position loss, were not observed in this study.

Discussion

Flatfoot is a prevalent condition, particularly in children, which is estimated to involve 5% of children (1, 2, 4). Arthroeresis techniques have gained popularity to treat this condition. These techniques limit the subtalar joint motion by inserting a motion-blocking implant. Alvarez developed the calcaneostop procedure in 1970 by inserting a cancellous screw into the calcaneus to limit the motility of the subtalar joint (7).

The mean age of patients was 10.23 ± 2, ranging from 5 to 15. While there is no consensus regarding the optimal time for surgery, some authors recommend calcaneostop for patients around 8-12 years old because older patients may not yield the best results (10). Some studies have

Table 1. Demographic Information of Patients

Variable	Value
Age, mean (SD)	10.23 (2)
Gender, n (%)	
Male	27 (61.4)
Female	17 (38.6)
Laterality	
Right	18 (40.9)
Left	26 (59.1)
Pain relief	55 (96.5)
Complication	2 (3.5)

Data presented as mean (SD) or n (%).

Fig. 1. A. Preoperative anterior; B. Postoperative anterior; C. Preoperative Posterior; D. Postoperative Posterior

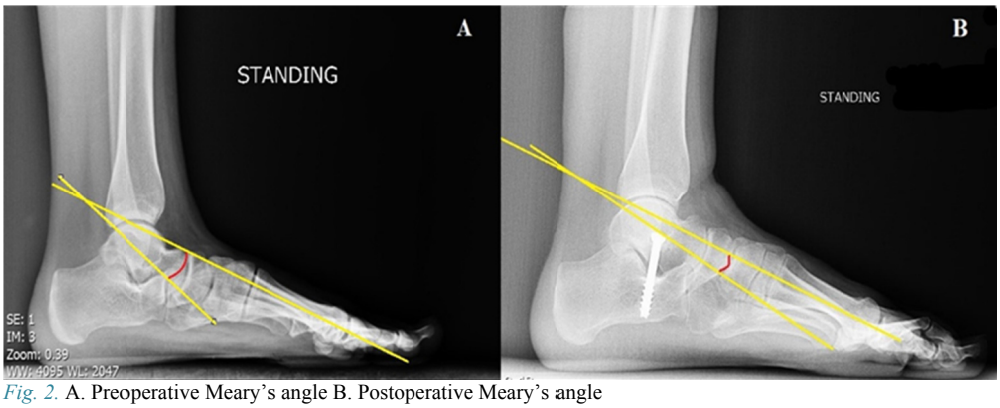

Fig. 2. A. Preoperative Meary's angle B. Postoperative Meary's angle

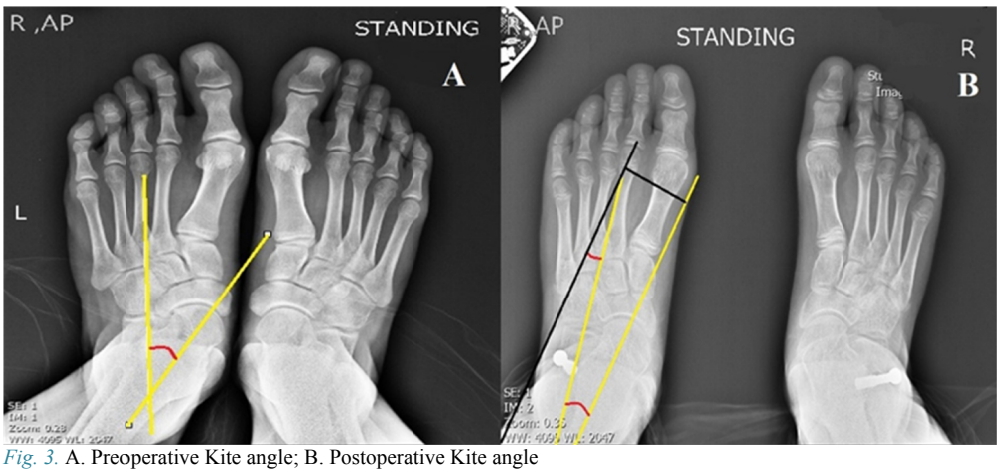

Fig. 3. A. Preoperative Kite angle; B. Postoperative Kite angle

reported a high success rate after surgery for older patients (8).

The results suggest that 96.5% of patients experienced pain relief after surgery. This finding is in accordance with other studies evaluating this procedure. Giannini et al reported a success rate of 95.5% after 88 surgeries in 44 feet (4). Magnan et al performed calcaneostop surgery on 475 patients and reported an 83% success rate with a follow-up of 12-112 months (28).

A percutaneous approach for this procedure is already

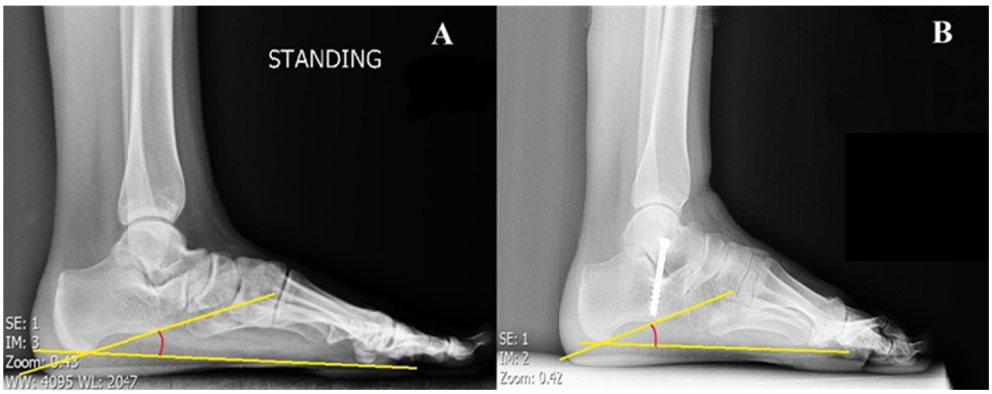

Fig. 4. A. Preoperative calcaneal inclination angle; B. Postoperative calcaneal inclination angle.

Table 2. Comparison Between Preoperative and Postoperative Radiographic Measurements

Variable	Preoperative, mean (SD)	Postoperative, mean (SD)	P Value
Meary's angle	15.74 (2.02)	8.72 (1.03)	<0.001
Kite angle	31.23 (1.97)	21.30 (1.98)	<0.001
Calcaneal inclination angle	12.40 (1.64)	18.52 (1.97)	<0.001

Data presented as mean (SD). The significance level was set at .05.

an established method. Roth et al inserted a temporary cancellous screw in 96 feet of 48 children and reported a 5-year success rate of 91.5% (23).

The mean postoperative measurements showed improvements in all Meary's, Kite, and calcaneal inclination angles comparing to preoperative measurements. These findings are consistent with those of prior studies (1, 8, 10, 29).

Achilles tendon lengthening was necessary in all (100%) cases. A rate of 87.6% representing 85 of the total 97 feet, is reported to undergo Achilles tendon lengthening in the study by Retana et al (10). This rate is almost similar to our findings.

Pain was experienced only in 2 feet (3.5%) after the surgery. Both feet underwent screw removal after 6 months, making the pain resolve. These patients underwent no additional procedure. Complication rates in our study were lower than the majority of previous studies. A 12% implant-related complication was reported aftter the calcaneostop procedure by Roth et al (23). According to a recent meta-analysis by Tan et al, the calcaneostop procedure was associated with an 8.78% complication rate (29). Jerosch et al evaluated the results of stop screw on 21 flat feet and reported a 10% complication in the patients (8).

This study, however, was not without flaws. First, the retrospective nature of the study could introduce some errors and bias into the study and limit our ability to maneuver on assess different variables. Second, we used only 1 type of implant in all the surgeries, while the implant material seems to be another important variable in evaluating the outcome. Third, the evaluated findings in this study were limited to short-term outcomes of the patients, and a longer follow-up is needed to evaluate long-term outcomes.

Conclusion

The calcaneostop procedure being an inexpensive and simple procedure, avoids the involvement of several joints and uses a simple incision that leaves only a small scar. Overall, calcaneostop has a remarkably high success rate and can be quite a convenient procedure for both surgeons and patients.

Acknowledgement

The authors would like to thank all those who contributed to this study in any possible way.

Conflict of Interests

The authors declare that they have no competing interests.

References

1. Kellermann P, Roth S, Gion K, Boda K, Tóth K. Calcaneo-stop procedure for paediatric flexible flatfoot. Arch Orthop Trauma Surg. 2011;131(10):1363-7.
2. Caravaggi P, Lullini G, Berti L, Giannini S, Leardini A. Functional evaluation of bilateral subtalar arthroereisis for the correction of flexible flatfoot in children: 1-year follow-up. Gait Posture. 2018;64:152-8.
3. Ferciot CF. The etiology of developmental flatfoot. Clin Orthop Relat Res. 1972;85:7-10.
4. Giannini S, Cadossi M, Mazzotti A, Persiani V, Tedesco G, Romagnoli M, et al. Bioabsorbable Calcaneo-Stop Implant for the Treatment of Flexible Flatfoot: A Retrospective Cohort Study at a Minimum Follow-Up of 4 Years. J Foot Ankle Surg. 2017;56(4):776-82.
5. Kwon JY, Myerson MS. Management of the flexible flat foot in the child: a focus on the use of osteotomies for correction. Foot Ankle Clin. 2010;15(2):309-22.
6. Nelson SC, Haycock DM, Little ER. Flexible flatfoot treatment with arthroereisis: radiographic improvement and child health survey analysis. J Foot Ankle Surg. 2004;43(3):144-55.
7. Usuelli FG, Montrasio UA. The calcaneo-stop procedure. Foot Ankle Clin. 2012;17(2):183-94.
8. Jerosch J, Schunck J, Abdel-Aziz H. The stop screw technique--a simple and reliable method in treating flexible flatfoot in children. Foot Ankle Surg. 2009;15(4):174-8.
9. Harris EJ, Vanore JV, Thomas JL, Kravitz SR, Mendelson SA, Mendicino RW, et al. Diagnosis and treatment of pediatric flatfoot. J Foot Ankle Surg. 2004;43(6):341-73.
10. Fernández de Retana P, Alvarez F, Viladot R. Subtalar arthroereisis

in pediatric flatfoot reconstruction. Foot Ankle Clin. 2010;15(2):323-35.
11. Smith C, Zaidi R, Bhamra J, Bridgens A, Wek C, Kokkinakis M. Subtalar arthroereisis for the treatment of the symptomatic paediatric flexible pes planus: a systematic review. EFORT Open Rev. 2021;6(2):118-29.
12. Viladot A. Surgical treatment of the child's flatfoot. Clin Orthop Relat Res. 1992(283):34-8.
13. Costa FP, Costa G, Carvalho MS, Moura AM, Pinto R, Torres J. Long-Term Outcomes of the Calcaneo-Stop Procedure in the Treatment of Flexible Flatfoot in Children: A Retrospective Study. Acta Med Port. 2017;30(7-8):541-5.
14. Das SP, Das PB, S G, Sahu MC. Effectiveness of surgically treated symptomatic plano-valgus deformity by the calcaneo stop procedure according to radiological, functional and gait parameters. J Taibah Univ Med Sci. 2017;12(2):102-9.
15. Hong J, Dai G, Weng Q, Liu Y. Interference Screw for the Treatment of Pediatric Flexible Flatfoot. J Foot Ankle Surg. 2020;59(6):1209-14.
16. Dare DM, Dodwell ER. Pediatric flatfoot: cause, epidemiology, assessment, and treatment. Curr Opin Pediatr. 2014;26(1):93-100.
17. Forg P, Feldman K, Flake E, Green DR. Flake-Austin modification of the STA-Peg arthroereisis: a retrospective study. J Am Podiatr Med Assoc. 2001;91(8):394-405.
18. De Pellegrin M, Moharamzadeh D, Strobl WM, Biedermann R, Tschauner C, Wirth T. Subtalar extra-articular screw arthroereisis (SESA) for the treatment of flexible flatfoot in children. J Child Orthop. 2014;8(6):479-87.
19. Pavone V, Costarella L, Testa G, Conte G, Riccioli M, Sessa G. Calcaneo-stop procedure in the treatment of the juvenile symptomatic flatfoot. J Foot Ankle Surg. 2013;52(4):444-7.
20. Faldini C, Mazzotti A, Panciera A, Persiani V, Pardo F, Perna F, et al. Patient-perceived outcomes after subtalar arthroereisis with bioabsorbable implants for flexible flatfoot in growing age: a 4-year follow-up study. Eur J Orthop Surg Traumatol. 2018;28(4):707-12.
21. Giannini S, Ceccarelli F, Benedetti MG, Catani F, Faldini C. Surgical Treatment of Flexible Flatfoot in Children: A Four-Year Follow-up Study. J Bone Joint Surg Am. 2001;83(2):S73-9.
22. Husain ZS, Fallat LM. Biomechanical analysis of Maxwell-Brancheau arthroereisis implants. J Foot Ankle Surg. 2002;41(6):352-8.
23. Roth S, Sestan B, Tudor A, Ostojic Z, Sasso A, Durbesic A. Minimally invasive calcaneo-stop method for idiopathic, flexible pes planovalgus in children. Foot Ankle Int. 2007;28(9):991-5.
24. Mosca VS. Flexible flatfoot in children and adolescents. J Child Orthop. 2010;4(2):107-21.
25. Saxena A, Nguyen A. Preliminary Radiographic Findings and Sizing Implications on Patients Undergoing Bioabsorbable Subtalar Arthroereisis. J Foot Ankle Surg. 2007;46(3):175-80.
26. Hoaglin DC, Iglewicz B. Fine-tuning some resistant rules for outlier labeling. J Am Stat Assoc. 1987;82(400):1147-9.
27. Bourdet C, Seringe R, Adamsbaum C, Glorion C, Wicart P. Flatfoot in children and adolescents. Analysis of imaging findings and therapeutic implications. Orthop Traumatol Surg Res. 2013;99(1):80-7.
28. Magnan B, Baldrighi C, Papadia D. Flatfeet: comparison of surgical techniques. Result of study group into retrograde endorthesis with calcaneus-stop. Ital J Ped Orthop. 1997;13:28-33.
29. Tan JHI, Tan SHS, Lim AKS, Hui JH. The outcomes of subtalar arthroereisis in pes planus: a systemic review and meta-analysis. Arch Orthop Trauma Surg. 2021;141(5):761-73.