

Significant weight loss, nausea, and vomiting due to strongyloidiasis: a case report

Hossein Froutan, MD,¹ Ayatollah Bayatian, MD,² Seied Mohsen Razavizadeh, MD,³,
Mohsen Nasiri-Toosi, MD,⁴ Afshin Shafaghi, MD.⁵

Department of Internal Medicine, Imam Khomeini Hospital, Tehran, Iran.

Abstract

Strongyloidiasis is caused by infestation with *Strongyloides stercoralis*, a free living tropical and semitropical soil helminth that has a larval form that penetrates intact skin. Clinical manifestations may be varied from an asymptomatic infection in immunocompetent hosts to a diffuse and fatal form in immunocompromised hosts.

We report a 56-year-old man from Dezfoul (south-west of Iran) with a 6-month history of nausea, vomiting and significant weight loss (greater than 10%). Abdominal ultrasonography had no significant findings. Upper gastrointestinal series and abdominal CT were performed. Dilated bowel loops especially in the jejunum, with decreased mucosal folds were seen. A biopsy specimen from the third part of duodenum showed strongyloides larvae, thus albendazole 400 mg twice a day for 3 days was initiated. He responded well to this treatment regimen.

Keywords: strongyloidiasis, nausea, vomiting, albendazole.

Introduction

Strongyloidiasis is endemic in tropical and semitropical regions. *Strongyloides* exists as a free-living organism that does not require a host to replicate. There is reported data of skin disease that contacts the soil. Filariform larvae can penetrate any area of the skin, after which they migrate through the dermis to enter the vasculature. The larvae circulate in the venous blood until they reach the lungs, where they break into the alveoli and ascend the bronchial tree. The worms are then swallowed with saliva and pass into the small bowel, where they embed in the duodenojejunal mucosa and mature. Most patients with strongyloidiasis have no frank symptoms. Patients may have an urticari-

al rash (larvae currens) caused by dermal migration of fillariform larvae and non-productive cough with or without hemoptysis [1] due to lung migration stage. Occasionally, patients have abdominal pain, anorexia, nausea, vomiting and diarrhea due to gastrointestinal involvement. *S. stercoralis* can survive in the body for a long time due to autoinfection.

In immunocompromised hosts, disseminated organ involvement, (lungs, CNS, GI-tract, liver,...) may occur. Bacteremia and septic shock may cause a high mortality [2].

Infection can be diagnosed by finding rhabditiform larvae in direct smears of the stool, positive serologic tests, study of duodenal aspirate and intestinal biopsy. Strongyloidiasis is treated with ivermectin, albendazole and thiabendazole [3]. As mentioned above, abdomi-

1. Professor of Gastroenterology, Tehran University of Medical Sciences, Chairman of Gastroenterology Dept.

2. **Corresponding author**, Assistant Professor of Internal Medicine, Internal Medicine Ward, Imam Khomeini Hospital, Tehran, Iran. Tel: +989122497819, email: bayatian@yahoo.com.

3. Assistant Professor of Gastroenterology, Imam Khomeini Hospital.

4. Associate Professor of Gastroenterology, Tehran University of Medical Sciences, Tehran, Iran.

5. Assistant Professor of Gastroenterology, Imam Khomeini Hospital.

nal symptoms are the usual presentation of this infection. Our patient presented not only with abdominal symptoms, but a significant loss of weight that may herald malignancies.

Case report

A 56 year old man from Dezful (south west of Iran) referred to our hospital with a 6 month history of bloating, epigastric and left lower quadrant pain, nausea and vomiting after eating. He had a significant loss of weight (18kg) (greater than 10% loss of his baseline body weight). He had a normal appetite. He had no history of diarrhea and melena. His abdominal pain did not correlate with body position. He had a history of pelvic fracture due to trauma and minor thalassemia. The patient was cachectic with a pale appearance. Vital signs were normal. Lung and heart exams were normal. The abdomen was soft with normal bowel sounds. There was no organomegaly or ascites. There was (+1) pitting edema in both lower limbs. The laboratory values were as follow:

| | |
|------------------------------|------------------------------|
| WBC = 11000/mm ³ | PMN= 60% |
| lymph= 35% | Eos= 4% |
| Mono= 1% | Hemoglobin= 9.2 g/dl |
| MCV = 57 fL | MCH=19.6 |
| PIT = 201000/mm ³ | AST = 34 u/L |
| ALT = 33 u/L | ALP = 251 u/L |
| Bil (Total)= 0.6 mg/dl | Bil direct = 0.1 mg/dL |
| PT = 15 sec | PTT = 38 sec |
| INR = 1.2 | HIV (Ab) = negative |
| Antigliadin Ab = negative | Antiendomysial Ab = negative |
| FBS = 85 mg/dL | BUN = 15 mg/dL |
| Creat = 0.6 mg/dL | Na ⁺ = 144 mmol/L |
| K ⁺ = 4.9 mmol/L | LDH = 507 u/L |
| Serum iron = 91 micg/mL | TIBC = 190 micg/mL |
| Ferritin = 103 micg/mL | U/A = normal |
| ESR = 3 mm/h | CRP = 2.9 mg/L |
| Albumin = 2.6 gr/dL | Protein = 5.5 gr/dL |

Stool exam was negative for ova and parasites and occult blood on three occasions.

Abdominal ultrasonography was normal. Plain film of the abdomen (Fig.1a) showed dilated bowel loops. Upper gastrointestinal series (Fig.1b) and abdominal CT were performed. Dilated bowel loops especially in the jejunum

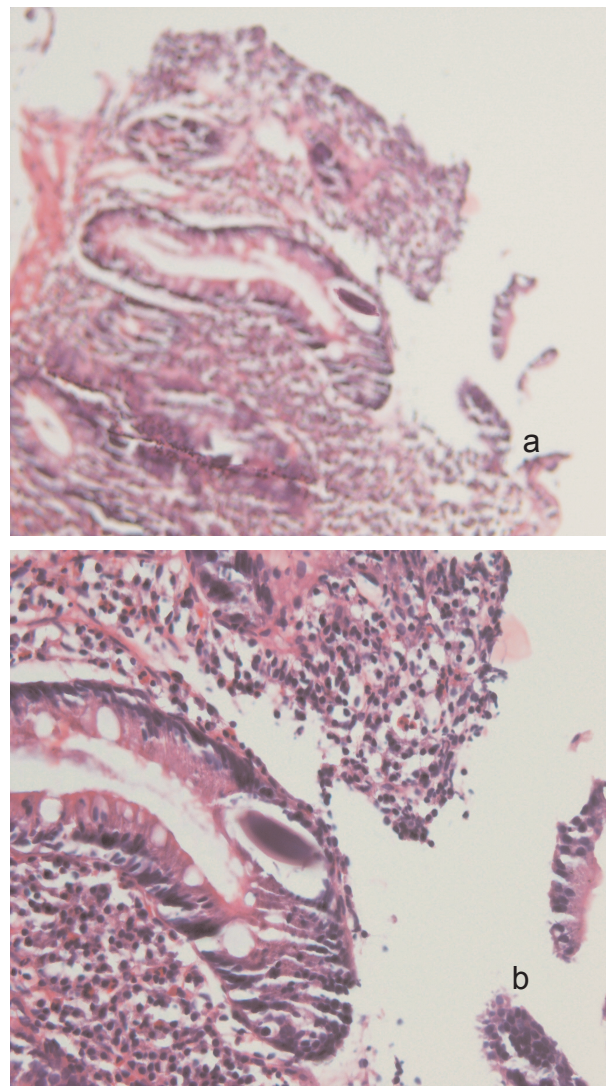


Fig. 1. Strongyloides larva in duodenal biopsy.

with decreased mucosal folds were seen. A biopsy specimen from the third part of the duodenum showed moderate villous atrophy and marked crypt hyperplasia with mild to moderate infiltration of lymphocytes and plasma cells in the lamina propria. Adult worm, larvae and eggs of strongyloides stercoralis were seen in lamina propria and lumen of the crypts. Thus albendazole 400 mg twice a day for 3 days was initiated.

Discussion

Most immunocompetent hosts of *S. stercoralis* are asymptomatic. Symptomatic patients may have an urticarial rash caused by migration

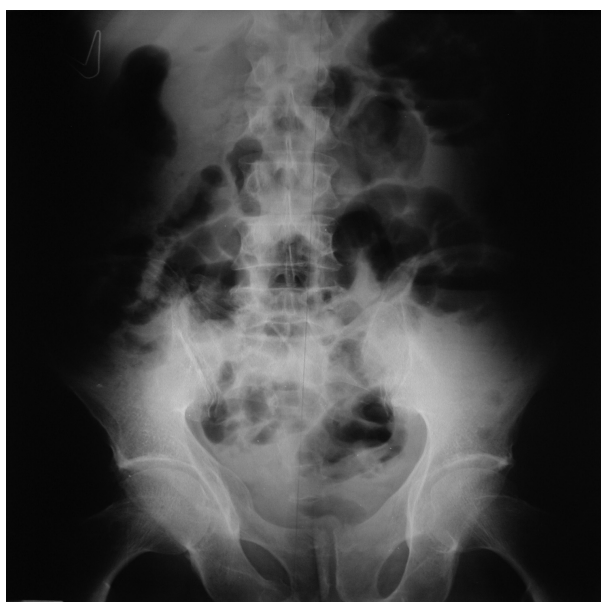

Fig. 2. Distended intestinal loops in plain abdominal X ray.

of larvae. Lung migration may cause cough, dyspnea, fever, hemoptysis [1], and peripheral eosinophilia. Our patient did not have any cutaneous manifestations or frank eosinophilia.

The mature worm can cause peptic ulcer-like pain due to gastritis, gastric ulcer and duodenitis. Patients may have anorexia, nausea and vomiting. Gastrointestinal involvement can cause malabsorption and intestinal obstruction. [4,5]

Massive and potentially fatal infection may occur in immunocompromised hosts [2]. In addition, we should search for the presence of infective larvae before initiation of glucocorticoids or administration of immunosuppressive drugs [6]. Strongyloidiasis can be diagnosed routinely by direct smears of stool and enzyme-linked immunosorbent assay (ELISA) for IgG antibodies against *S. stercoralis* [7]. Intestinal biopsy is an insensitive method but is specific. Our patient had 3 negative consequent stool exams for larvae. We performed an upper gastrointestinal endoscopy for the assessment of bowel dilation. A biopsy specimen was taken from the third part of the duodenum, and larvae were seen in this specimen. (Fig.1)

Upper GI endoscopy may show edema,

brown discoloration of duodenal mucosa and submucosal hemorrhage. Colonoscopy may show edema, decreased vascularity and ulcers [8,9]. Upper GI endoscopy showed mucosal atrophy of the duodenum in our patient and colonoscopy was normal. Our patient was treated with albendazole. Abdominal symptoms improved and he gained his ideal weight.

According to epidemiological data, we should consider this infection in endemic regions, especially when unusual or atypical symptoms occur. Because of potentially fatal complications, immunosuppressive drugs should be postponed until subclinical infection is ruled out.

References

1. Strazzella WD., Safirstein B.H. Asthma due to parasitic infestation. *N J Med* 1989, Dec; 86(12):947-9.
2. Keiser PB, Nutman TB, Strongyloides stercoralis in the immunocompromised population. *Clin Microbiol Rev* 2004 Jan. 17(1): 208-17.
3. Muennig P, et al. The cost effectiveness of ivermectin vs. albendazole in the presumptive treatment of strongyloidiasis in immigrants to the United States. *Epidemiol Infect* 2004 Dec 132(6):1055-63.
4. Shekar KC, Krishnan R. Gastric strongyloidiasis. *Southeast Asian J Trop Med Public Health* 1997. 28 (1):158-60.
5. Sreenivas DV, et al: Intestinal strongyloidiasis; a rare opportunistic infection. *Indian J Gastroenterol* 1997 Jul;16 (3):105-6.
6. Scheaffer MW, et al: Strongyloides hyperinfection syndrome after heart transplantation. *G J Heart Lung Transplant* 2004 Jul. 23(7):905-11.
7. Carroll SM, et al. Serodiagnosis of human strongyloidiasis by an enzyme-linked immunosorbent assay. *Trans R Soc Trop Med Hyg* 1981;75(5):706-9.
8. Thompson BF, et al. The spectrum of GI strongyloidiasis: an endoscopic-pathologic study. *Gastrointest Endosc* 2004 Jun. 59(7) 906-10.
9. Rivasi F, et al: Histopathology of gastric and duodenal Strongyloides stercoralis location in fifteen immunocompromised subjects. *Arch Pathol Lab Med* 2006 Dec. 130(12): 1792-8.