




# A Study of Characteristic Features and Diagnostic Roles of X-ray and MRI in Calcifying Tendinitis of the Shoulder

Morteza Nakhaie Amroodi<sup>1</sup>, Shadi Abdolahi Kordkandi<sup>2</sup>, Mehdi Moghtadaei<sup>2</sup>, Hossein Farahini<sup>2</sup>, Shayan Amiri<sup>2</sup>, Mikael Hajjalizade<sup>2\*</sup> 

Received: 11 Dec 2021

Published: 16 Jul 2022

## Abstract

**Background:** Calcifying tendinitis (CT) is an enigmatic lesion with several obscure aspects and it is a common disorder of the upper extremity characterized by the presence of calcifications in rotator cuff tendons and synovial tissues. In this study, we aimed to review the demographic and clinical characteristics, as well as radiologic and treatment history in CT patients who were referred with shoulder pain.

**Methods:** In this cross-sectional study, a total of 146 patients who were referred with a shoulder CT were included. The definitive diagnosis was based on a combination of plain radiograph and magnetic resonance imaging (MRI). A predesigned independent t test was used to capture demographic and clinical data, as well as radiologic and treatment histories, and a chi-square test was utilized to assess the statistical correlation between qualitative variables.

**Results:** The median age of the patients was 42.5 years. The female to male ratio was 2.3 to 1. The complaint of restricted shoulder movement was recorded in 107 (73.3%) patients and more frequently in women ( $p = 0.042$ ). Night pain was present in 109 (74.7%) patients. The current and previous diagnoses matched in 36.1% (13 out of 36) of patients who only had MRI and in 63.6% (35 out of 55) patients who had both MRI and plain radiograph with them. Supraspinatus tendon was the main site of calcified deposition 65% (95 out of 146).

**Conclusion:** CT is frequent at the age of around 40 and in the female gender. The diagnosis should be based on a combination of radiography and MRI and not based on MRI alone. The efficacy of different conservative treatments remains to be unwrapped.

**Keywords:** Calcifying Tendinitis, Rotator Cuff Tear, Conservative Treatment

**Conflicts of Interest:** None declared

**Funding:** None

\*This work has been published under CC BY-NC-SA 1.0 license.

Copyright© Iran University of Medical Sciences

**Cite this article as:** Nakhaie Amroodi M, Abdolahi Kordkandi S, Moghtadaei M, Farahini H, Amiri S, Hajjalizade M. A Study of Characteristic Features and Diagnostic Roles of X-ray and MRI in Calcifying Tendinitis of the Shoulder. *Med J Islam Repub Iran.* 2022 (16 Jul);36:79. <https://doi.org/10.47176/mjiri.36.79>

## Introduction

Calcifying tendinitis (CT) of the shoulder is a common disorder of the upper extremity characterized by the presence of calcifications in rotator cuff tendons and synovial tissues. The calcific component is generally comprised of

calcium hydroxyapatite in crystalline or amorphous presentation (1). The incidence of CT varies between 2.7% and 20% in the asymptomatic population. The majority of patients are aged 30 to 50 years. Women are reported to be more affected (2). Although it has been associated with a

**Corresponding author:** Dr Mikael Hajjalizade, [michaelalizadeh@gmail.com](mailto:michaelalizadeh@gmail.com)

<sup>1</sup> Bone and Joint Reconstruction Research Center, Shafa Orthopedic Hospital, Iran University of Medical Sciences, Tehran, Iran

<sup>2</sup> Department of Orthopedics, Rasul-e Akram Hospital, Iran University of Medical Sciences, Tehran, Iran

### ↑What is “already known” in this topic:

Calcific tendinitis is frequent at the age of around 40 and in the female gender. It is a common disorder of the upper extremity characterized by the presence of calcifications in rotator cuff tendons and synovial tissues.

### →What this article adds:

Calcific tendinitis diagnosis should be based on a combination of radiography and MRI and not based on MRI alone. The efficacy of different conservative treatments remains to be unwrapped.

degenerative process, the exact etiology of CT remains unknown (3). The clinical picture is highly variable and includes asymptomatic patients, patients with chronic pain, and patients with acute painful crises (4). Plain radiograph, magnetic resonance imaging (MRI), and ultrasonography are widely used for the detection of calcific deposits and the diagnosis of CT (5).

Treatment varies from monitoring in asymptomatic patients and conservative management as the initial treatment of symptomatic patients. Arthroscopic debridement of the deposit and open surgery are the subsequent therapeutic choices in patients with progressive disability and where conservative treatments fail to improve symptoms (5, 6). Several conservative treatments have been introduced for CT, including nonsteroidal anti-inflammatory drugs (NSAIDs), physiotherapy, electrotherapies such as extracorporeal shock wave, anti-inflammatory radiotherapy, ultrasound-guided needling, and corticosteroid therapy (7-9). However, the best choice of conservative treatment for CT remains controversial (5).

Since symptomatic CT is a debilitating condition with a significant socioeconomic impact and work absenteeism, further research are required regarding its epidemiology, clinical characteristics, imaging study, and optimal treatment.

The goal of this study was to examine the clinical and demographic parameters, as well as the imaging and treatment histories of CT patients referred to our institute's shoulder clinic.

## Methods

This cross-sectional study was approved by the review board of our institute and written informed consent was obtained from patients before they participated in the study. In a cross-sectional design, patients with a confirmed diagnosis of symptomatic calcifying tendinitis who were referred to the shoulder clinic of our university hospital between 2016 and 2019 were included, and the associated data were recorded in a predesigned checklist. Although many patients already had plain radiographs at the referral session, in the majority of cases 86% (125 cases), only 1 radiographic view (mainly anteroposterior) was present. For this reason, new radiographs were obtained for all patients in all 3 standard views (anteroposterior, axillary, and true lateral scapular). Moreover, many patients already had an MRI with them. However, as our center is a referral center for shoulder injuries and the patients were referred from all over the country, the MRIs were obtained with different scanners ranging from 0.28 to 3 Tesla. Moreover, MRI results were reported by different radiologists and the majority of them (71%) (n = 103 cases) were not even musculoskeletal radiologists. For these reasons, all the MRIs were also repeated to be performed by the same machine. The definitive diagnosis was based on a combination of plain radiographs and MRI. In this respect, both the plain radiographs and MRI were seen by a musculoskeletal radiologist and an orthopedic shoulder surgeon. If the diagnosis of CT was made by both observers, the case was included. In case the diagnosis of the 2 observers did not match, it was dis-

cussed by the 2 observers to reach a consensus. If the observers did not agree on a diagnosis, the case was excluded from the study. After excluding other problems such as tumors and other shoulder certain diagnoses, a total of 146 participants were assessed in the study (10).

The checklist included demographic and clinical information, as well as radiologic and treatment history. The clinical information included the symptom duration, history of clinical examination, history of trauma, presence of night pain, and complaint of restricted shoulder movement. The radiologic information comprised of the history of plain radiographs or MRI before the referral, and the history of diagnosis (CT, rotator cuff tear, both or none). The location of calcification was identified on the plain radiographs and categorized into 4 subsets, including supraspinatus (SSP), subscapularis (SSC), infraspinatus (ISP), and teres minor (TM). The treatment information included the choice of conservative modality that was used for the subsidence of pain.

## Statistical Analysis

SPSS for Windows Version 16 was used for the statistical analysis of the data. Descriptive data were provided as mean  $\pm$  standard deviation or number and percentage. A comparison of the mean age between different groups was done with an independent t test. A chi-square test was used for the evaluation of the statistical association between qualitative variables.  $P < 0.05$  was considered significant.

## Results

A total of 146 patients with a confirmed diagnosis of shoulder CT were evaluated. The mean age of the patients was  $42.8 \pm 8.9$  years (range, 28-66 years). The median age of the patients was 42.5 years. The study population included 44 (30.1%) men and 102 (69.9%) women. Accordingly, the female to male ratio was 2.3 to 1. The mean age of the patients was not significantly different between male and female patients ( $p = 0.718$ ). The dominant and non-dominant shoulders were involved in 83 (56.8%) and 63 (43.2%) patients. The mean duration of symptoms was  $7.9 \pm 0.4$  months (range, 1-36 months). The mean duration of symptoms was not significantly different between men and women ( $p = 0.627$ ). A total of 92 (63%) patients had a history of clinical evaluation. History of trauma was noticed in 55 (37.7%) cases. The complaint of restricted shoulder movement was recorded in 107 (73.3%) patients, significantly more frequent in the female population ( $p = 0.042$ ). Night pain was present in 109 (74.7%) patients. The presence of night pain was not significantly different between men and women ( $p = 0.399$ ). The clinical and demographic characteristics of male and female patients are compared in Table 1.

A total of 34 (23.3%) patients already had a plain radiograph of the affected shoulder with them; 36 (24.6%) patients only had an MRI of the affected shoulder with them; 55 (37.7%) patients had both plain radiograph and MRI of the involved shoulder along; 21 (14.4%) patients had no imaging modality with them. In total, the historical radiology report included the diagnosis of CT alone in 10 (11%) patients, the diagnosis of rotator cuff tear alone in 31

**Table 1.** Comparison of demographic and clinical characteristics between male and female patients with calcifying Tendonitis

Variable	Male patients (n=44)	Female patients (n=102)	P-value
Age (year)	43.18±9.5	42.6±8.7	0.718
Hand dominancy			
Dominant	26 (59.1)	57 (55.9)	0.428
Non-dominant	18 (40.9)	45 (44.1)	0.428
Symptom duration (month)	8.2±5.8	7.8±3.6	0.627
History of trauma			
Positive	17 (38.6)	38 (37.3)	0.499
Negative	27 (61.4)	64 (62.7)	0.499
ROM restriction			
Positive	27 (61.4)	80 (78.4)	0.042
Negative	17 (38.6)	22 (21.6)	0.042
Night pain			
Positive	34 (77.3)	75 (73.5)	0.399
Negative	10 (22.7)	27 (26.5)	0.399

Data are presents as mean ± SD or number (%).  $P < 0.05$  is considered significant. ROM: range of motion.

**Table 2.** Radiology report in CT patients who had an MRI with or without radiograph

Radiology report	Only MRI	MRI+Radiograph	Total
CT	4 (11.1%)	6 (10.9%)	10 (11%)
Partial or complete RCT	12 (33.3%)	19 (34.5%)	31 (34.1%)
CT & RCT	18 (50%)	27 (49.1%)	45 (49.5%)
None	2 (5.6%)	3 (5.5%)	5 (5.5%)
Total	36 (100%)	55 (100%)	91 (100%)

CT:calcific tendinitis, RCT:rotator cuff tear

(34.5%) patients, both CT and rotator cuff tear in 45 (49.5%) patients, and none in 5 (5.5%) cases. The tear was reported as partial in 71 (93.4%) cases and complete in 5 (6.6%) cases. Previous radiology report in patients who had an MRI with or without a radiograph is summarized in [Table 2](#).

Based on our evaluation, the diagnosis was CT alone in 117 (80.1%) cases and CT in association with rotator cuff tear in 29 (19.9%) cases. From a total of 91 patients who already had an MRI report with them, the current and previous diagnoses matched in 36.1% (13 out of 36) of patients who only had an MRI and in 63.6% (35 out of 55) patients who had both MRI and plain radiograph with them.

Based on our radiologic evaluation, SSP was the main site of calcified deposition that was seen in 95 (65%) cases. The calcific deposit in ISP, SSC, and TM were seen in 42 (28.7%), 33 (22.6%), and 7 (4.8%) cases, respectively. In 31 (21.2%) cases, the calcific deposit was seen in 2 regions (multifocal calcifications). No significant association was found between the number of calcification foci and the presence of night pain ( $p = 0.268$ ) or complaint of restricted movement ( $p = 0.449$ ).

NSAID consumption was recorded in 116 (79.5%) patients. A total of 115 (78.8%) patients had a history of physiotherapy. The mean number of physiotherapy sessions was  $21.8 \pm 10.8$  (range, 10-50 sessions). A total of 33 (22.6%) patients had a history of corticosteroid injection. Thirteen (8.9%) patients had a history of hyaluronic acid injection. History of cupping therapy, ozone therapy, and leeching therapy was also recorded in 26 (17.8%), 7 (4.8%), and 8 (5.5%) patients, respectively.

## Discussion

In this study, we reviewed the demographic and clinical features, as well as imaging and treatment history in shoulder CT patients who were referred to our center. Based on

the results of the present study, the median age of the patients was 42.5 years, and the disease was 2.31 times more frequent in women. The night pain and complaint of restricted shoulder movement were present in the majority of cases. Complaint of restricted shoulder movement was significantly more in women. At the entrance, 23.3%, 24%, and 37.7% of patients already had a plain radiograph, MRI, or both, respectively. In patients whose diagnosis was based solely on MRI, the rate of the wrong diagnosis was much higher than in patients whose diagnosis was based on both MRI and radiography (63.9% vs 36.4%). The main site of calcific localization was SSP (65%). Several types of conservative treatment, including conventional medicine, were used for the treatment of CT.

Based on the previous epidemiologic studies, CT is mostly presented at the age of 30 to 60 years. The median age of patients in the current study was 42.5 years, which was consistent with earlier investigations (5). Besides, CT has been found to more frequently affect women (11). The frequency of women was considerably more in the present study as well. Supraspinatus tendon has also been reported as the most common localization of calcific deposition, with an incidence of 51.5% to 90% of cases (12, 13). Similarly, the main localization of calcification in the present series was SSP that was detected in 65% of cases. The prevalence of multifocal calcific deposits is 8% to 28.2% in previous investigations (5, 14) and 21.2% in the present study, which were also comparable. Shoulder pain, which may or may not be linked with shoulder movement restriction, is the most common clinical sign of CT (15). Pain and complaint of shoulder movement restriction were the most clinical picture in the current report as well. We did not observe any significant association between numbers of calcification and the night pain or complaint of shoulder movement restriction. Repetitive trauma has been acknowledged as a

CT predisposing factor (16). A history of trauma was noticed in 37.7% of patients in the current series.

The pain level and age of the shoulder CT patients closely resemble rotator cuff tears (17-19). Thus, the differential diagnosis of CT and rotator cuff tear is challenging. Moreover, CT might be associated with rotator cuff tears in many cases. Jim et al evaluated the coexistence of CT and rotator cuff tear by arthrography in 81 patients who presented with shoulder pain. In 22 (27.1%) patients, a partial or complete rotator cuff tear was detected. They concluded that the coexistence of CT with rotator cuff tear is common, particularly in older patients (20). The CT was associated with rotator cuff tear in 19.9% of patients of the current series.

In a considerable number of patients in whom the previous diagnosis was based on MRI alone (38.7%), the diagnosis was partial or complete rotator cuff tear. However, after our in-depth evaluation using both plain radiographs and MRI, they were diagnosed as CT (Figs. 1 and 2). This rate of inconsistency supports the inaccuracy of sole MRI-based diagnosis of CT. Although MRI provides excellent soft-tissue visualization and allows for multiplanar imaging study with high resolution, it is not recommended for the diagnosis of CT, as the hypointense appearance of calcific deposits in MRI makes them difficult to be reliably distinguished from artifacts (21). Accordingly, the diagnosis of CT should be based on a combination of plain radiograph and MRI and should not be based on MRI alone. Radiography is the most practical modality for the diagnosis of CT (22, 23) and MRI could only be used as an adjunct diagnostic approach (23). Furthermore, MRI should be performed using high-tesla scanners and analyzed by two observers (1 musculoskeletal radiologist and 1 shoulder surgeon) to get a trustworthy diagnosis. A variety of conservative treatments have been introduced for the treatment of CT, and the extent of these treatments is on the increase (5). Recently, autologous platelet-rich plasma (PRP) therapy and other new treatments have also been introduced as a choice of conservative treatment in CT and other orthopedic problems (24-26). However, the results of the majority of these treatments seem to be conflicting, and further studies are needed to reach a consensus regarding the optimal conservative treatment for CT (5). A considerable number of patients in the present study experienced traditional medicine, such as leeching, cupping, and ozone therapy. Even so, the efficacy of these treatments in the management of CT is not approved.

There were certain limitations to this study that should be mentioned. The patient occupation, which could be linked to the occurrence of CT, was not documented in this study. Furthermore, because this was a single-center study, the results may not be generalizable.

### Conclusion

Calcifying tendinitis is a prevalent upper extremity disorder at the age of around 40 years, mostly in women. It could be associated with debilitating pain and complaint of restricted shoulder movement. A mix of plain radiographs and MRIs should be used to make the diagnosis, as an MRI alone could lead to a misdiagnosis. Furthermore, in a sig-

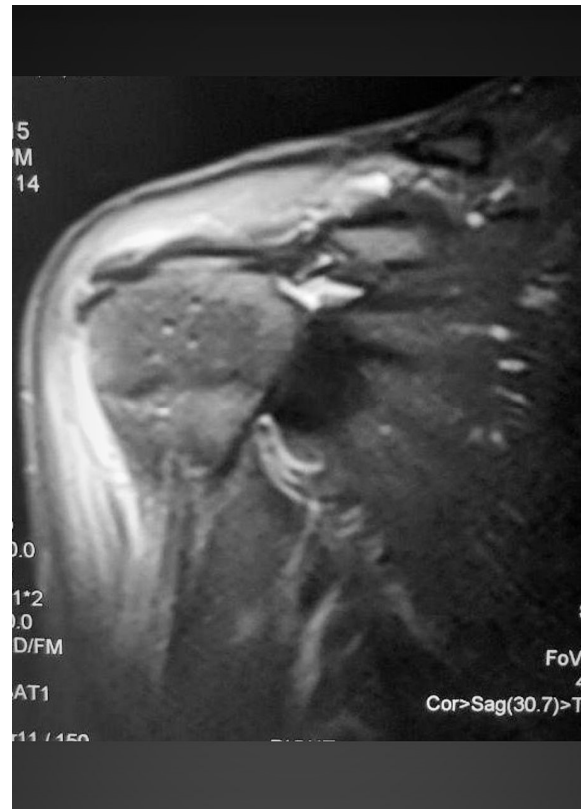

Fig. 1. MRI of 37 y/o female with Rt shoulder pain since 5month ago who was treated as bursitis

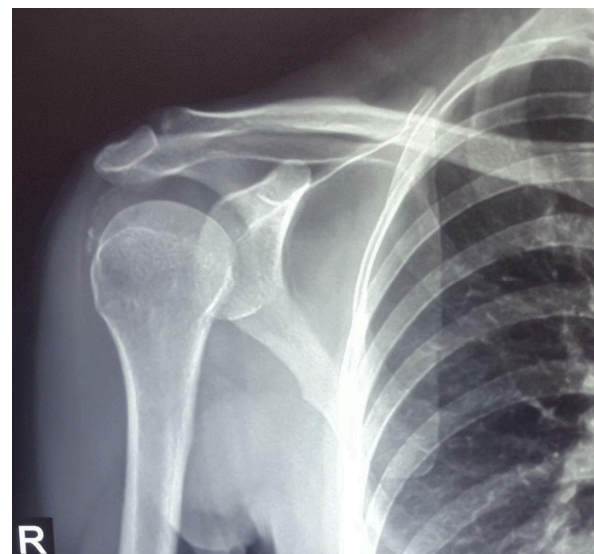


Fig. 2. After 5 months anteroposterior shoulder x-ray for the first time was taken and calcify tendonitis was obviously seen

nificant number of patients, low tesla MRI or MRI interpretation by an unqualified person result in an incorrect diagnosis. More research on the best conservative treatment options, including traditional medicine, is required.

### Acknowledgment

Not applicable.

### Ethical Consideration

This research was approved by the ethical committee of Iran university of medical sciences under this code IR.IUMS.REC.1398.475.

### Conflict of Interests

The authors declare that they have no competing interests.

### References

- Chiou HJ, Hung SC, Lin SY, Wei YS, Li MJ. Correlations among mineral components, progressive calcification process and clinical symptoms of calcific tendonitis. *Rheumatology (Oxford, England)*. 2010;49(3):548-55.
- Lemak DG, Lemak LJ. *Calcific Tendinitis. The Athlete's Shoulder*: Elsevier; 2009. p. 155-8.
- Uhthoff HK, Sarkar K, Maynard JA. Calcifying tendinitis: a new concept of its pathogenesis. *Clin Orthop Relat Res*. 1976(118):164-8.
- Hurt G, Baker CL. Calcific tendinitis of the shoulder. *Orthop Clin*. 2003;34(4):567-75.
- Sansone V, Maiorano E, Galluzzo A, Pascale V. Calcific tendinopathy of the shoulder: clinical perspectives into the mechanisms, pathogenesis, and treatment. *Orthop Res Rev*. 2018;10:63-72.
- Barber FA, Cowden III CH. Arthroscopic treatment of calcific tendonitis. *Arthrosc Tech*. 2014;3(2):e237-e40.
- Kachewar SG, Kulkarni DS. Calcific tendinitis of the rotator cuff: a review. *J Clin Diagn Res*. 2013;7(7):1482-5.
- Kim YS, Lee HJ, Kim YV, Kong CG. Which method is more effective in treatment of calcific tendinitis in the shoulder? Prospective randomized comparison between ultrasound-guided needling and extracorporeal shock wave therapy. *J Shoulder Elbow Surg*. 2014;23(11):1640-6.
- Flores C, Balias R, Álvarez G, Buil MA, Varela L, Cano C, et al. Efficacy and Tolerability of Peritendinous Hyaluronic Acid in Patients with Supraspinatus Tendinopathy: a Multicenter, Randomized, Controlled Trial. *Sports Med Open*. 2017;3(1):22-.
- Jamshidi K, Bozorgi MHA, Hajjalizade M, Bagherifard A, Mirzaei A. Tailored treatment of aneurysmal bone cyst of the scapula: en bloc resection for the body and extended curettage for the neck and acromion. *J Shoulder Elbow Surg*. 2020;29(5):961-7.
- De Carli A, Pulcinelli F, Rose GD, Pitino D, Ferretti A. Calcific tendinitis of the shoulder. *Joints*. 2014;2(3):130-6.
- Clavert P, Sirveaux F. [Shoulder calcifying tendinitis]. *Rev Chir Orthop Reparatrice Appar Mot*. 2008;94(8 Suppl):336-55.
- Le Goff B, Berthelot JM, Guillot P, Glemarec J, Maugars Y. Assessment of calcific tendonitis of rotator cuff by ultrasonography: comparison between symptomatic and asymptomatic shoulders. *Joint Bone Spine*. 2010;77(3):258-63.
- Ogon P, Suedkamp NP, Jaeger M, Izadpanah K, Koestler W, Maier D. Prognostic factors in nonoperative therapy for chronic symptomatic calcific tendinitis of the shoulder. *Arthritis Rheum*. 2009;60(10):2978-84.
- Uhthoff HK, Loehr JW. Calcific Tendinopathy of the Rotator Cuff: Pathogenesis, Diagnosis, and Management. *J Am Acad Orthop Surg Glob Res Rev*. 1997;5(4):183-91.
- BOSWORTH BM. Calcium deposits in the shoulder and subacromial bursitis: a survey of 12,122 shoulders. *JAMA*. 1941;116(22):2477-82.
- Yamamoto A, Takagishi K, Kobayashi T, Shitara H, Osawa T. Factors involved in the presence of symptoms associated with rotator cuff tears: a comparison of asymptomatic and symptomatic rotator cuff tears in the general population. *J Shoulder Elbow Surg*. 2011;20(7):1133-7.
- Tashjian RZ. Epidemiology, natural history, and indications for treatment of rotator cuff tears. *Clin Sports Med*. 2012;31(4):589-604.
- Eraghi AS, Hajjalizade M, Shekarchizadeh E, Kordkandi SA. Role of shoulder gradient in the pathogenesis of rotator cuff tears. *World J Orthop*. 2020;11(4):206-12.
- Jim YF, Hsu HC, Chang CY, Wu JJ, Chang T. Coexistence of calcific tendinitis and rotator cuff tear: an arthrographic study. *Skeletal Radiol*. 1993;22(3):183-5.
- Chen W, Zhu W, Kovanlikaya I, Kovanlikaya A, Liu T, Wang S, et al. Intracranial calcifications and hemorrhages: characterization with quantitative susceptibility mapping. *Radiology*. 2014;270(2):496-505.
- Faure G, Daculsi G. Calcified tendinitis: a review. *Ann Rheum Dis*. 1983;42(Suppl 1):49.
- Siegel DS, Wu JS, Newman JS, del Cura JL, Hochman MG. Calcific tendinitis: a pictorial review. *Can Assoc Radiol J*. 2009;60(5):263-72.
- Foster TE, Puskas BL, Mandelbaum BR, Gerhardt MB, Rodeo SA. Platelet-rich plasma: from basic science to clinical applications. *Am J Sports Med*. 2009;37(11):2259-72.
- Seijas R, Ares O, Alvarez P, Cusco X, Garcia-Balletbo M, Cugat R. Platelet-rich plasma for calcific tendinitis of the shoulder: a case report. *J Orthop Surg (Hong Kong)*. 2012;20(1):126-30.
- Hajjalizade M, Moghtadaei M, Mirzaei A, Kordkandi SA, Babaheidarian P, Pazoki-Toroudi H, et al. Significant effect of simvastatin and/or ezetimibe-loaded nanofibers on the healing of femoral defect: An experimental study. *Mater Sci Eng C Mater Biol Appl*. 2020;111:110861.