

ANGIOGENESIS ASSESSMENT IN BASAL CELL CARCINOMA

F. SARI ASLANI* AND A. ALEDAVOOD**

From the Department of Pathology, Shiraz University of Medical Sciences, Shiraz, I.R. Iran.

ABSTRACT

Basal cell carcinoma (BCC) is currently the most common cutaneous cancer found in humans. Although it generally shows a relatively benign course (BCC1), some cases show aggressive behavior (BCC2). Until recently, traditional histologic diagnostic criteria have failed to discriminate unequivocally between BCC1 and BCC2.

In this study we selected 50 cases of BCC and categorized them into two groups (BCC1 and BCC2) on the basis of histologic criteria and then examined the rate of angiogenesis to establish if it correlates with their histological features and/or clinical behavior. The vessels were highlighted by immunohistochemical staining for factor VIII-related antigen in formalin fixed paraffin embedded tissues. All 25 cases of BCC2, whose clinical behavior was aggressive had microvessel counts significantly higher than that of the BCC1 group with mean values of 50.24 and 20.9 for BCC2 and BCC1 respectively. But there were eight cases of morphological BCC1 who had aggressive clinical behavior and interestingly had microvessel counts higher than the other cases of BCC1.

The findings of the present study seem to establish a correlation between tumor angiogenesis and clinicobiological parameters of aggressiveness.

From this point of view the assay of microvessel density might be helpful in selecting patients with BCCs at high risk for recurrence or metastasis, who could benefit from additional therapies and closer followup.

MJIRI, Vol. 15, No. 2, 73-77, 2001.

Keywords: Aggressive BCC, Non-aggressive BCC, Tumor angiogenesis.

INTRODUCTION

BCCs are the most common cutaneous tumor, and their incidence increases with age and exposure to ultraviolet rays. There are two clinicopathological types of BCC; the classic or ordinary type (BCC1) and the aggressive type (BCC2).¹⁶ These two distinct types of BCC have different histologic pictures, but there is no definite correlation between histopathological findings and clinical behavior. Consequently over the past two decades many other morphological and biological factors have been investigated. The most important factors which are

signs of aggressiveness and predict the occurrence of metastasis are the size, ulceration, local invasion and location of the lesion.¹¹ Our aim was to find an accurate prognostic indicator that correlates with outcome. Recent studies have suggested that tumor angiogenesis expressed as the microvessel density within and in areas adjacent to the tumor stroma interface significantly correlates with tumor aggressiveness and overall survival of patients with solid tumors such as breast cancer,^{2,17} invasive bladder carcinoma,⁶ germ cell neoplasm,¹² brain tumor,⁸ gastric carcinoma,⁹ endometrial carcinoma,¹ laryngeal carcinoma¹⁰ and head and neck squamous cell carcinoma.^{7,18} In this study we want to examine if there is a correlation between angiogenic rate and the histologic criteria indicative of aggressiveness and their bio-

*Assistant Professor of Pathology.

**Senior Resident of Pathology.

Angiogenesis Assessment in BCC

logical behavior including clinical appearance of the lesion, sex of the patient, invasion and recurrence.

MATERIAL AND METHODS

Selection of cases

We reviewed Hematoxylin and Eosin sections from 400 cases of cutaneous BCC surgically treated in Shiraz University affiliated hospitals from 1992 to 1999. Among these, 30 cases of BCC1 and 30 cases of BCC2 were chosen. The morphological criteria used to identify BCC2 were nuclear pleomorphism, high mitotic index, absence of cellular peripheral palisading, stromal hyalinization, and thin sheets of neoplastic cells with an irregular spiky pattern of invasion (Fig. 1). For cases to be considered as BCC2, more than two of the above criteria should be present in at least 70% of the tumor. On the contrary BCC1 cases were composed of well defined nests or organoid clusters of basaloid cells with oval or elongated pale nuclei, and typical peripheral palisade arrangement surrounded by fibrous stroma.¹⁶ The sections selected for tumor angiogenesis assessment were devoid of ulceration and granulation tissue formation. After immunohistochemical staining for factor VIII related antigen, 10 cases were excluded from the study because of unsatisfactory quality of staining. Finally 25 cases of BCC1 and 25 cases of BCC2 were evaluated for tumor angiogenesis. The medical charts were reviewed and clinical data including sex, age, site, shape, size of the lesion and follow-up were obtained.

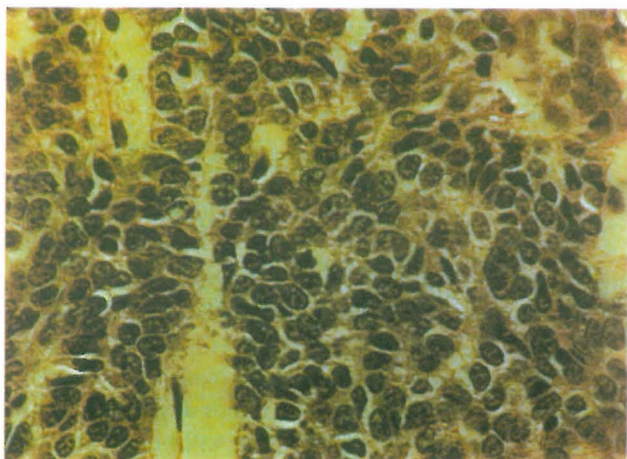


Fig. 1. BCC2, polymorphism, pleomorphism and mitosis (H&E x400).

Immunohistochemical staining procedure

Tissue preparation: For each tumor, 5 micron tissue sections were prepared from paraffin-embedded blocks, adhered to a slide by prolysin, incubated at 60°C for 30

minutes, dewaxed in xylene and brought through graded ethanols for dehydration.

Staining procedure: 1-3% H₂O₂ for 20 minutes; 2- Antigen retrieval by heating the tissue section in sodium citrate buffer solution (0.01 molar, pH= 6) inside a 98°C water bath for 20 minutes; 3- Antibody blocking solution for 20 minutes, and Triton solution for 10 minutes; 4- Predicated (1/40) antihuman vWF (DAKO A/S Productionsvej, Denmark) for 18-24 hours in the refrigerator or 3 hours at room temperature; 5- Link^a solution for 30 minutes; 6- Streptavidin peroxidase^b solution for 30 minutes; 7- DAB^c chromogen solution for 10 minutes; 8- Rinsing by Hematoxylin for background staining and mounting by Balsam. In the interval between each two successive steps rinsing in PBS^d solution was done. Positive control slides were selected from skin and liver hemangioma.

Microvessel quantitation

For microvessel quantitation, all of the slides were examined by light microscopy at low-power magnification (×10) to identify the areas with the highest number of vessels within the tumor. In each tumor, three areas of highest vascularization (hot spots) were selected. Microvessel count (MVC) was performed on 200× fields. The average of these three 200× fields was recorded. We considered inverted individual thin walled vessels and single or clusters of endothelial cells in the absence of a lumen. All of the vessels with thick muscular walls were

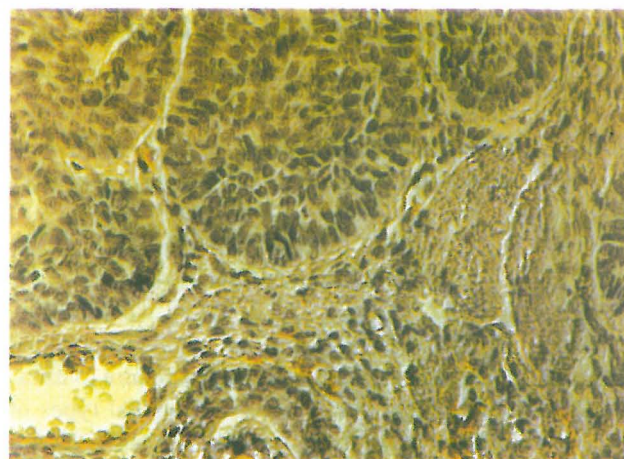


Fig. 2. BCC1, immunohistochemical staining for factor VIII related antigen, ×400.

- a- Link: Biotinylated anti-rabbit and anti-mouse immunoglobulin in phosphate buffered saline (PBS).
- b- Streptavidin peroxidase: Streptavidin conjugated to horse-radish peroxidase in PBS, containing carrier protein and an anti-microbial agent.
- c- DAB: 3,3' diaminobenzidine in chromogen solution.
- d- PBS: Phosphate buffer saline.

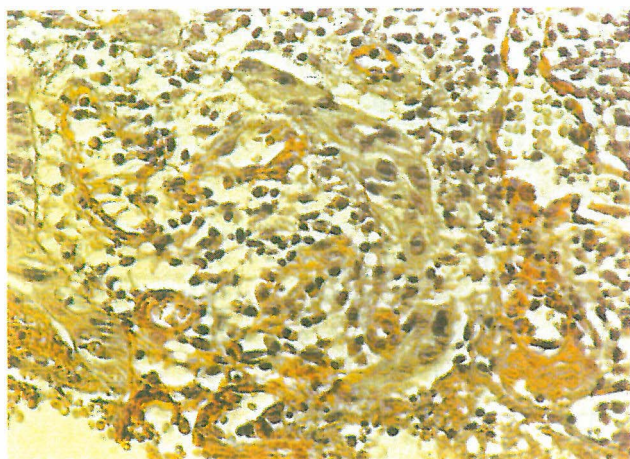


Fig. 3. BCC2, immunohistochemical staining for factor VIII related antigen, $\times 400$.

excluded and therefore only capillaries and post-capillary venules were included (Fig. 2,3). MVC was per-

formed at first by one observer and then by two observers with a double-head microscope, for an immediate interobservational control.

The observers were not aware of the clinical presentation or outcome of the cases. Only those results that had the agreement of both observers were considered for the final counts. Results were expressed both as the mean value of the highest number of microvessels identified in all the three $200\times$ fields and as the interval between the lowest and highest value in each case. The MVC of both BCC1 and BCC2 is shown in Table I.

RESULTS

Microvessel counts (MVC) for each case of BCC1 and BCC2 are shown in Table I.

The MVC in all 25 cases of BCC2 was more than 40 with a range of 40-65, mean value of 5.24 and SD of 6.72, and clinical behavior was aggressive in 22 of these cases. The clinical outcome in the remaining three cases

Table I. Microvessel count in BCC1 and BCC2 (immunohistochemical staining for Factor VIII-related antigen).

BCC1			BCC2		
Case No.	MC*	MC^	Case No.	MC*	MC^
1	13.3	13-14	1	63.3	62-65
2	57.3	55-60	2	49.6	49-50
3	39.6	38-41	3	42.3	40-44
4	27.6	26-29	4	41.6	41-42
5	18.3	16-20	5	58.0	55-61
6	50.3	49-52	6	45.3	43-47
7	39.0	38-40	7	49.6	48-51
8	22.3	20-24	8	43.0	41-45
9	50.3	48-53	9	58.3	57-60
10	24.3	24-25	10	50.6	49-53
11	25.3	23-28	11	47.3	45-49
12	49.0	48-50	12	62.0	61-63
13	12.6	11-14	13	48.6	46-51
14	18.3	17-19	14	41.3	39-43
15	57.3	56-59	15	41.3	40-42
16	16.3	16-17	16	52.3	51-54
17	18.6	17-20	17	50.3	49-52
18	25.0	24-26	18	51.6	50-53
19	22.3	20-25	19	57.3	55-60
20	48.0	46-50	20	43.0	42-44
21	25.6	25-26	21	52.3	50-54
22	11.3	10-13	22	51.0	50-53
23	29.3	28-31	23	58.6	55-61
24	27.3	25-29	24	55.0	53-58
25	18.3	16-20	25	42.3	41-44

MC*: Mean value of microvessel counts in three fields.

MC^: Range of microvessel counts in three fields.

Angiogenesis Assessment in BCC

Table II. Comparison of clinical appearance of the lesions in BCC1 and BCC2.

		BCC1	BCC2	P
Sex	M	15	18	0.37
	F	10	7	
Age		31-75	37-73	---
Site	CF	14	15	0.936
	O	8	9	
F, R, MR		11,5,1	16,11,5	0.315
Shape of lesion		P= 6 N= 12 U= 6	P=3 N= 3 U= 19	0.004
Size>3cm		3	11	0.012
Multiplicity		5	7	---

Abbreviations: CF: Central area of face, O: Other, F: Follow-up, R: Relapse, MR: Multiple relapse, P: Patch, N: Nodule, U: Ulcer.

is unknown.

The criteria for aggressiveness was relapse or ulcerative lesion and/or a size of >3 cm.

In 17 cases of BCC1 the MVC was less than 30 with a range of 10-29, mean value of 20.9 and SD of 5.56, but in eight cases the MVC was similar to BCC2 (>40); among them, 5 patients had an aggressive clinical course and the clinical outcome of 3 cases is unknown.

Clinical findings of patients in both groups are presented in Table II. There was a significant correlation between histology and size and shape of the lesion (*p*-values 0.012 and 0.004, respectively). No significant correlation was found between histology and sex, age or site of the lesion with chi-square test.

Among patients in the BCC1 group only 11 cases had follow-up and five of these had relapse, even though their lesion was completely excised in the first admission.

DISCUSSION

This study showed a significant correlation between density of microvessels in histologic sections of BCCs stained for factor VIII-related antigen and the occurrence of relapse and/or ulcerative lesions (more than 3 cm). All of the 25 cases of BCC2 had microvessel counts of >40, and the clinical course was aggressive in 22 cases (three were lost to follow up). Among 25 cases of BCC1,

there were 8 cases with microvessel counts similar to BCC2 (>40). Interestingly 5 cases of these had aggressive clinical behavior in contrast to their histologic picture. In fact, these five cases were clinically BCC2, but histologic criteria could not differentiate them as BCC2. However, in tumor angiogenesis assessment, they were categorized as BCC2. Similar to BCC2, there were 3 cases of BCC1 with microvessel counts of >40 whose clinical outcome remains unknown.

Overall the microvessel count in 22 cases of BCC2 with aggressive clinical behavior was higher than 17 cases of BCC1 with non-aggressive behavior.

There seems to be a reasonable and interesting correlation between tumor angiogenesis and clinical behavior in BCC. In a similar study¹⁶ the degree of angiogenesis was compared between two distinct groups of BCC1 and BCC2, each with 30 cases. In all 60 cases the assignment of BCC type was established by histopathologic indices, although surprisingly the clinical behavior was also shown to be in exact correlation with the assigned BCC type for each case. The investigators concluded that there was a clear-cut higher angiogenesis in all cases of BCC2 in comparison to BCC1 which in another way could be stated as greater angiogenesis in cases with aggressive behavior in comparison to cases without it.

The present study also showed a significant correla-

tion between histologic picture and morphology and size of the lesions ($p= 0.004$ and $p= 0.012$, respectively). Therefore, these two clinical data can be reliable clinical prognostic indicators.

In addition to angiogenesis assessment, several different methods including quantitative assay of AgNOR,³ extracellular matrix analysis, myofibroblastic markers⁴ and morphometric assessment⁵ may bring significant contribution in the prediction of outcome of basal cell carcinoma. Finally, among the endothelial markers, CD31 is the best for microvessel highlighting because of its high sensitivity and specificity, but as reported in several articles, factor VIII related antigen is also a perfect marker and has reliable prognostic significance.¹³⁻¹⁵

REFERENCES

1. Abulafia D, Triest WE, Shever DM: Angiogenesis in malignancies of the female genital tract. *Gynecol Oncol* 72 (2): 220-31, 1999.
2. Bosari S, Lee AKC, Delellis RA, et al: Microvessel quantitation and prognosis in invasive breast carcinoma. *J Hum Pathol* 23: 755-761, 1992.
3. De Rosa G, Staibano S, Barra E, et al: Nucleolar organizer regions in aggressive and non-aggressive basal cell carcinoma of the skin. *Cancer* 69 (1): 123-6, 1992.
4. De Rosa G, Barra E, Guarino M, et al: Fibronectin, Laminin, type IV collagen distribution and myofibroblastic stromal reaction in aggressive and non-aggressive basal cell carcinoma. *Am J Dermatopathol* 16 (3): 258-67, 1994.
5. De Rosa G, Vetrani A, Zeppa P, et al: Comparative morphometric analysis of aggressive and ordinary basal cell carcinoma of the skin. *Cancer* 65(3): 544 -9, 1990.
6. Dickinson AJ, Fox SB, Persad RA, et al: Quantification of angiogenesis as an independent predictor of prognosis in invasive bladder carcinomas. *Br J Urol* 74 (6): 762-6, 1994.
7. Eisma RJ, Spiro JD, Kreutzer DL: Role of angiogenic factors: co-expression of interleukin-8 and vascular endothelial growth factor in patients with head and neck squamous carcinoma. *Laryngoscope* 109 (5): 687-93, 1999.
8. Li VW, Folkerth RD, Watanabe H, et al: Microvessel count and cerebrospinal fluid fibroblast growth factor in children with brain tumors. *Lancet* 344 (8915): 82-6, 1994.
9. Maeda K, Chung YS, Ogawa Y, et al: Prognostic value of vascular endothelial growth factor expression in gastric carcinoma. *Cancer* 77 (5): 858-63, 1996.
10. Murray JD, Carlson GW, McLaughlin K, et al: Tumor angiogenesis as a prognostic factor in laryngeal cancer. *Am J Surg* 174 (5): 523-6, 1997.
11. Kirkham N: Tumors and cysts of the epidermis, In: Elder D, (ed.), *Histopathology of the Skin*. 8th edition, Philadelphia: Lippincott-Raven, pp. 719-731, 1997.
12. Olivarez D, Ulbright T, Deriese W, et al: Neovascularization in clinical stage A testicular germ cell tumor: prediction of metastatic disease. *Cancer Res* 54 (10): 2800-2, 1994.
13. Parums DV, Cordell JL, Micklem K, et al: A new monoclonal antibody that detects vascular endothelium associated on routinely processed tissue sections. *J Clin Pathol* 43 (9): 752-7, 1990.
14. Porschen R, Classen S, Piontek M, et al: Vascularization of carcinomas of the esophagus and its correlation with tumor proliferation. *Cancer Res* 54 (2): 587-91, 1994.
15. Ramani P, Braddey NJ, Fletcher CD, et al: A new monoclonal antibody to endothelium: assessment of its diagnostic utility in paraffin sections. *J Histopathology* 17 (3): 237-42, 1990.
16. Staibano S, Boscaino A, Salvatore G, et al: The prognostic significance of tumor angiogenesis in non-aggressive and aggressive basal cell carcinoma of the human skin. *J Human Pathology* 27: 695-699, 1996.
17. Weidner N, Semple JP, Welch WR: Tumor angiogenesis and metastasis—correlation in invasive breast carcinoma. *New Engl J Med* 324 (1): 1-8, 1991.
18. Williams JK, Carlson GW, Cohen C, et al: Tumor angiogenesis as a prognostic factor in oral cavity tumors. *Am J Surg* 168 (5): 373-80, 1994.

