

Acute urinary retention in a three years old girl: case report and review of literature

Ali Honarpisheh¹,MD., Mohammad Reza Sharif²,MD., Ahmad Talebian³,MD.,
Abbas Taghavi Ardakani⁴,MD., Homayoon Tabesh⁵,MD., Esmaeel Fakharian⁶, MD.

Department of Pediatrics, Kashan University of Medical Sciences, Tehran, Iran.

Abstract

Urinary retention, a rare childhood problem which is most commonly caused by urinary tract infection. However, neurological neoplasm must also be considered in differential diagnosis. We report here a 3 year old girl that was referred to the pediatrics department of Kashan University of Medical Sciences (KAUMS) with a history of urinary retention for 10 days. By insertion of a Foley catheter specimens obtained for urinalysis and culture, and also antibiotics were administered, but no clinical improvement encountered and the patient developed lower limbs weakness. Magnetic resonance imaging of the spine revealed an intramedullary mass lesion at located in T10 to T12. Gradual improvement appeared after surgical excision of an infected epidermoid cyst and completion of the course of antibiotics.

Keywords

Epidermoid cyst, intramedullary mass lesion, spinal cord, urinary retention.

Introduction

The urinary retention is inability to void urine voluntarily despite collection of adequate amount of urine in the bladder. In acute events the bladder may expand up to the level of umbilicus and become painful or tender on deep palpation. In chronic cases the bladder may be even more expanded without any pain. Two groups of causes are accounted for this rare childhood problem. The primary and more common causes are infections, constipation, neurological dysfunction, and adverse drug reactions, and the second and less common causes are urinary bladder neoplasm, focal inflammatory reactions, incarcerated inguinal hernia,

and idiopathic retention.

The urinary retention considered to be a rare childhood event, which could be induced by either infections or neurological disorders.

Case report

A 3 year old girl presented with acute urinary retention and dysuria. Her urinary system ultrasound study, urinalysis, and urine culture were all normal. Cefixime, phenazopyridine and diazepam and repeated catheterization of the bladder were prescribed for her but no improvement encountered. She was referred to our centre and admitted for further evaluation. She was the second child in her family with no history of considerable illness and normal developmental

1. **Corresponding author**, Associate Professor of Pediatrics, Department of Pediatrics, Kashan University of Medical Sciences, Kashan, Iran. Address; Kashan Shahid Beheshti Hospital, Ghotb-e- Ravand Ave, Iran. Tel : +980361 5308169. Email: honar_md@yahoo.com
2. Assistant Professor of Pediatrics, Department of Pediatrics, Kashan University of Medical Sciences. Kashan, Iran.
3. Professor of Pediatrics, Department of Pediatrics, Kashan University of Medical Sciences. Kashan, Iran.
4. Assistant Professor of Pediatrics, Department of Pediatrics, Kashan University of Medical Sciences. Kashan, Iran.
5. Assistant Professor of Neurosurgery, Department of Pediatrics, Kashan University of Medical Sciences. Kashan, Iran.
6. Associate Professor of Neurosurgery, Trauma Research center, Kashan University of Medical Sciences. Kashan, Iran.

milestones. She was conscious, her temperature was 38 °c, respiratory rate 24/min, BP 90/60 mmHg, PR 160/min, weight 14 Kg and 88cm height, with 50 percentile. Her urinary bladder was distended and tender on palpation, with a height of 10 cm. Abdomen was soft with no sign of organomegaly. Her genitalia, spine and neurological examination were all appeared normal.

Her CBC, ESR, CRP, BUN, creatinin, electrolytes, and urinalysis were all within the normal range. Repeated urinary system ultrasonography revealed moderate to severe bilateral hydronephrosis and some debris in the urinary bladder.

Since she was febrile, had history of repeated intermittent catheterizations and antibiotics like Ceftriaxone and Amikacin were intravenously administered and internal Foley catheter inserted for urinalysis. Despite these measures no improvement was appeared. Regular examinations showed weakness of the lower limbs and decreased DTRs. Magnetic resonance imaging of the thoracolumbar spine revealed a homogeneous intramedullary mass hypointense on T1 and hyperintense on T2 weighted images along T10 to T12 vertebrae, distorting the cord (Fig 1). The patient underwent operative decompression from T9 to L1 and pus was drained from a cystic cavity. Gram positive cocci were isolated from the specimen, and pathologic analysis showed a cyst with stratified squamous epitheliuith consistent with epidermoid cyst. Her antibiotic regimen continued and in 2 to 3 weeks her lower limbs weakness and sphincter problem improved.

Discussion

Urinary retention is a relatively rare entity in children [1,12]. In a study of two children hospitals in USA in a 6 year period 53 cases were found [1] and many different causes including infections, neurological disturbances, constipation, adverse drug reactions, local inflammatory causes, and neoplasm of urinary system were

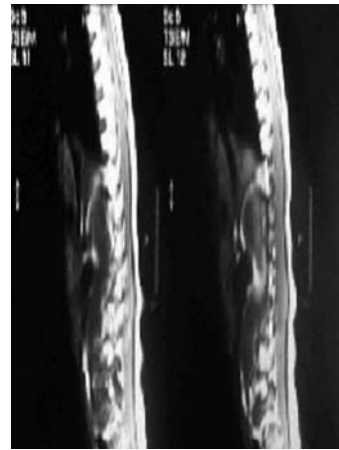


Fig1: MRI of spine of patient which revealed a non-homogenous cystic intramedullary mass from 10th to 12th vertebrae distorting the cord.

defined. There are other case reports in which acute appendicitis [5], constipation and paraparesis secondary to cauda equina syndrome [6], transverse myelitis after vaccination for measles and rubella in a 9 year old girl [7], retention after consumption of non steroidal anti-inflammatory agents [8], transverse myelitis [9], aseptic meningitis [10], and Devic optic neuromyelitis [11] have been found as the underlying cause. In another study on 86 children with urinary retention in Razi Hospital of Rasht-Iran, the most common causes were lower urinary tract stones (27.9%), neurological disorders (10.4%), trauma (10.4%), local inflammatory causes (9.1%), urinary tract infections (5.8%), ureterocele (7.4%), benign obstructive lesions (5.8%), iatrogenic (5.8%), constipation (4.6%), and imperforated hymen (3.5%).

This is the first case report of epidermoid cyst of the spinal cord causing urinary retention. Our patient had no history of lumbar puncture so the histopathological findings may indicated a congenital background of the lesion and it may be infected iatrogenically with frequent manipulations and catheterization of the urinary tract.

Conclusion

Although urinary retention is a rare finding in

children, but if it occurs serious problems such as spinal cord tumors should be considered and search must be done for even neurological abnormalities.

References

1. Verhamme KM, Dieleman JP, van Wijk MA, et al. Low incidence of acute urinary retention in the general male population; the triumph project. *Eur Urol* 2005; Apr 47 (4): 494-8 .
2. Nyman MA, Schwenk NM, Silverstein MD. Management of urinary retention ; rapid versus gradual decompression and risk of complications. *Mayo Clin Proc* 1997;Oct 72 (10) : 951-6.
3. Gatti JM,Perez - Brayfield M, Kirsch AJ et al. Acute urinary retention in children. *J Urol* 2001; Mar 165 (3) : 918-21.
4. Mikel Gray. urinary retention manegment in the acute care setting. *AJN* 2000; July vol 100 No 7.
5. Asgari SA, Mansour Ghanaie M, Simforoosh N,et al.Acute urinary retention in children. *Urol J*,2005; Winter:2(1):23-7.
6. De Paepe H, Hoebeke P, Renson C, et al. Pelvic-floor Therapy in girls with recurrent urinary tract infections and dysfunctional voiding. *Br J Urul* 1998; 81 suppl 3:109-13.
7. Peter Jr, Steinhardt Gf. Acute urinary retention in children. *Pediar Emerg Care* 1993; 9:205-7.
8. Guzel N, Eras M, Guzel DK. A chilal with spinal interamedullary abscess. *Childs Nerv Syst* 2003; 19(10-11):773-6.
9. Elmac I,Kurtkaya O, Peker S,et al. Cervical spinal cord interamedullary abscess. Case report. *J Neurosurg Sci* 2001; 45(4):213-5