

RANDOMIZED TRIAL COMPARING ROLLERBALL ABLATION WITH CUTTING LOOP ENDOMETRIAL RESECTION IN THE TREATMENT OF MENORRHAGIA

S. ALBORZI, M.D., AND M.E. PARSANEZHAD, M.D.

From the Department of Obstetrics and Gynecology, Division of Endoscopy, Shiraz University of Medical Sciences, Shiraz, I.R. Iran.

ABSTRACT

In order to compare the clinical efficacy, safety, success rate and probable complications of rollerball ablation with cutting loop endometrial resection in the treatment of menorrhagia, eighty-three women in reproductive age suffering from menorrhagia who did not respond to medication were treated in a randomized study comparing cutting loop endometrial resection with hysteroscopic rollerball ablation for treatment of menorrhagia between Sep. 1995-Aug. 1999 at Shiraz University of Medical Sciences' affiliated hospitals.

After at least twelve months of follow up, results indicated that both techniques significantly reduced menstrual blood flow with no clinically significant difference between the two groups as reflected by return to normal bleeding or less (rollerball 95% and endometrial resection 93%). Rate of amenorrhea was 20.5% in rollerball and 25% in the resection group. Rate of post-op amenorrhea, hypomenorrhea and normal menses was almost similar in both series and the method of ablation had no influence on success rate. Only five patients (6%) were considered treatment failures, two from the rollerball and three patients from the resection group. Four of these required reoperation and one patient became amenorrheic after starting medication. None of the eighty-three patients experienced intra- or postoperative complications.

Endometrial ablation by either rollerball or resection methods is therefore a successful, safe and cost-effective alternative for hysterectomy in the treatment of intractable menorrhagia.

MJIRI, Vol. 15, No. 1, 11-16, 2001.

Keywords: Endometrial ablation, Endometrial resection, Menorrhagia, Hysteroscopy.

INTRODUCTION

Menorrhagia, defined as excessive menstrual blood loss, in the later part of a woman's reproductive years, accounts for an important portion of the large number of hysterecto-

mies being performed today.¹ Hysterectomy has been the standard treatment for intractable menorrhagia for many years, but it involves not only considerable surgical risk but also significant expense.²

In recent years hysteroscopic ablation, a new therapeutic option, is increasingly accepted as a safe, cost-effective, and excellent alternative to hysterectomy. Hysteroscopic ablation has gained considerable popularity in the management of menorrhagia in current gynecologic practice.³

Correspondence: Saeed Alborzi, M.D., Associate Professor of Obstetrics and Gynecology, P.O. Box: 71345-1818, Shiraz-Iran, Fax: (+98)-711-6262225, E-mail: alborzis@sums.ac.ir

Rollerball Ablation vs. Cutting Loop Endometrial Resection

Either a laser or resectoscope with loop and rollerball electrode can accomplish ablation of the endometrium.⁴ Future, currently under investigation methods of endometrial destruction may include the non-hysteroscopic use of radio frequency, thermal transfer, hyperthermia and photodynamic therapy.⁴⁻⁶

Electrosurgical methods are the most available and currently used techniques that were studied in several aspects in this article. We compared the clinical efficacy, safety and success rate of rollerball ablation with cutting loop endometrial resection for patients with intractable menorrhagia who did not respond to medical therapy. This study was performed at Shiraz University of Medical Sciences' affiliated hospitals from September 1995 till August 1999.

MATERIAL AND METHODS

Patients were included in this study if they had a documented history of persistent menorrhagia for at least three cycles. The average age was 37.5 years old. The youngest was 25 and the oldest was 50 years old. A complete and detailed medical history and physical examination was performed. General state of health, any present illness, current medication and menstrual history were determined. All patients underwent preoperative endometrial sampling to exclude possible malignancy within the past six months. Ultrasound examination preferably with a vaginal probe was done for all patients to give additional information about uterine size, thickness of the endometrium and the presence and location of possible myomas or polyps. Of 83 patients, 14 (16.8%) had submucosal myomas and polyps were detected in 12 (14.4%). Cervical cytology was determined in all patients, and no evidence of malignancy or premalignant lesion was detected. Laboratory tests including hemoglobin and renal function tests were also performed.

We excluded those patients who had active pelvic inflammatory disease (PID), malignant or premalignant endometrial pathology, extensive uterine cavities distorted by large fibroids, or who desired to maintain fertility from this study.

Patients who met the entry criteria were randomly selected for performing endometrial resection or rollerball ablation regardless of history and physical findings. All procedures were performed in the operating room and under general anesthesia in the dorsal lithotomy position. Bimanual examination was performed. Then the cervix was exposed and grasped with a tenaculum. The uterus was sounded and if needed the cervix was dilated to 8 mm. Distending fluid was injected in the uterine cavity following insertion of the hysteroscope. The only distending media used in this study was 5% dextrose with a pump feed infusion system. Operating room personnel monitored the volume of infused fluid and collected its outflow carefully.

Rollerball electrosurgery was randomly performed in 39 patients (47%) using standard hysteroscopic equipment (Wolf or Storz, Germany). Coagulation of the endometrium was performed in a systematic manner, beginning from the fundal area. The anterior uterine wall was then coagulated followed by the lateral and subsequently the posterior wall. Nine patients (23%) had a myoma or polyp that was resected during the procedure.

Endometrial resection was performed by cutting loop in 44 patients (53%) in this manner. The area around the tubal ostia was destroyed by rollerball coagulation if it was thin. In our study none of the procedures were performed with laparoscopic guidance. Blood loss in all procedures was minimal. All patients recovered briefly and were discharged the same day or one day post operation. They were examined one week after ablation, and also every three months subsequently for evaluation of their response to treatment. Range of follow-up was between 12-36 months.

We used χ^2 test for statistical analysis and considered $p < 0.05$ as significant.

RESULTS

According to each patient's menstrual history, results were categorized to four subgroups: *Amenorrhea* (complete cessation of menstruation), *Hypomenorrhea* (scanty flow), *Normal menses* (return to routine pattern) and *Hypermenorrhea* (no improvement).

Only five (6%) of the eighty-three patients reported continuing or worsening symptoms: two from the rollerball group and three patients from the resection group. One of them (from the resection group) developed amenorrhea with Medroxyprogesterone Acetate. Four patients achieved a satisfactory result with re-ablation and one underwent hysterectomy due to treatment failure. The patient who had hysterectomy was in the rollerball series. Histologic examination of the uterus revealed atrophic endometrium.

Overall, 36 patients (43.3%) became hypomenorrheic, 19 (22.8%) amenorrheic and 23 patients (27.7%) returned to normal menstruation. Fig. 1 summarizes the results of patient follow-up interviews after endometrial resection or rollerball ablation after at least 12 months post-operation.

These results were further analyzed according to patient age, and summarized in Fig. 2. Of 42 patients under forty years old, four patients (9.5%) failed to respond. Two patients (9%) from the rollerball series and two (10%) from the resection group reported worsening or continuing of their menstrual flow. The only patient in the over-forty group who failed to respond belonged to the resection group.

These eighty-three women had three final diagnoses according to history, physical findings, sonography findings and endometrial pathologic study: dysfunctional uterine bleeding (DUB), adenomyosis, and myoma or polyp. Fig. 3 compares the outcome of the two methods in the

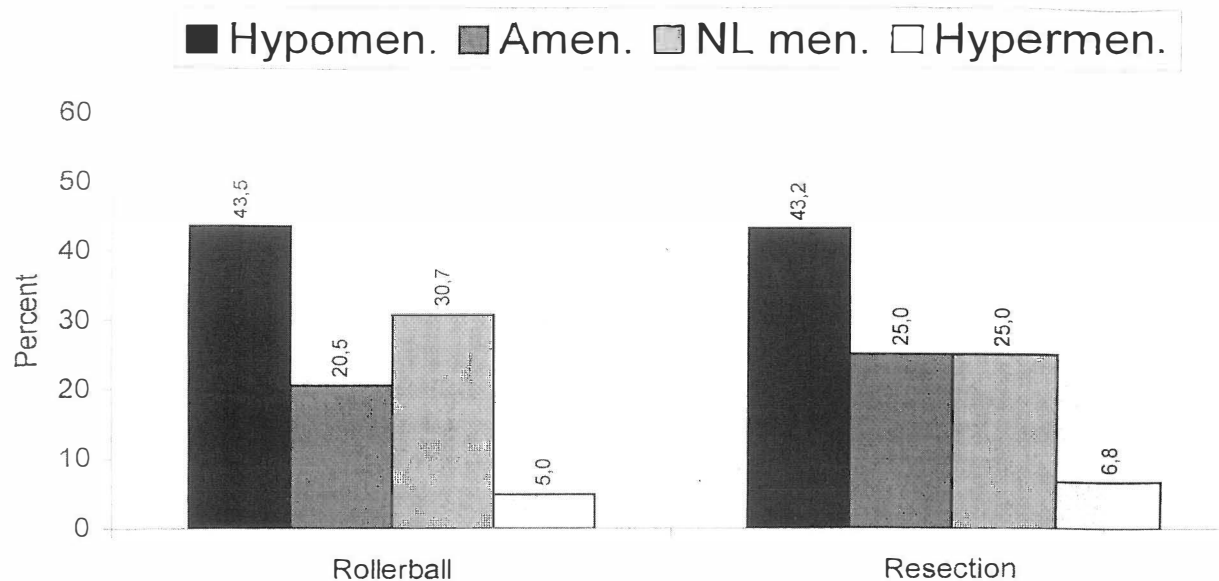


Fig. 1. Comparison between results of rollerball and resection methods in 83 patients ($p>0.05$).

above-mentioned groups.

As can be seen on the left side of this Figure, results of the two methods were compared in 41 patients with DUB. Three patients with DUB reported unresponsiveness: two (9%) out of 22 in the rollerball group plus one (5.2%) out of 19 patients in the resection group. The middle part of Fig. 3 presents these results in 16 patients with a diagnosis of adenomyosis. The unsatisfactory rate was 6.2% in the resection group. The third group was patients having a polyp or myoma, and the results of their operation is summarized on the right side of Fig. 3. Treatment failure was zero in the rollerball group as compared to one (5.8%) in the 17 patients undergoing resection. The overall unresponsive rate in patients having a myoma or polyp was 4.3% compared to 7.3% in the DUB group and 6.2% in the adenomyosis group. No significant difference was detected ($p>0.05$).

DISCUSSION

At present the use of hysteroscopic surgery using electrosurgical energy to destroy or remove the full thickness of the endometrium and superficial myometrium under direct vision has emerged as a promising technique for the treatment of menorrhagia.^{4,7} The aim of endometrial ablation is to decrease menstrual flow sufficiently to avoid hysterectomy. Endometrial ablation is followed by significantly reduced postoperative pain, hospital stay and decreased recovery period compared with hysterectomy.⁸

The one-year success rate in our study was 94%; in the same range as that reported in the literature. Depending on the definition of success, length of follow-up and operator

experience, the success rate for hysteroscopic treatment of menorrhagia has varied from 75% to 98%.^{9,10} In recent years, authors have reported better improvement rates (about 90%) in the treatment of intractable menorrhagia by endometrial ablation.^{9,11} That may be due to greater operator experience and advanced equipment.

Our success rate was 93% in resection and 95% in the rollerball group, which was comparable. We did not find a significant difference between them. This high and statistically equivalent satisfaction rate noted in both ablation methods implies that endometrial ablation is an effective alternative form of management of intractable menorrhagia regardless of the technique one uses. Comparison between different hysteroscopic ablation methods showed approximately similar success rates. Ten authors have contributed a total of 817 cases of rollerball endometrial ablation to the literature with satisfaction rates of about 96%.^{9,13} Results are linearly correlated with the amount of endometrial thermal injury.^{2,13} Rollerball ablation requires less training, and is easier and faster to do than endometrial resection.⁴ Nine authors have reported 863 cases of endometrial resection observed for one year or less. Satisfactory reduction in abnormal uterine bleeding was reported in 92% of the patients.^{14,15} In comparison of endometrial resection with rollerball ablation, the rollerball electrode permits a more complete and uniform treatment of the total endometrial surface.¹⁶ Endometrial resection with a cutting loop extensively samples the uterine cavity, provides tissue for histological evaluation and lessens the risk of undiagnosed concealing carcinoma or its precursors.¹⁷ Deep loop resection goes directly into the myometrium ensuring the removal

Rollerball Ablation vs. Cutting Loop Endometrial Resection

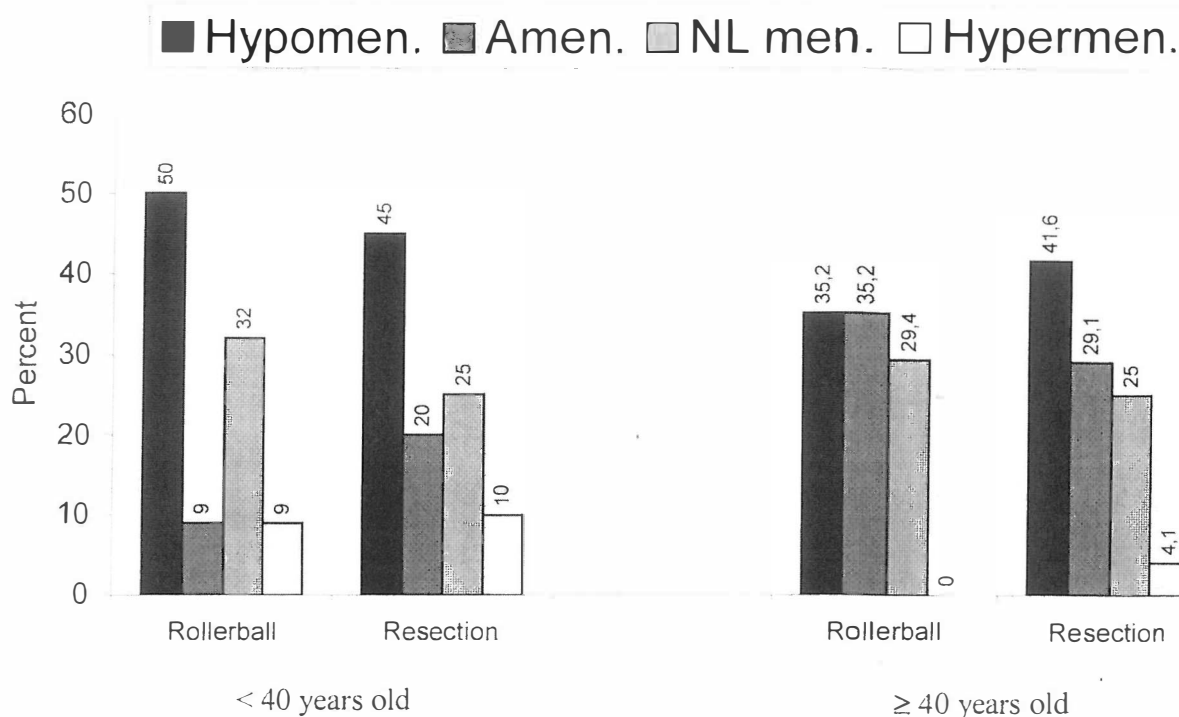


Fig. 2. Results of rollerball ablation compared to the resection method in 42 patients with age <40 years old and 41 patients with age \geq 40 years old ($p>0.05$).

and destruction of endometrial glands that inhabit the superficial myometrium.^{4,16} The rollerball can be easily used to ablate the lower uterine segment, where the fear of transecting large isthmic vessels with the cutting loop can prevent complete endometrial resection. On the other hand, the use of the cutting loop to deeply resect the endometrium requires greater hysteroscopic skill and a keen sense of intrauterine anatomy.^{4,18}

In our study four unresponsive patients were younger than forty years old and one patient was 42 years old. In patients who underwent rollerball ablation with a diagnosis of DUB, the mean age of the unresponsive group was 29 years old compared to 46 years in the amenorrhea group ($p<0.05$). In the under forty group the failure rate and amenorrhea rate were both 9% with the rollerball method compared to 10% and 20% in the resection group. In the over forty group, the failure rate was zero in the rollerball group but 4.1% in the resection group; and the amenorrhea rate was 35.2% in the rollerball group compared to 29.1% with the resection method. This difference was not statistically significant ($p>0.05$). There is general agreement that the results of hysteroscopic ablation are likely to be better in older patients.⁴ Ablation in older patients is associated with a lower failure rate and a higher amenorrhea rate, even about 90%.¹⁸⁻²⁰ It seems that the age of the patients affects the outcome, with best results in the over forty group and worst

results in the under thirty group;⁴ our results approve this issue.

The overall amenorrhea rate was 22.8% in our study; 20.5% in the rollerball method compared to 25% in the resection group. It is lower than 25%-84%, which was reported in the literature. This wide range of post-op amenorrhea is most likely related to relative power densities, duration of thermal exposure and preoperative preparations.^{12,25} Also, amenorrhea rates may vary according to patient age, and appear to be higher in patients older than 35 years.⁴ The reason for the lower amenorrhea rate in our study is not clear but may be related to younger patient age and use of lower voltage.

In this study none of the eighty-three patients experienced intra- or post-operative complications in accordance with the literature.²⁶ All of our patients were discharged within 24 hours after performing ablation with no significant difference between the two groups. In comparing probable complications in both methods, the rollerball is safer because of the blunt end of the working device.⁴ Uterine perforation causing intraoperative hemorrhage or direct thermal injury to adjacent viscera is more likely to occur with the loop technique.¹⁶ This danger is greatest at the isthmus and cornua where the thickness of the myometrium leaves little margin for error. The possibility of intravascular absorption of distending media and intraoperative hem-

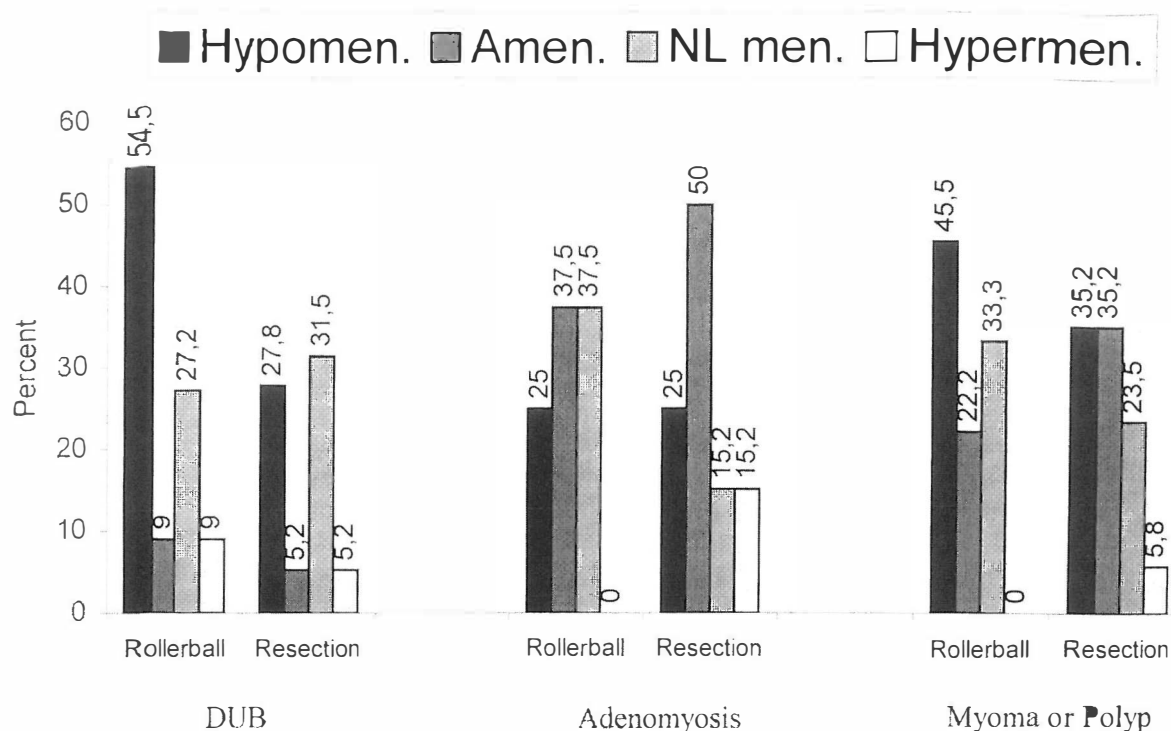


Fig. 3. Results of hysteroscopic cutting loop resection and rollerball ablation in 41 patients with DUB, 16 patients with adenomyosis and 26 patients having myoma or polyp ($p>0.05$).

orrhage potentially increases by the extensive transection of superficial vessels when the endometrium is shaved in the resection method.²⁷ Although these concerns suggest that electrosurgical loop resection of the endometrium is more difficult to do and potentially more dangerous than the rollerball technique,²⁴ we encountered no more complications in either methods.

We therefore conclude that endometrial ablation by either rollerball or cutting loop resection—when performed by a competent hysteroscopist—is associated with a high degree of success and low rate of complications.

ACKNOWLEDGEMENT

The authors wish to express their profound gratitude to Dr. P. Sahami for collecting the data and Dr. M. Eghtedari for his unfailing cooperation in technical processing and preparation of the manuscript.

REFERENCES

1. Singer A, Almanza R, Gutierrez A, et al: Preliminary clinical experience with a thermal balloon endometrial ablation method to treat menorrhagia. *Obstet Gynecol* 4: 732-4, 1994.
2. Daniell JF, Kurtz BR, Ke RW: Hysteroscopic endometrial ablation using the rollerball electrode. *Obstet Gynecol* 4: 329-31, 1992.
3. Hanjani SA, Good JA: Pyometria after endometrial resection and ablation. *Obstet Gynecol* 85: 893-4, 1995.
4. Brili AL: What is the role of hysteroscopy in the management of abnormal uterine bleeding? *Clin Obstet Gynecol* 38: 319-45, 1995.
5. Weisberg M, Goldrath MH, Berman J, et al: Hysteroscopic endometrial ablation using free heated saline for the treatment of menorrhagia. *J Am Assoc Gynecol Laparosc* 7 (3): 311-16, 2000.
6. Altebi FA, Vilos JA, Eskandar MA: Thermal balloon endometrial ablation to treat menorrhagia in high-risk surgical candidates. *J Am Assoc Gynecol Laparosc* 6 (4): 435-9, 1999.
7. Baggisgh MS, Sze HE: Endometrial ablation: a series of 568 patients treated over an 11 year period. *Am J Obstet Gynecol* 174: 907-13, 1996.
8. Wortman M, Daggett A: Hysteroscopic endomyometrial resection: a new technique for the treatment of menorrhagia. *Obstet Gynecol* 83: 295-8, 1994.
9. Vilos GA, Vilos ES, King JH: Experience with 800 hysteroscopic endometrial ablations. *J Am Assoc Gynecol Laparosc* 4: 33-8, 1996.
10. Garry R: Endometrial ablation and resection: validation of a new surgical concept. *Br J Obstet Gynecol* 104: 1329-31, 1997.
11. Serden SP, Brooks PG: Treatment of abnormal uterine bleed-

Rollerball Ablation vs. Cutting Loop Endometrial Resection

- ing with the gynecologic resectoscope. *J Reprod Med* 10: 690-97, 1991.
12. Wortman M, Daggett A: Hysteroscopic management of intractable uterine bleeding. *J Reprod Med* 38: 505-9, 1993.
 13. Townsend DE, Richart RM, Paskwitz RA, et al: Rollerball coagulation of the endometrium. *Obstet Gynecol* 76: 310-13, 1990.
 14. Magos AL, Baumann R, Lockwood T, et al: Experience with the 250 first endometrial resections for menorrhagia. *Lancet* 337: 1074-78, 1991.
 15. Nicholason SC, Slade RJ, Ahmed AIH: Endometrial resection in Oxford: first 500 cases: a five year follow-up. *Br J Obstet Gynecol* 15: 43-8, 1995.
 16. Valle RF: Rollerball endometrial ablation. *Clin Obstet Gynecol* 9: 300-15, 1995.
 17. Sinervo K, Martyn P: Endometrial stromal sarcoma diagnosed after hysteroscopic endometrial resection. *J Am Assoc Gynecol Laparosc* 7 (2): 257-9, 2000.
 18. Ke RW: Endometrial ablation: an alternative to hysterectomy. *Clin Obstet Gynecol* 40: 914-27, 1997.
 19. Taylor PJ, Gomel V: Endometrial ablation: indication and preliminary diagnostic hysteroscopy. *Clin Obstet Gynecol* 9: 251-60, 1995.
 20. Shaw RW: Introduction to menorrhagia. *Br J Obstet Gynecol* 101: 111-2, 1994.
 21. Romer T: Benefit of GnRH analogue pretreatment for hysteroscopic surgery in patients with bleeding disorders. *Gynecol Obstet Invest* 47: 12-20, 1998.
 22. Romer T, Schwesinger G: Hormonal inhibition of endometrium for transcervical endometrial ablation—a prospective study with a 2 year follow-up. *Eur J Obstet Gynecol Reprod Biol* 74: 201-3, 1997.
 23. Nathanson HG, Phillips DR, Milim SJ: Relationship of endometrial thickness with the menstrual timing of leuprolide acetate administration for preoperative preparation for hysteroscopic surgery. *J Am Assoc Gynecol Laparosc* 4: 190-4, 1997.
 24. Yin CS, Wei RY, Chao TC: Hysteroscopic endometrial ablation without endometrial preparation. *Int J Obstet Gynecol* 62: 167-72, 1998.
 25. Wood C, Hurley VA, Leoni M: The value of vaginal ultrasound in the management of menorrhagia. *Aust NZJ Obstet Gynecol* 33: 198-200, 1993.
 26. Propts AM, Liberman RF, Harlow BL, et al: Complications of hysteroscopic surgery: predicting patient risk. *Obstet Gynecol* 96 (4): 517-20, 2000.
 27. Garry R: Good practice with endometrial ablation. *Obstet Gynecol* 85: 144-51, 1995.