


Efficacy of Dry Needling in Treating Scars following Total Hip Arthroplasty: A Case Report

Mehrdad Bahramian^{1,2}, Narges Dabbaghipour^{3*}, Amir Aria⁴, Bahareh Sajadi moghadam fard tehrani⁵, Jan Dommerholt^{6,7,8}

Received: 4 Jun 2022

Published: 20 Dec 2022

Abstract

Background: In this case report of a 31-year-old female, we describe the effects of dry needling on scar tissue following total hip arthroplasty.

Case report: A 31-year-old woman underwent an elective bilateral total hip replacement due to a motor vehicle accident. Based on physical examination, the patient had burning pain at the incision site at the time of menstruation and limited hip range of motion worse on the right side. The treatment program consisted of six sessions of dry needling over a three-week period alongside infrared radiation for 20 minutes during each session. The needles were spaced along the entire length of the scar tissue and rotation was performed back and forth across the scar region to release the adhesion between the scar line and the underlying tissue, focusing more on the painful-to-touch spots and adhesive points. Following the completion of the dry needling treatments hip range of motion and the patient's functional outcome improved. Dry needling may be an effective and rapid treatment for scar tissue adhesion after surgical procedures. High-quality randomized-controlled studies are needed to verify the efficacy of this method.

Keywords: Dry Needling, Hypertrophic scar, Total hip arthroplasty, Scar treatment, Scar adhesion

Conflicts of Interest: None declared

Funding: None

***This work has been published under CC BY-NC-SA 1.0 license.**

Copyright© Iran University of Medical Sciences

Cite this article as: Bahramian M, Dabbaghipour N, Aria A, Sajadi moghadam fard Tehrani B, Dommerholt J. Efficacy of Dry Needling in Treating Scars following Total Hip Arthroplasty: A Case Report. *Med J Islam Repub Iran*. 2022 (20 Dec);36:156. <https://doi.org/10.47176/mjiri.36.156>

Introduction

Total hip arthroplasty (THA), or surgical replacement of the hip joint with an artificial prosthesis, is an increasingly common treatment in patients suffering from severe osteoarthritis (1). Also, arthroplasty could be a surgical option in the emergency setting for patients with hip fractures

(2). Over 1 million arthroplasty procedures are performed each year in the United States, and the annual incidence has been increasing (3). The purpose of THAs is to relieve pain, improve quality of life, and increase physical activity levels. (4, 5).

Corresponding author: Narges Dabbaghipour, n-dabbaghipour@razi.tums.ac.ir

¹ Department of Physiotherapy, School of Rehabilitation, Iran University of Medical Sciences, Tehran, Iran

² Department of Physical Therapy, College of Health Science & Professions, University of North Georgia, Dahlonega, USA

³ Department of Physiotherapy, School of Rehabilitation, Tehran University of Medical Sciences, Tehran, Iran

⁴ Department of Physiotherapy, School of Rehabilitation, Jondishapur University of Medical Sciences, Ahvaz, Iran

⁵ Department of Physiotherapy, School of Rehabilitation, Shahid Beheshti University of Medical Sciences, Tehran, Iran

⁶ Bethesda Physiocare, Bethesda, MD, USA

⁷ Myopain Seminars, Bethesda, MD, USA

⁸ Department of Physical Therapy and Rehabilitation Science, School of Medicine, University of Maryland, Baltimore, MD, USA

↑What is “already known” in this topic:

Hypertrophic scars following hip arthroplasty are a common complication that is characterized by myofascial adhesion, burning pain, muscle imbalance, and limited knee Range of motion. Therefore, it can affect the patient's abilities and performance in daily living.

→What this article adds:

It seems that dry needling has a positive effect on the characteristics and appearance of the scar tissue. Applying mechanical stress by inserting and rotating a needle into tissue adhesions could stimulate collagen fiber formation along the normal alignment and increase tissue flexibility.

One of the most common postoperative complications of THA is arthrofibrosis, which is characterized by the production of excessive fibrous scar tissue near the joint (6). The hypertrophic scar is thought to result from abnormal responses to trauma or surgical procedures and is characterized by an over-proliferation of fibroblasts and excessive collagen deposits (7, 8).

Although the etiology of the scar is unclear, several risk factors have been identified. It appears that the type of trauma, wound size and depth, infection, immobility, and previous history of surgery could increase the risk of scar tissue after THA (9-11). Patients often present with symptoms, including pain, tenderness, hard texture, numbness, or burning sensations (12). The main clinical feature of arthrofibrosis is loss of range of motion due to painful, stiff scar tissue, which affects the patient's quality of life and functional ability (13).

Current treatment strategies for hypertrophic scars are surgical manipulations, topical and intralesional corticosteroid injections, laser therapy, silicone gel sheeting, drug therapy, and radiotherapy (14-16). There are only a few clinical studies of the effect of acupuncture and dry needling (DN) on scar tissue (17, 18). DN is an invasive technique used by an increasing number of physical therapists to treat patients with pain and dysfunction (19). Several studies have shown that DN can decrease the intensity of pain and muscle stiffness, alter peripheral nociceptive input and improve the range of motion (20, 21). The purpose of this case report is to describe the efficacy of scar needling on pain, range of motion, and functional ability after THA surgery.

Case Description

A 31-year-old woman (height: 166 cm, weight: 57 kg) with bilateral intertrochanteric fractures due to a high-velocity motor vehicle accident received a right-sided THA using a posterolateral approach in December 2021. One month after the THA, she presented with increased pain and restriction of movement in her left hip in spite of medical and physical therapy treatments. Based on these findings, a second surgery on the left side was conducted eight months after the first procedure. The patient had no past pertinent medical history or underlying diseases.

Two months after an operation on the left side, she was admitted to the orthopedic physical therapy clinic with severe burning pain, numbness in the right scar line, and intermittent claudication in both limbs. She underwent 20 physical therapy treatment sessions for the hips and lumbar spine, which included conventional TENS (frequency: 70 Hz, pulse width: 50 μ s, Time: 20 min), ultrasound (frequency: 3-MHz, intensity: 1.8 W/cm², time: 5 min), exercise therapy including hip stretching exercise, passive range of motion exercises and isometric hip abductor strengthening (2 sets of 15 repetitions, 2 times a day). However, due to the lack of complete recovery, the patient has again been referred to our research group by the surgeon.

Clinical finding

Physical examination showed that both surgical areas

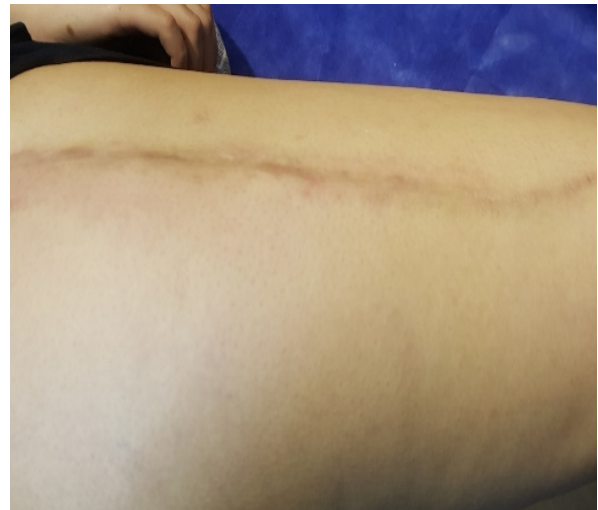

Fig. 1. The postoperative scar after right THA

featured similar large mature scars resulting in loss of hip ROM. Also, the patient complained of neuropathic pain, during which the pain was continuous with spontaneous attacks of stabbing pains in the scar area, and palpation of the scar painful in joint line areas, defined as allodynia. The longitudinal scar on the right side was about 51 cm long, 4.8 cm wide, pink in color, tough, and very sensitive to touch (Fig. 1). Also, the length and width of the scar on the left side were 38 cm and 3.6 cm, respectively. All outcome measurements were assessed by the second physiotherapist before and after the treatment. Postoperative ROM was assessed with a long-legged goniometer according to a standardized procedure (22). All six-movement directions of the hip were measured. The hip muscle strength was determined for each muscle group separately for each leg by manual muscle testing (MMT). Based on manual testing, the average hip muscle strength was considered good (4/5). Hip joint and surgical line pain levels were evaluated with a visual analog scale (VAS) before and after the treatment (23). Also, the patient completed two functional assessment tests to evaluate mobility and balance, namely the Timed Up-and-Go test and a 30-second chair-stand test (24, 25). The patient completed the 36-Item Short-Form Health Survey questionnaire (SF-36) before and after the treatment (26).

Treatment

Burning pain, intermittent claudication due to scar tissue, and lack of effectiveness of routine physiotherapy treatment led to the choice of alternative therapy for the patient. It seems that adhesions of scar tissue can be treated effectively by placing a needle directly into the scar tissue and creating mechanical stress, which may restore the scar's mobility and sensation. So the treatment aimed to improve scar features, skin layers mobility and hip range of motion. During the scar tissue DN, the patient was placed in the side-lying position. A skilled, trained physical therapist with 11 years of DN experience inserted a filiform needle (0.30 x 50 mm, Dong Bang Acupuncture Inc., Kyunggi-do, Korea) underneath the scar area and moved the needle back and forth to potentially alter the

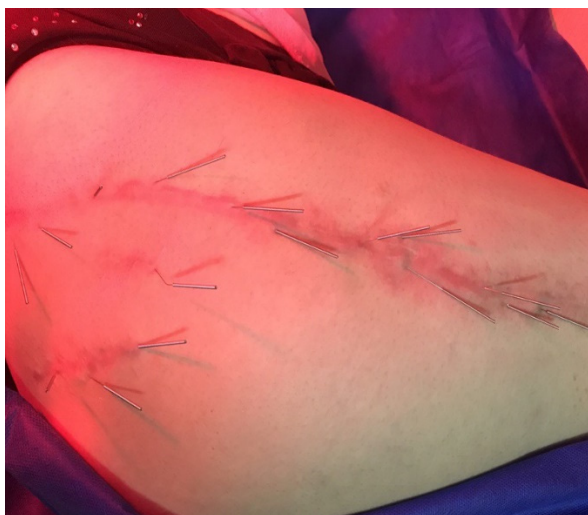

Fig. 2. DN of the scar in the right hip

adhesion. The therapist placed other needles (0.25 x 25 mm, Dong Bang Acupuncture Inc., Kyunggi-do, Korea) above the proximal border of the scar band at a 15 to 30 degrees perpendicular to the tissue surface in a vertical line and gently rotated the needles back and forth. In addition, infrared radiation was applied for 20 minutes at a distance of 40 cm from the patient's body to improve regeneration and facilitate scar tissue regeneration (Fig. 2). Needles were manipulated and rotated 2–3 times during the session. Treatments were performed twice a week for 3 continuous weeks with 30 minutes each time.

The score on the Timed Up-and-Go test, 30-second chair-stand test, was assessed. Also, according to the SF-36 questionnaire, scar tissue needling was effective in improving the quality of life. It is noteworthy that the patient was very satisfied with her improvement. The final results are summarized in Table 1.

Discussion

Despite the favorable clinical and functional outcomes of a THA, adhesive scars are a common postoperative

complication, potentially resulting in burning pain, tenderness, numbness, stiffness, itchiness, reduced range of motion, and decreased function with psychological and social barriers (27).

Several methods have been developed for the treatment of scar tissue, but finding the most effective treatment is still a major challenge for therapists. It seems that several variables, such as duration of scar, skin type, and age, should be considered.

The current case report showed that a specific scar tissue DN technique had a positive effect on the characteristics and appearance of the scar, the patient's pain level, and the hip's range of motion following hip replacement surgery. Progressively, the patient's symptoms improved throughout the treatment sessions. She increased her ambulation distance without claudication and improved her single-leg balance based on the Timed Up-and-Go test result.

Many studies have examined the wound-healing process and morphological properties of scar tissue. Among these, the main difference between scar tissue and normal skin is the density, fiber size, and orientation of the collagen fibrils (28, 29). Collagen is the most abundant protein found throughout the body and during the healing wound process, they are synthesized by fibroblast cells (30). It seems that creating a superficial post-traumatic dermal inflammation over the scar area induces the wound-healing inflammatory cascade, and the scar collagen that is broken down is replaced with new collagen type 3 under the epidermis (31, 32). It is expected that such damage could reduce scar thickness and improve the appearance of scarred skin. Although, achieving maximum tissue changes requires more than 8 weeks. (33).

Even though the underlying mechanisms of scar tissue DN are not fully understood, applying mechanical stress by inserting and rotating a filament needle into scar tissue and fascial adhesions could stimulate fibroblasts and myofibroblasts activity, increase dermal elastin and collagen, and encourage the realignment of collagen bundles to the direction of stress (34, 35). Especially using treatment techniques such as soft tissue mobilization and exercise

Table 1. Characteristics of outcome measures

Outcome measurement		Before treatment	After treatment
VAS		8/10	3/10
	Flexion	Rt.: 4/5 - Lt: 4 ⁺ /5	Rt.: 5/5 - Lt: 5/5
MMT	Extension	Rt.: 4/5 - Lt: 4/5	Rt.: 5/5 - Lt: 5/5
	Abduction	Rt.: 4/5 - Lt: 4/5	Rt.: 4 ⁺ /5 - Lt: 4 ⁺ /5
	Adduction	Rt.: 4/5 - Lt: 4/5	Rt.: 5/5 - Lt: 5/5
	External rotation	Rt.: 4/5 - Lt: 4/5	Rt.: 5/5 - Lt: 5/5
	Internal rotation	Rt.: 4/5 - Lt: 4/5	Rt.: 5/5 - Lt: 5/5
Timed Up-and-Go test		7:49 seconds	5:19 seconds
30-second chair-stand test		8 repetitions	12 repetitions
Hip ROM	Flexion	Rt.: 102° - Lt: 123°	Rt.: 120° - Lt: 125°
	Extension	Rt.: 25° - Lt: 25°	Rt.: 35° - Lt: 25°
	Abduction	Rt.: 61° - Lt: 68°	Rt.: 65° - Lt: 70°
	Adduction	Rt.: 55° - Lt: 50°	Rt.: 55° - Lt: 50°
	External rotation	Rt.: 35° - Lt: 28°	Rt.: 47° - Lt: 40°
SF-36	Internal rotation	Rt.: 23° - Lt: 40°	Rt.: 42° - Lt: 50°
	Physical functioning	40%	65%
	Emotional well-being	44%	56%
	Social functioning	37.5%	62.5%

ROM: Range Of Motion; VAS: Visual Analogue Scale; MMT: Manual Muscle Test; SF-36: 36-Item Short-Form Health Survey questionnaire

some after the DN can reorganize the collagen directions in selective alignment and thus increase tissue stability.

Persistent adhesions are likely linked to a dysregulation of extracellular matrix proteins. Cyclically stretching fibroblasts may facilitate the transcription of the tenascin-C gene, impact fibronectin and collagen, and modify integrins, which are important for mechanical force patterning (36). The increased fibroblastic activity appears to accelerate tissue healing. DN can improve microcirculation, muscle blood flow, and oxygenation of tissues (37, 38).

In addition, increasing the nerve density in and around the scar tissue during wound healing leads to an itching sensation (39). The DN stimulates mechanoreceptors and nociceptors in the skin and underlying tissue and enhances the activity of inhibitory neural mediators, thereby modulating neurogenic inflammation (40). Therefore, DN may alter their viscoelastic properties, improve tissue mobility and pliability, and reduce hyperalgesia and allodynia (19, 41).

However, the lack of sufficient studies about the efficacy of needles in surgical scars and some similarities between DN and the micro-needling (MN) technique led to evaluating the previous studies in that field. In a systematic review, Sitohang et al. maintain that MN is an effective therapeutic modality in atrophic acne scars, and it can improve scar appearance (42).

According to another systematic review, using the MN technique could improve patients' clinical symptoms with a high level of patient satisfaction in many types of scars, including acne, hypertrophic, and post-operative or post-traumatic scars (43). However, differences in the depth of needle penetration between the two techniques might lead to different therapeutic results in scar tissue. Consequently, the MN findings should not be generalized to the DN technique.

Conclusion

In conclusion, this case report indicates that DN could be employed as a successful and effective method in the treatment of problematic or surgical scars. Treatment should be applied twice a week for more than three continuous weeks. Needles should be inserted around the scar angled 30–45° toward the skin, and be left in tissue for 20 minutes. Also, the combination of DN and IR appears to be another cost-effective modality for patients suffering from scar adhesions. Besides, changing the biomechanical properties by removing the tissue adhesion can improve skin mobility and function. We would recommend that long scars have fewer treatment sessions or a longer time interval between sessions. Because the long lateral scar could increase frontal-plane stability and the snap tissue release in the short term can increase pain and decrease the patient's balance. However, future research with high-quality evidence and a larger sample size is recommended to further evaluate this treatment.

Acknowledgments

The authors would like to thank the participating patient and colleagues who made this report possible.

Conflict of Interests

The authors declare that they have no competing interests.

References

- Papalia R, Campi S, Vorini F, Zampogna B, Vasta S, Papalia G, et al. The role of physical activity and rehabilitation following hip and knee arthroplasty in the elderly. *J Clin Med*. 2020;9(5):1401.
- Coomber R, Porteous M, Hubble MJ, Parker MJ. Total hip replacement for hip fracture: surgical techniques and concepts. *Injury*. 2016;47(10):2060-4.
- Kremers HM, Larson DR, Crowson CS, Kremers WK, Washington RE, Steiner CA, et al. Prevalence of total hip and knee replacement in the United States. *J Bone Jt Surg*. volume. 2015;97(17):1386.
- Ewen AM, Stewart S, Gibson ASC, Kashyap SN, Caplan N. Post-operative gait analysis in total hip replacement patients—a review of current literature and meta-analysis. *Gait Posture*. 2012;36(1):1-6.
- Gogia PP, Christensen CM, Schmidt C. Total hip replacement in patients with osteoarthritis of the hip: improvement in pain and functional status. *Orthopedics*. 1994;17(2):145-50.
- Flick TR, Wang CX, Patel AH, Hodo TW, Sherman WF, Sanchez FL. Arthrofibrosis after total knee arthroplasty: patients with keloids at risk. *J Orthop Traumatol*. 2021;22(1):1.
- Atiyeh BS. Nonsurgical management of hypertrophic scars: evidence-based therapies, standard practices, and emerging methods. *Aesthetic Plast Surg*. 2007;31(5):468-92.
- Gauglitz GG, Korting HC, Pavicic T, Ruzicka T, Jeschke MG. Hypertrophic scarring and keloids: pathomechanisms and current and emerging treatment strategies. *Mol Med*. 2011;17(1):113-25.
- CRAWFORD RW, Murray D. Total hip replacement: indications for surgery and risk factors for failure. *Ann Rheum Dis*. 1997;56(8):455-7.
- Butzelaar L, Ulrich M, Van Der Molen AM, Niessen F, Beelen R. Currently known risk factors for hypertrophic skin scarring: A review. *J Plast Reconstr Aesthet Surg*. 2016;69(2):163-9.
- Niessen FB, Spauwen PH, Schalkwijk J, Kon M. On the nature of hypertrophic scars and keloids: a review. *Plast Reconstr Surg*. 1999;104(5):1435-58.
- Fang S. The successful treatment of pain associated with scar tissue using acupuncture. *J Acupunct Meridian Stud*. 2014;7(5):262-4.
- Solanki RB, Bhise AR. Arthrofibrosis following total knee arthroplasty. *Int J Physiother Res*. 2014;2(6):762-65.
- Chowdri NA, Mattoo MMA, Darzi MA. Keloids and hypertrophic scars: results with intra-operative and serial postoperative corticosteroid injection therapy. *ANZ J Surg*. 1999;69(9):655-9.
- Leclere F, Mordon SR. Twenty-five years of active laser prevention of scars: what have we learned? *J Cosmet Laser Ther*. 2010;12(5):227-34.
- Slemp AE, Kirschner RE. Keloids and scars: a review of keloids and scars, their pathogenesis, risk factors, and management. *Curr Opin Pediatr*. 2006;18(4):396-402.
- Tuckey C, Kohut S, Edgar DW. Efficacy of acupuncture in treating scars following tissue trauma. *Scars Burn Heal*. 2019;5:2059513119831911.
- Rozenfeld E, Sapoznikov Sebakhtu E, Krieger Y, Kalichman L. Dry needling for scar treatment. *Acupunct Med*. 2020;38(6):435-9.
- Dunning J, Butts R, Mourad F, Young I, Flannagan S, Perreault T. Dry needling: a literature review with implications for clinical practice guidelines. *Phys Ther Rev*. 2014;19(4):252-65.
- Dommerholt J. Dry needling—peripheral and central considerations. *J Man Manip Ther*. 2011;19(4):223-7.
- Maher RM, Hayes DM, Shinohara M. Quantification of dry needling and posture effects on myofascial trigger points using ultrasound shear-wave elastography. *Arch Phys Med Rehabil*. 2013;94(11):2146-50.
- Holm I, Bolstad B, Lütken T, Ervik A, Røkkum M, Steen H. Reliability of goniometric measurements and visual estimates of hip ROM in patients with osteoarthritis. *Physiother Res Int*. 2000;5(4):241-8.
- Boonstra AM, Preuper HRS, Reneman MF, Posthumus JB, Stewart RE. Reliability and validity of the visual analogue scale for disability in patients with chronic musculoskeletal pain. *Int J Rehabil Res*. 2008;31(2):165-9.
- Dobson F. Timed Up and Go test in musculoskeletal conditions. *J Physiother*. 2014;61(1):47-.

25. Jones CJ, Rikli RE, Beam WC. A 30-s chair-stand test as a measure of lower body strength in community-residing older adults. *Res Q Exerc Sport*. 1999;70(2):113-9.
26. Turk DC, Melzack R. *Handbook of pain assessment*: Guilford Press; 2011.
27. Bayat A, McGrouther D, Ferguson M. Skin scarring. *BMJ*. 2003;326(7380):88-92.
28. Dale PD, Sherratt JA, Maini PK. A mathematical model for collagen fibre formation during foetal and adult dermal wound healing. *Proc Royal Soc B*. 1996;263(1370):653-60.
29. Lin TW, Cardenas L, Soslowsky LJ. Biomechanics of tendon injury and repair. *J Biomech*. 2004;37(6):865-77.
30. Mathew-Steiner SS, Roy S, Sen CK. Collagen in Wound Healing. *Bioengineering*. 2021;8(5):63.
31. Fernandes D. Percutaneous collagen induction: an alternative to laser resurfacing. *Aesthet Surg J*. 2002;22(3):307-9.
32. Volk SW, Wang Y, Mauldin EA, Liechty KW, Adams SL. Diminished type III collagen promotes myofibroblast differentiation and increases scar deposition in cutaneous wound healing. *Cells Tissues Organs*. 2011;194(1):25-37.
33. Aust MC, Knobloch K, Reimers K, Redeker J, Ipaktchi R, Altintas MA, et al. Percutaneous collagen induction therapy: an alternative treatment for burn scars. *Burns*. 2010;36(6):836-43.
34. Fox JR, Gray W, Koptiuch C, Badger GJ, Langevin HM. Anisotropic tissue motion induced by acupuncture needling along intermuscular connective tissue planes. *J Altern Complement Med*. 2014;20(4):290-4.
35. Langevin HM, Storch KN, Snapp RR, Bouffard NA, Badger GJ, Howe AK, et al. Tissue stretch induces nuclear remodeling in connective tissue fibroblasts. *Histochem Cell Biol*. 2010;133(4):405-15.
36. Chiquet M, Renedo AS, Huber F, Flück M. How do fibroblasts translate mechanical signals into changes in extracellular matrix production? *Matrix Biol*. 2003;22(1):73-80.
37. Loaiza LA, Yamaguchi S, Ito M, Ohshima N. Electro-acupuncture stimulation to muscle afferents in anesthetized rats modulates the blood flow to the knee joint through autonomic reflexes and nitric oxide. *Auton Neurosci*. 2002;97(2):103-9.
38. Kubo K, Yajima H, Takayama M, Ikebukuro T, Mizoguchi H, Takakura N. Effects of acupuncture and heating on blood volume and oxygen saturation of human Achilles tendon in vivo. *Eur J Appl Physiol*. 2010;109(3):545-50.
39. Hamed K, Giles N, Anderson J, Phillips JK, Dawson LF, Drummond P, et al. Changes in cutaneous innervation in patients with chronic pain after burns. *Burns*. 2011;37(4):631-7.
40. Cuignet O, Pirlot A, Ortiz S, Rose T. The effects of electroacupuncture on analgesia and peripheral sensory thresholds in patients with burn scar pain. *Burns*. 2015;41(6):1298-305.
41. Dommerholt J, de las Penas CF. *Trigger Point Dry Needling E-Book: An Evidence and Clinical-Based Approach*: Elsevier Health Sciences; 2018.
42. Sitohang IBS, Sirait SAP, Suryanegara J. Microneedling in the treatment of atrophic scars: A systematic review of randomised controlled trials. *Int Wound J*. 2021;18(5):577-85.
43. Juhasz ML, Cohen JL. Microneedling for the treatment of scars: an update for clinicians. *Clin Cosmet Investig Dermatol*. 2020;13:997.