

INVASIVE GASTRIC MUCORMYCOSIS: REPORT OF A CASE AND REVIEW OF THE LITERATURE

B. GERAMIZADEH AND S. AZIZI

From the Department of Pathology, Shiraz University of Medical Sciences, Shiraz, I.R. Iran.

ABSTRACT

Invasive gastric mucormycosis is a rare and fatal disease. We report a rare case with longstanding SLE who presented with fever. Autopsy showed multiple small shallow-based ulcers in the antrum. Histologic examination showed invasive mucormycosis. This is a rare case of invasive gastric mucormycosis localized exclusively in the stomach.

MJIRI, Vol. 14, No. 4, 397-398, 2001.

Keywords: Stomach, mucormycosis, immunocompromised patients, gastric ulceration.

INTRODUCTION

Invasive gastric mucormycosis is a rare and fatal disease, seen only in severely debilitated patients.¹ The disease presents with variable signs and symptoms, such as gastric ulcer,² gastritis³ and gastric perforation.⁴ The majority of the reported cases have been fatal⁵ except for a few which had received antifungal drugs on an early diagnosis.^{6,7}

CASE REPORT

A 63 year old female, a known case of SLE, presented with low grade fever. She had been on prednisolone (10 mg/day) for several years. The only positive finding related to the GI tract was 1+ occult blood in the stool. The patient developed spontaneous bruising and bleeding from venipuncture sites. She became confused and died with cardio-respiratory arrest.

Complete autopsy was performed to investigate the cause of death. On postmortem study there were multiple (~10) small shallow-based circular ulcers in the antrum. Microscopic examination of the mucosal ulcerations revealed numerous mucor hyphae. There was massive tissue and vascular invasion (Fig. 1). Multiple sections of other organs were surprisingly negative for fungal infection.

DISCUSSION

Mucormycosis has been described in most sites of the body.⁸ Gastrointestinal variants are rare and most of the previous reports are from Africa.² It can be seen in the

esophagus, stomach and intestine.^{9,10} The stomach can be involved by mucor as colonization, infiltration and invasion.² The two former may be seen as isolated gastric involvement in various conditions such as peptic ulcer and even in normal healthy persons.² But invasive gastric mucormycosis is rare and fatal, seen only in severely debilitated or immunocompromised patients.¹ The majority of reported cases have been in kidney^{5,7,9} and heart^{4,6,11} transplants. The other rare cases have been reported in myelodysplastic syndrome,¹² diabetes,¹³ AIDS¹⁴ and one report in a young woman, a known case of SLE.¹⁵ There are three reported cases in the pediatric age group,¹⁶ two of which had lymphoma and leukemia and the last one was a premature infant.¹⁶ The patients presented with variable signs and symptoms, i.e., gastric ulcer,² severe gastritis,³

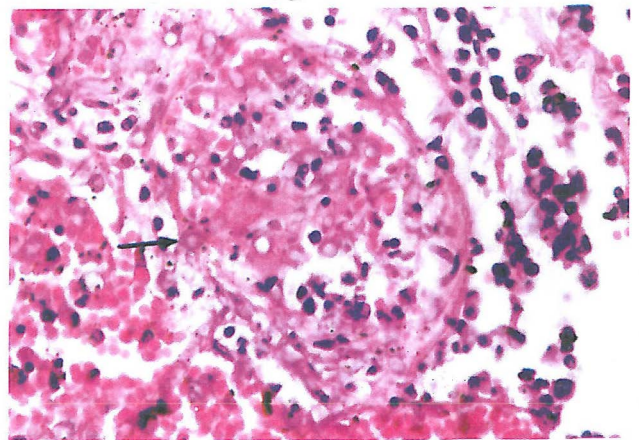


Fig. 1. Microscopic view of vascular invasion of mucor in gastric wall (arrow, H&E, ×400).

Invasive Gastric Mucormycosis

gastric perforation,⁴ emphysematous gastritis³ and acute abdomen.¹⁶ The majority (98%) of the reported cases were fatal⁵ except for a few which had received antifungal drugs on an early diagnosis.^{6,7}

Our case is rare in the mode of presentation (fever) and we assume that the stomach was the primary route of entry.

REFERENCES

1. Goldman H: Gastritis. In: Ming Si C, Goldman H, (eds.), Pathology of Gastrointestinal Tract, 2nd edition, Baltimore: Williams and Wilkins, pp. 439, 545, 666, 1998.
2. Thomson SR, Bade PG, et al: Gastrointestinal mucormycosis. Br J Surg 78(8): 952, 1991.
3. Cherney CL, Chutuape A, et al: Fatal invasive gastric mucormycosis occurring with emphysematous gastritis, case report and review of literature. Am J Gastroenterol 94(1): 252, 1999.
4. Knoop C, Antoine M, et al: Gastric perforation due to mucormycosis after heart-lung transplant and heart transplantation. Transplantation 66(7): 932, 1998.
5. Winkler S, Susani S, et al: Gastric mucormycosis due to *Rhizopus oryzae* in a renal transplant recipient. J Clin Microbiol 34(10): 2585, 1996.
6. Corley DA, Lindeman N, et al: Survival with early diagnosis of gastric mucormycosis in a heart transplant patient. Gastrointest Endos 46(5): 425, 1997.
7. Martinez EJ, Cancio MR, et al: Nonfatal gastric mucormycosis in a renal transplant recipient. South Med J 90(3): 34, 1997.
8. Meyer RD, Armstrong D: Mucormycosis-changing status. Cri Rev Cli Lab Sci 4: 421, 1973.
9. Sheu BS, Lee PC, et al: A giant gastric ulcer caused by mucormycosis infection in a patient with renal transplantation. Endoscopy 30(5): 360, 1998.
10. Foroutan H, Nayer H, Mashayekhi NR: Zygomycosis of colon, case report and review of literature. MJIRI 11(1): 53-55, 1997.
11. Barroso F, Forcelledo JL, et al: A fatal case of gastric mucormycosis in a heart transplant recipient. Endoscopy 31(2): 32, 1999.
12. Sasaki A, Tsukaguchi M, et al: Myelodysplastic syndrome developing acute myelocytic leukemia with gastric mucormycosis. Rinsho-Byori 41(9):1054, 1993.
13. Danheimer IP, Fouch W, et al: Gastric mucormycosis occurring with emphysematous gastritis, case report and review of literature. Am J Gastroenterol 94(1):252, 1999.
14. Bullet-E, Andreu-X, et al: Gastric mucormycosis in a patient with acquired immunodeficiency syndrome (letter). Gastrointest Endos 39(1):106, 1993.
15. Bloxham CA, Carr S, et al: Disseminated zygomycosis and systemic lupus erythematosus (clinical conference). Intensive Care Med 16(31): 201, 1990.
16. Vadeboncoeur C, Walton JM, et al: Gastrointestinal mucormycosis causing an acute abdomen in the immunocompromised patient - three cases. J Pediatric Surg 29(9): 1248, 1994.