

EVALUATION OF ANATOMICAL VARIATIONS OF VESTIBULAR AQUEDUCT DIMENSIONS IN TEMPORAL BONE CT SCAN

M. POURSADEGH,* M.D., G. HASHEMI,** M.D., AND M.M.
JALALI,*** M.D.

*From the Departments of Otolaryngology and Radiology, Emam Reza Hospital, Mashhad University of
Medical Sciences, Mashhad, I.R. Iran.*

ABSTRACT

Various dimensions of the human vestibular aqueduct were evaluated in two groups, patient and control, and these measurements were compared. Both groups were examined clinically, followed by audiometric evaluation and temporal bone high resolution CT scan. It was found that in approximately one third of the patient group (with idiopathic SNHL), the vestibular aqueduct was 1.5 mm or larger. Also, the midpoint diameter of the distal limb was larger than in the control group ($p < 0.01$). But there was no relation between the various dimensions of the vestibular aqueduct and mastoid pneumatization.

MJIRI, Vol. 14, No. 3, 199-202, 2000.

Keywords: Large vestibular aqueduct, Congenital SNHL, Temporal bone CT scan.

INTRODUCTION

The vestibular aqueduct (VA) is a bony canal in the otic capsule which extends from the medial wall of the vestibule to the outer opening in the posterior surface of the petrous pyramid and through which courses the endolymphatic duct.^{2,13} The first description of the VA was presented by Dominicus Cotunnis in 1774.³ The first description of a large VA based on imaging was by Valvassori and Clemis in 1978.^{10,13} With the advent of high resolution MRI, LVAS has been suggested to be the most common congenital inner ear malformation.¹²

The purpose of our study was to investigate clinical, audiometric and CT findings in patients with idiopathic sensorineural hearing loss and in a control group.

MATERIAL AND METHODS

At first, to determine the sample size of this comparative study, a pilot study was performed (21 patients and 31 controls). Adequate sample size ($\alpha = 0.05$, $\beta = 0.10$) was

found to be 66 cases. Then, this cross-sectional investigation was performed in two groups from May 1998 to June 1999.

In the patient group, there was no known cause for SNHL. A detailed history of gestation and pregnancy, mode of delivery, perinatal complications, infections, illness, ototoxic drug intake, trauma, family history and consanguinity was obtained. Patients with a history that suggested another cause of hearing loss were excluded from the study (for example, ototoxic drug intake, kernicterus, low birth weight, Apert's syndrome, Hurler's syndrome, middle ear abnormality, etc.). Minimal age for inclusion in the study was 4 years. Each patient had a complete head and neck, otologic and ophthalmologic examination. All patients were tested by an audiologist. PTA, SRT, SDS and tympanograms were obtained in the standard fashion. The control group consisted of patients that were undergoing temporal bone CT scan due to other problems (no SNHL).

Computed tomographic scans were obtained using a scanner unit (GE CT/T 9800) in Emam Reza Hospital. Sections of 1-1.5mm contiguous increments were performed. All of the images that were obtained in the axial plane¹¹ were reconstructed with a standard bone algorithm program.¹⁵

The ENT resident was blinded to the details of the two groups' CT images. All inner ear structures including cochlea, vestibule, semicircular canals, internal auditory ca-

*Associate professor and chairman, Department of Otolaryngology, Emam Reza Hospital, Mashhad Medical Sciences University, Mashhad, I.R. Iran.

**Assistant professor, Department of Radiology, Emam Reza Hospital.

***Senior resident, Department of Otolaryngology, Emam Reza Hospital.

Vestibular Aqueduct Anatomical Variations

nal, cochlear aqueduct, VA and mastoid pneumatization were assessed. The middle ear and mastoid cavities were simultaneously inspected for abnormalities. All of the CT images were confirmed by a radiologist. The following measurements and assessments were made;

- 1- Degree of mastoid pneumatization
- 2- The length of the vestibular aqueduct
- 3- The length of the external aqueductal aperture
- 4- The midpoint diameter of the distal limb
- 5- The length of the internal auditory canal (IAC)
- 6- The distance between the external aperture (EA) and IAC

The degree of perilyabyrinthine pneumatization was classified into three types: type I, corresponding to well developed pneumatization that extended posterior to the sigmoid sinus; type II, medium grade pneumatization that extended up to but not beyond the sigmoid sinus; and type III, poor or no pneumatization that was sclerotic.¹

The vestibular aqueduct was categorized into five types (Gado classification): type I: tubular, type II: filiform, type III: funnel shaped, type IV: visualization of the external aperture only, and type V: non-visualization of the external aperture and descending portion of the VA.⁷

Measurements pertaining to patient and control groups were evaluated by non-parametric analysis of variance (Kruskal-Wallis) and were compared by Wilcoxon-rank-sum test.

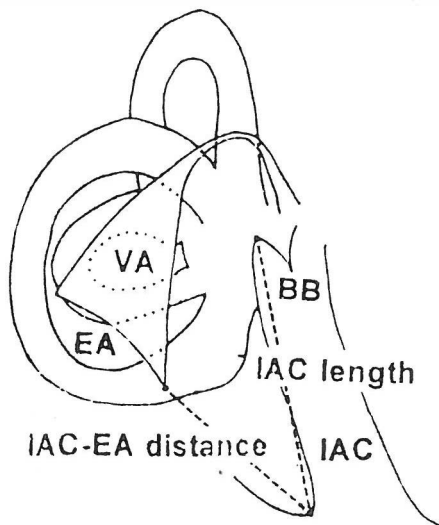


Fig. 1. Schematic diagram of VA, IAC, and EA-IAC distance.

RESULTS

The patient group consisted of 43 subjects, 25 male and 18 female, 6 to 65 years old (mean= 24.2 yr). It should be noted that 48% of patients were 14 years old or less. The control group consisted of 34 subjects, 23 male and 11 female, 5 to 80 years old (mean= 42.5 yr). Because the vestibular aqueduct increases in size and reaches maturity by age 4 years,³⁻⁵ it was expected that the different age distribution in the two groups would have no effect in this study.⁶

Based on the type of perilyabyrinthine pneumatization, temporal bones were categorized. In the patient group, the percentage of temporal bone in types I, II and III was 46.97%, 31.82% and 21.21%, respectively. As compared, these per-

Table I. Various VA dimensions in the control group (mm).

	Mean	SD	Range	Median	Mode
VA length	4.157	1.425	1.9-8.4	3.9	2.8
Midpoint diameter	1.025	0.438	0.3-2.9	1.0	0.7
VA aperture	2.432	1.270	0.4-6.0	2.4	0.9
IAC length	8.995	4.131	5.6-14.5	9.05	8.8
EA-IAC distance	9.749	1.819	6.4-14.4	9.6	

Table II. Various VA dimensions in the patient group (mm).

	Mean	SD	Range	Median	Mode
VA length	4.237	1.352	1.8-12.2	4.1	4.1
Midpoint diameter	1.325	0.948	0.3-7.3	1.2	0.8
VA aperture	2.876	1.517	0.4-9.0	2.60	-
IAC length	8.904	1.423	5.4-12.6	8.9	-
EA-IAC distance	9.555	1.624	5.7-14.5	9.3	8.7

centages were 12.50%, 34.38% and 53.12%, respectively in the control group.

Also, according to the Gado classification in the patient group, 51.16% of temporal bones were type I, 23.26% of them were type II and 25.58% of them were type III. In the control group, the percentage of temporal bones in types I, II and III were 24.93%, 14.8

Various VA dimensions of control and patient groups are shown in Table I and Table II, respectively.

Since the distribution of samples was not normal and this was confirmed by the chi-square test, the Kruskal-Wallis test and Wilcoxon-rank-sum test were used for statistical analysis.

Based on pneumatization, the statistical significance of various dimensions was evaluated in the two groups via analysis of variance. Only in the patient group was the relation between the midpoint diameter of VA and temporal bone pneumatization significant. Also, when various dimensions of the two groups were compared (via non-parametric t-test), only the difference of midpoint diameters ($p < 0.01$) and VA apertures ($p < 0.05$) were significant. No difference existed between the other dimensions.

On the other hand, normal ears in the patient group were examined. It was found that the distribution profile of the midpoint diameter of the distal limb had skewness and its mean was 1.312 ± 0.529 mm. The difference between these measurements and the control group was significant ($p < 0.01$).

Table III. Prevalence of inner ear abnormalities.

Inner ear abnormality	Percentage
Large vestibular aqueduct	37.76
Vestibule abnormality	16.18
Vestibule and SCC abnormalities	13.24
Vestibule, SCC and cochlear abnormalities and LVA	4.41

Tinnitus and vertigo were found in 42.8% and 23.5%, respectively. An impaired tandem-Romberg test was seen in 44.62%. There was a family history of SNHL in 20.93% of the patient group. In audiometric evaluation of the patient group, CHL was found in 23.3%. The most common PTA pattern was flat (25.93%). Other patterns were upward (24.07%), downward (7.41%), reverse U (3.7%) and deaf (38.89%). Among the different abnormalities of the inner ear's patient group, a large VA was seen more than others (Table III).¹⁴

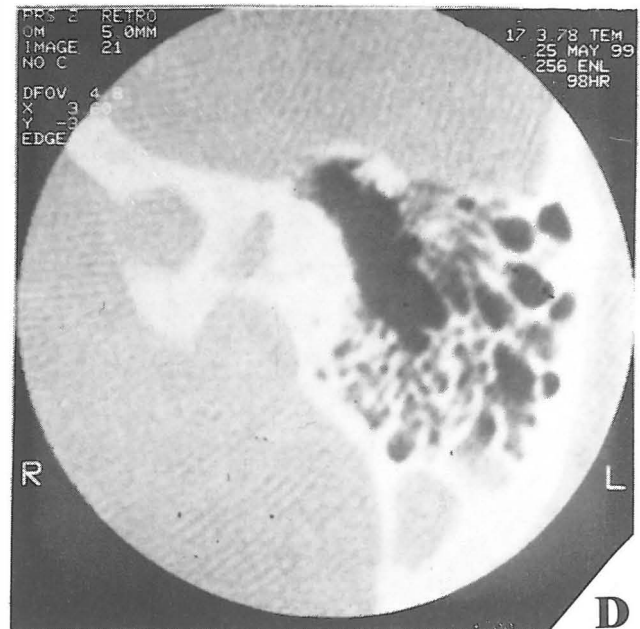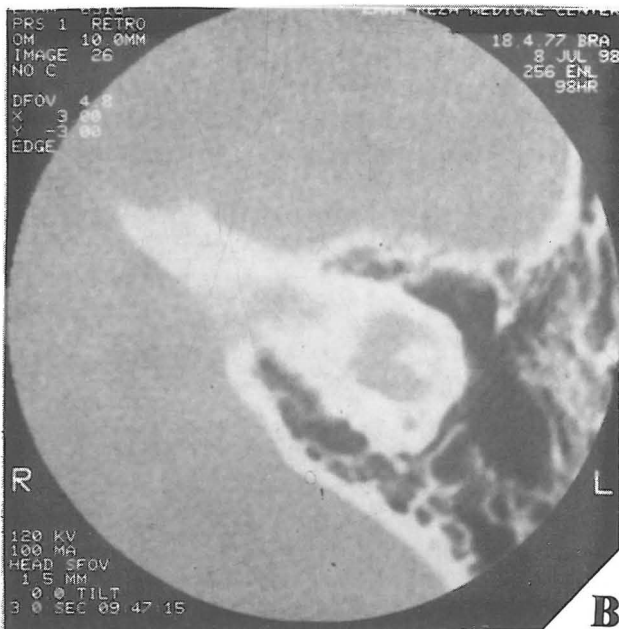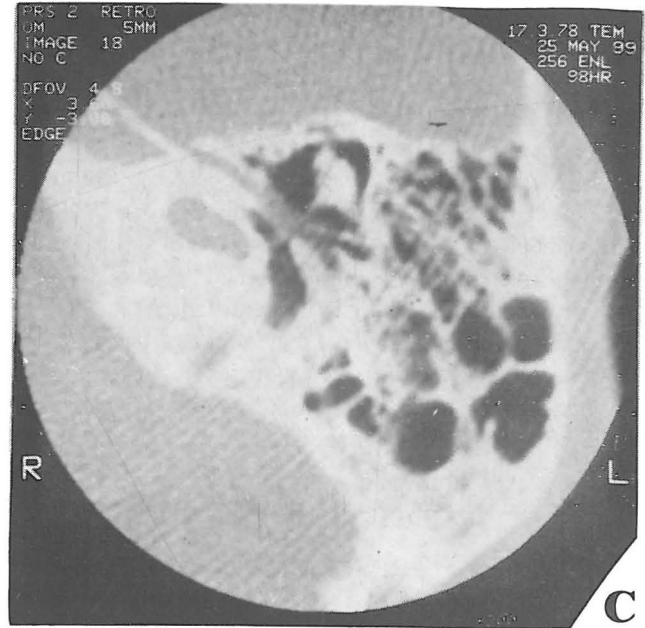


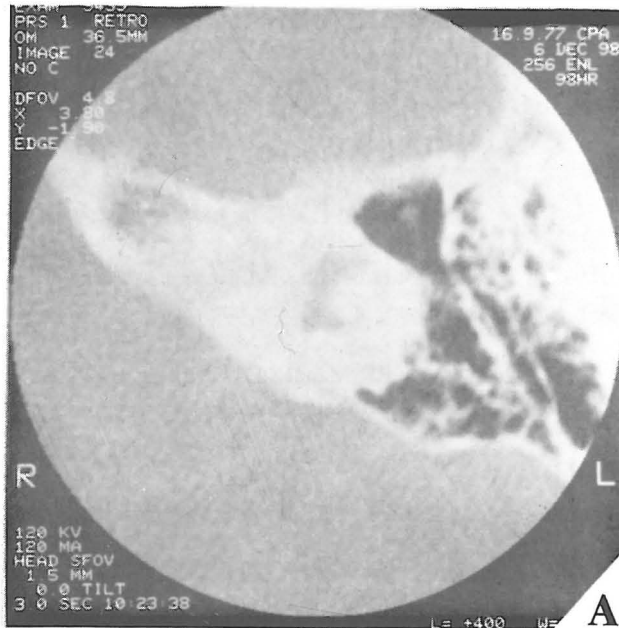Fig. 2. Examples of observed inner ear abnormalities in the patient group's CT scan. a: vestibule abnormality, b: vestibule and LSCC abnormalities, c: cochlear hypoplasia and LVA, d: vestibule, LSCC and cochlear abnormalities and extreme LVA.

DISCUSSION

In this study, we concluded that there was no correlation between various VA dimensions and its surrounding structures and perilyabyrinthine pneumatization (in contrast to Dimopoulos' study).³ Only the midpoint diameter of the distal limb was related to pneumatization in the patient group. But the Pearson correlation coefficient was 0.255. Thus, this correlation isn't strong. Probably, previous authors failed to consider whether their samples had normal distribution. Also, we concluded that in the patient group, the midpoint diameter of the distal limb was larger than the control group ($p < 0.01$). Sizes equal to 1.4 mm or more in patient and control groups were 36.76% and 10.29%, respectively.⁹ Of interest, in normal ears of the patient group, there was LVA in 35.29%. This finding may be due to genetic predisposing factors that result in progressive SNHL. In this study, no relation between the external aperture (EA) and length of the distal portion of VA was found (in contrast to Wilbrand and Dimopoulos' studies).³ But EA-IAC distance was related to the length of IAC ($r = 0.407$) and $Y = 1.962 + 0.405X$ ($Y =$ the length of IAC, $X =$ EA-IAC distance).

In conclusion, we believe that an enlarged VA may be only a bony marker of membranous anomalies⁸ and thus, until an accurate method is available to assess the membranous labyrinth, we may recognize these patients and predict progression of their SNHL by clinical markers such as audiogram and CT scan.

REFERENCES

1. Arenberg IK, Dupatocinio I, Dreisbach JM, Seibert C: Radiographic classification of the vestibular and cochlear aqueducts: the paired correlation between normal and abnormal vestibular aqueduct and cochlear aqueduct anatomy. *Laryngoscope* 94: 1325-1333, 1984.
2. Becker TS, Vignaud J, Sultan A, Lachman M: The vestibular aqueduct in congenital deafness: evaluation by the axial projection. *Radiology* 149: 741-744, 1983.
3. Dimopoulos PA, Smedby O, Wilbrand HF: Anatomical variations of the human vestibular aqueduct, Part I. A radioanatomical study. *Acta Radiologica* 37 (Suppl 403): 21-32, 1996.
4. Dimopoulos PA, Smedby O, Wilbrand HF: Anatomical variations of the human vestibular aqueduct, Part II. A radioanatomical study. *Acta Radiologica* 37 (Suppl 403): 33-41, 1996.
5. Eby TL, Nadol JB: Postnatal growth of the human temporal bone: implications for cochlear implants in children. *Ann Otol Rhinol Laryngol* 95: 356-364, 1986.
6. Fujita S, Sando I: Three-dimensional course of the vestibular aqueduct. *Eur Arch Otorhinolaryngol* 253: 122-125, 1996.
7. Gado MH, Arenberg IK: Radiological visualization of the vestibular aqueduct. *Radiology* 117: 621-626, 1975.
8. Griffith AJ, Arts A, Downs C, Innis JW, Shepard NI, Sheldon S, Gebarski SS: Familial large vestibular aqueduct syndrome. *Laryngoscope* 106: 960-965, 1996.
9. Jackler RK, De la Cruz A: The vestibular aqueduct syndrome. *Laryngoscope* 99: 1238-1243, 1989.
10. Phelp S: Large vestibular aqueduct: large endolymphatic sac? *The Journal of Laryngology and Otology* 110: 1103-1104, 1996.
11. Swartz JD, Yussen PS, Mandell DW, Mikaelian DO, Berger AS, Wolfson RJ: The vestibular aqueduct syndrome: computed tomographic appearance. *Clinical Radiology* 36: 241-243, 1985.
12. Tong KA, Harnsberger HR, Dahlen RT, Carey JC, Ward K: Large vestibular aqueduct syndrome: a genetic disease? *AJR* 168: 1097-1101, 1997.
13. Valvassori GE, Clemis JD: The large vestibular aqueduct syndrome. *Laryngoscope* 88: 723-728, 1978.
14. Valvassori GE: The large vestibular aqueduct and associated anomalies of the inner ear. *Otolaryngologic Clinics of North America* 16(1): 95-101, 1983.
15. Zalzal GH, Tomaski SM, Vezina LG, Bjornsti P, Grundfast KM: Enlarged vestibular aqueduct and sensorineural hearing loss in childhood. *Arch Otolaryngol Head Neck Surgery* 121: 23-28, 1995.