




Effectiveness and Safety of Transplantation of the Stromal Vascular Fraction of Autologous Adipose Tissue for Wound Healing in the Donor Site in Patients with Third-Degree Skin Burns: A Randomized Trial

Maksim G. Ryabkov^{1*}, Marfa N. Egorikhina¹, Nikita A. Koloshein¹, Kseniya S. Petrova¹, Mikhail G. Volovik¹, Nataliya Yu. Orlinskaya¹, Aleksandra O. Moskovchenko¹, Irina N. Charykova¹, Diana Ya. Aleynik¹, Daria D. Linkova¹, Igor E. Pogodin¹, Irina I. Kobyakova¹, Igor Yu. Arefyev¹

Received: 29 Nov 2022

Published: 21 Jun 2023

Abstract

Background: The quality of the wound healing at the donor site significantly determines the overall condition of the burn patient, the extent of wound fluid and protein losses, the severity of any systemic in-inflammatory reaction, and the intensity of the pain syndrome. It is known that the stromal vascular fraction (SVF) has a beneficial effect on the healing of wound defects. This study is aimed at assessing the safety and effectiveness of the application of the SVF of autologous adipose tissue to stimulate wound healing of the donor site in patients with burns.

Methods: This placebo-controlled clinical study included 38 patients with third-degree thermal skin burns. The patients underwent liposuction, enzymatic isolation of the SVF, and intradermal injection of the preparation into the wounds in the donor site, followed by tewametry, cutome-try, thermography and biopsy after 12 days. Quantitative indicators were compared using the Mann-Whitney test for unrelated groups and the Wilcoxon test for related groups. Spearman's rank correlation coefficient (RS) was used to assess the correlation

Results: Epithelization of the wounds in all patients was seen over an average area of 88 (84;92) %, there being no significant differences between the actual and the control wound sites for this parameter. Transdermal water loss in the test wound sites was 2 times lower than in the control sites ($P = 0.001$). The wound donor sites regained their temperature distribution faster than the control sites ($P = 0.042$). Histological preparations of the skin of the wound sites revealed that their epidermal layer was 19% thicker compared to the controls ($P = 0.043$). It should be noted that five adverse events related to manipulations in the postoperative period were registered.

Conclusions: Transplantation of SVF autologous adipose tissue into the wound area in most clinical cases proceeded without complications. The area of epithelialization of wound areas after the introduction of SVF did not change, although a significant decrease in transdermal water loss was observed in the wound areas with an improvement in their thermoregulation and an increase in the thickness of the epidermis.

Keywords: Burns, Adipose Tissue, Mesenchymal Stem Cells, Stromal Vascular Fraction, Wound Healing, Transplant Donor Site, Skin Transplantation

Conflicts of Interest: None declared

Funding: The work was carried out within the framework of the program "Priority-2030", by the Minister of Science and Higher Education of the Russian Federation.

*This work has been published under CC BY-NC-SA 1.0 license.

Copyright© Iran University of Medical Sciences

Cite this article as: Ryabkov MG, Egorikhina MN, Koloshein NA, Petrova KS, Volovik MG, Orlinskaya NY, Moskovchenko AO, Charykova IN, Aleynik DY, Linkova DD, Pogodin IE, Kobyakova II, Arefyev IY. Effectiveness and Safety of Transplantation of the Stromal Vascular Fraction of Autologous Adipose Tissue for Wound Healing in the Donor Site in Patients with Third-Degree Skin Burns: A Randomized Trial. *Med J Islam Repub Iran.* 2023 (21 Jun);37:70. <https://doi.org/10.47176/mjiri.37.70>

Introduction

Transplantation of a split-thickness autodermal trans-

plant from an intact skin site to the burn site is presently

Corresponding author: Dr Maksim G. Ryabkov, maxim-ryabkov@yandex.ru

¹ Federal State Budgetary Educational Institution of Higher Education Privolzhskiy Research Medical University of the Ministry of Health of the Russian Federation, 603005 Nizhny Novgorod, Russia

↑What is "already known" in this topic:

Studies have shown that the stromal-vascular fraction of autologous adipose tissue has immunomodulatory, anti-inflammatory, and angiogenic effects on the skin.

→What this article adds:

This study showed that SVF improved donor wound healing in patients with deep burns. The epidermis of donor wounds becomes thicker after SVF injection. Thermal regulation improves, and wound water loss is reduced.

the main reconstructive method for burns and will remain so in the immediate future. However, along with the expected therapeutic effect, autodermoplasty is also associated with adverse effects that include the formation of extensive superficial wounds at the skin donor sites. The duration and quality of the wound healing at the donor site (hereinafter referred to as the "WDS") significantly determine the overall condition of the burns patient, the extent of wound fluid and protein losses, the severity of any systemic inflammatory reaction, and the intensity of the pain syndrome (1, 2). The recovery rate and the quality of the repaired cover tissues in the donor site is a fundamental components of the effectiveness of such treatment of patients with critical burns, as persons in this group often need multiple transplants from the donor sites (3, 4). All of the above emphasize the need to develop techniques allowing for optimization of the healing of the WDSs, ensuring restoration of their blood supplies, epithelialization and repair of the overall structure of the damaged skin (5).

One of the most promising perspectives to optimize wound healing is the use of regenerative cell techniques (3, 6–8). A significant aspect of such techniques is the use of mesenchymal stem cells (hereinafter referred to as MSCs). According to recent studies, MSCs demonstrate high effectiveness in wound healing, not only due to their proliferative activity but also to their paracrine immunomodulatory effects and stimulation of the reparative processes (9–11).

However, it should be noted that optimal methods for the clinical use of MSCs in patients with burns are still open to discussion. The most attractive source of MSCs, according to many experts, is adipose tissue, but the best origin for this is still being debated. On the one hand, allogeneic material has an important advantage, as it can be obtained without any additional injury to the patient during sampling; on the other hand, a number of studies have shown the relatively higher effectiveness of autologous MSCs (12). At the same time, methods for obtaining and using MSCs are also being widely discussed. For instance, an increase in cell biomass by cultivation provides a more pronounced therapeutic effect due to the use of high cell concentrations. However, cultivating MSCs after their isolation is a complex process that is both time-consuming and costly, requiring the organization of cell biobanking. It should also be noted that, in some countries, there are specific restrictions related to the use of allogeneic materials and cultured human cells (13).

The above-mentioned problems prove the need to find other ways to obtain and use MSCs, which brings our attention to using the stromal vascular fraction containing MSCs as a source. The stromal vascular fraction (hereinafter referred to as the "SVF") is a heterogeneous population of cells isolated from adipose tissue. SVF isolation is associated with minimal manipulations, therefore significantly easing its clinical use and reducing costs (14). In addition to MSCs, SVF can include endothelial cells and their precursors, T-regulating cells, macrophages, smooth muscle cells, pericytes, and preadipocytes (15, 16).

The SVF has proven its effectiveness in the treatment of

various diseases. A number of studies have confirmed its beneficial effect on osteoarthritis, both when used independently and in combination with other components, such as PRP (17–24). The SVF is actively used in aesthetic medicine: in rejuvenation procedures (25), as well as for the clinical treatment of various forms of alopecia (26, 27) and acne (28). In recent years, the application of SVF has grown. For instance, the effectiveness of the SVF in restoring liver function has been shown (29), and there have been promising results in the treatment of Parkinson's disease (30), and of erectile dysfunction, and Peyronie's disease (31). Some studies have indicated autologous SVF cells can also be considered a safe medication delivery system for anticancer therapies (32).

It is known that SVF has a beneficial effect on the healing of wound defects, including burns, this being confirmed by both experimental and clinical studies. It has been demonstrated in a rat burn model that the SVF increases the concentration of growth factors, increases collagen formation, and stimulates angiogenesis and epithelialization (33–37). Clinical trials of SVF in the treatment of wound defects are not numerous at the moment. However, there are descriptions of the effects of accelerating neovascularization and epithelialization, as well as of the stabilization of inflammation, in a number of published studies (38–40).

It should be noted that the high reparative potential of the SVF is largely related to the heterogeneous composition of the fraction. The regenerative effect is achieved due to the impact of the complex of SVF cells. For example, the release of growth factors is mainly provided by MSCs, the proangiogenic effect—by microvascular cells and the immunomodulatory effect—by blood cells. Moreover, the SVF usually contains residual elements of the intercellular substance of the adipose tissue that has a stabilizing matrix effect, facilitating cellular interaction when SVF is applied to the damaged area. However, many researchers note that the heterogeneous nature of the SVF can hinder the selection of a standardized treatment regimen, making the development and standardization of new protocols for the isolation and preparation of the SVF a particularly relevant task for modern regenerative medicine (15, 16, 41, 42).

Our study is aimed at solving a fundamental and clinically significant issue, that is, the identification of the most likely positive and negative consequences of the transplantation of autologous stromal vascular fractions of adipose tissue in patients with deep thermal burns. At the launch of the study, the authors highlighted a hypothesis: biomedical technology, including tumescent liposuction, enzymatic treatment of the adipose tissue without any subsequent cell culture, and the intradermal injection of SVF into wounds in the donor site improve the functional and structural characteristics of newly formed skin without any clinically significant risk of postoperative complications in patients with deep burns.

Purpose: to evaluate the safety and effectiveness of biomedical technology for the transplantation of the autologous stromal vascular fraction of adipose tissue to stimulate wound healing in the skin donor sites in patients with

third-degree burns.

Methods

This prospective, placebo-controlled clinical trial included 38 patients (26 men and 12 women). All were hospitalized at the burns center of the University Hospital of the Federal State Budgetary Educational Institution of Higher Education, the "Privolzhsky Research Medical University" of the Ministry of Health of the Russian Federation (FSBEI HE PRMU MOH) with deep thermal burns in 2021–2022.

Criteria for inclusion: voluntary informed written consent of the patient; men and women aged 18–70 with verified diagnoses of third-degree thermal burns (according to ICD-10); a burn obtained 5–30 days before inclusion; an area of deep burning of 10%–60% of the body surface; absence of chronic skin diseases and autoimmune diseases.

Criteria for exclusion: active neoplastic processes; diseases of the blood system; pregnancy or lactation; immunodeficiency; tuberculosis; diabetes mellitus; positive Wasserman reaction; refusal (or inability) to sign an informed consent to participate in the study.

Preoperative therapy, surgical interventions, and postoperative therapy were conducted in accordance with the standards of medical care for patients with burns established in the Russian Federation (Thermal and chemical burns. Sunburn. Burns of the respiratory tract. National clinical guidelines. Moscow, Association of Combustionologists "World without burns". 2020:126.). The study complied with the international ethics principles and the requirements of the regulations of the Russian Federation, including the following: the Rules of the ICH GCP E6, and the requirements of the Declaration of Helsinki. The study was approved by the Local Ethics Committee of the Federal State Budgetary Educational Institution of Higher Education, the "Privolzhsky Research Medical University" of the Ministry of Health of the Russian Federation (FSBEI HE PRMU MOH), MoM No. 19 of 19.11.2021. All patients had the purpose, algorithm and possible re-

sults of therapeutic and diagnostic manipulations explained to them in detail, after which they provided their informed consent to the said manipulations. Recovery of the adipose tissue and SVF administration were conducted in a surgery room in compliance with the requirements of asepsis and antisepsis regulations.

Stages of biomedical technology: 1 —recovery of the adipose tissue; 2 —processing of the adipose tissue and isolation of the stromal vascular fraction of it, enriched with mesenchymal stem cells; 3 —randomization of the WDS sites and administration of the medication; 4 —control of the wound process.

Recovery of the adipose tissue

The skin of a site that was not thermally damaged was double treated with antiseptic and then the subcutaneous tissue of an area of at least 50 cm² was infiltrated with Klein's solution (Figure 1 a, b). The adipose tissue was aspirated with a blunt Mercedes-type cannula (150x3 mm and 150x1.3 mm) with a 20 ml syringe. After aspiration, the adipose tissue was transferred into a sterile tube (50 ml) with a biopsy transport medium and sent to the laboratory.

Processing of the adipose tissue and obtaining the SVF

Autologous cells of the stromal vascular fraction were recovered in the biotechnological laboratory of the University Hospital of the FSBEI HE PRMU MOH in line with the approved protocol. The source material for SVF recovery was the lipoaspirate obtained in the sterile-packed syringes. This lipoaspirate from the syringes was transferred into sterile tubes (50 ml, Costar, USA) and washed 3 times with sterile saline by laminar box centrifugation. The middle fraction between the sediment and the supernatant was removed. At the next stage, a 0.2% solution of Type 1 collagenase (Sigma, USA), equal to the volume of the lipoaspirate, was added to each tube. The lipoaspirate was subjected to heated enzymatic treatment to release the SVF cells using an orbital shaker at +37°C and 200 rpm over a period of 60 minutes. At the end of

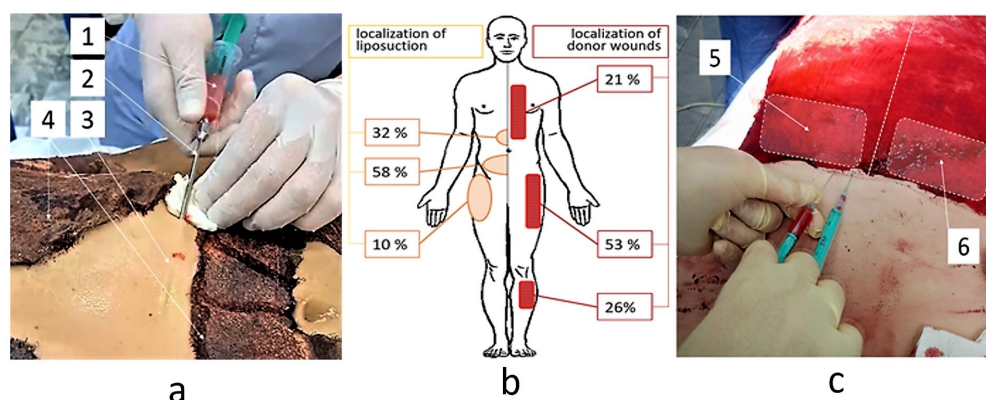


Figure 1. Stages of recovery and administration of the stromal vascular fraction of the adipose tissue of patients with third-degree burns: a —liposuction on the abdominal wall; b —localization of the liposuction areas and wounds of the donor site in the patients; c — intradermal injection of the SVF into the test site of the wound in the donor site. 1 —lipoaspirate in the syringe; 2 —cannula; 3 — liposuction area; 4 —area of the damaged skin under the bandage; 5 —the test area of the wound in the donor site; 6 —the control area of the donor wound.

the enzymatic treatment, sterile saline solution was added to the resulting suspension and re-suspended. After that, the suspension was centrifuged for 10 minutes at 1500 rpm. Here, the extracellular fat, adipocytes, and unseparated remains of the adipose tissue were removed. The sediment with the SVF cells was washed, re-centrifuged, and re-suspended in sterile saline and then filtered through a cell filter with a pore diameter of 100 μm (Costar, USA). The concentration of cells in the suspension and the proportion of living cells were calculated with a cell counter (Countes, Invitrogen, USA) using an intravital trypan blue dye. The resulting suspension of SVF cells was brought to a concentration of 1 ml/ml in 0.9% NaCl solution with 10% autologous patient serum and collected into syringes, which were packed in sterile packaging bags marked for each patient, before transfer to the burns department of the FSBEI HE PRMU MOH University Hospital.

Randomization of the WDS sites and administration of medication

Before the preparations were administered into the tissues, two sites of the equal area were specified on the surface of the planned wound of the donor site (Figure 1 b). The sites were randomized using a random number table into 2 groups: the studied group (SVF administration) and the control group (placebo (0.9% NaCl solution) administration). Randomization of wound sites with their division into 2 equal groups was carried out in accordance with the state standard of the Russian Federation GOST R ISO 24153-2012 "Statistical methods. Randomization and random sampling procedures" provided for such procedures. After that, the split skin transplants of thickness 0.4–0.45 mm were taken with an AESCULAP dermatome from both sites of the donor area. The SVF or placebo was administered by means of intradermal injection (Figure 1 c). The SVF dose was calculated on the basis of 0.1 ml of the preparation per 1 cm² of the WDS area being tested. The volume of the placebo injected into the control site was equal to the volume of the administered SVF. After administration, the wound was covered with a wet-to-dry gauze dressing and antiseptic.

The surgeon performed injections of drugs in the control (placebo) and study (SVF) areas of the wound. After that, the surface of the wound was closed with a bandage. Data on the drugs injected into each side of the wound were encrypted before being issued to surgeons. The patients were anesthetized and did not know which drug the researchers injected into one or another part of the wound. The bandage was removed after 12 days and functional diagnostics were performed: thermometry, cutometry, tewametry. Functional diagnostics were carried out by research doctors who did not have data on which drug was injected into each area of the wound. During the biopsy, each tissue sample was encrypted in the operating room and sent for histological examination. The pathologist had no data on the studied biopsy specimens.

Control of the wound process

12 days after administration, the dressing was removed from the WDS, the site was photographed, the area of

wound epithelization was assessed, and a non-invasive study of the functional parameters of the cover tissue was performed together with biopsies of the test and control areas of the wound. The area of WDS epithelization was assessed by means of computer-assisted planimetry. The functional study included the following: assessment of transdermal water loss (tevametry), skin elasticity (cutometry) and thermography of the wound surface. The tewametry (for the evaluation of the Transepidermal Water Loss, TEWL) and cutometry were conducted using a TPM-MS 750 testing device (Courage Khazaka electronic GmbH, Germany). The thermography was carried out with a Thermo Tracer TH-9100 thermal imager (NEC, Japan): spectral range of 8–14 μm ; sensitivity, 0.030 \pm 0.003 $^{\circ}\text{C}$; IR matrix resolution, 320 \times 240 pixels. An initial image was taken, followed by the cold test: a napkin moistened with saline at a temperature of +20 $^{\circ}\text{C}$ was put against the skin for 60 seconds. 180 sec after the cold test, thermographic images of both the test and control WDS areas were obtained.

The functional study and thermography were immediately followed by full-thickness biopsies of the newly formed skin in the test and control areas of the wound; these were fixed in 10% formalin; and then sent for standard histological processing, embedded in paraffin blocks (HistoStar, Thermo Scientific). Serial sections with a thickness of 4–6 microns (Microm HM 325, Thermo Scientific) were stained with hematoxylin and eosin (Gemini AS, Thermo Scientific). The morphometry of the newly formed skin layers was conducted using a 3DHISTECH PANNORAMIC MIDI scanning complex (Carl Zeiss, Hungary) in bright field mode with a magnification range of \times 50 to \times 400 by means of an automated image analysis system.

Statistical data processing

IBM SPSS Statistics software, V20 (IBM Corporation, Somers, NY, USA) was used for statistical data processing. The results are expressed as the Me (Q1; Q3), where Me is the median of the analyzed parameter and (Q1; Q3) is the 25th and 75th percentile values, respectively. Quantitative indicators were compared using the Mann-Whitney test for unrelated groups and the Wilcoxon test for related groups. Spearman's rank correlation coefficient (RS) was used to assess the correlation. The sample parameters provided below have the following designations: Me—median, Q1—upper quartile, Q3—lower quartile, n—size of the analyzed subgroup, p—value of statistical significance of differences. The critical value of the significance level was taken as equal to 5% ($P \leq 0.05$).

Results

The characteristics of the patients by gender, age, and range of concurrent diseases are given in Table 1.

Frequency of wound complications in the sites administered with adipose tissue and injected with SVF

To reduce the risk of infectious complications, lipoaspiration was conducted only on intact skin sites in various anatomical areas: for 22 patients—in the abdominal wall

Table 1. Characteristics of patients.

Characteristics	Number
Gender (men/women), n	26/12
Age, median [Q1;Q3]	44 [35; 59]
Body mass index (BMI)	19 [17.5; 22]
Causative agent (flame/hot liquid), n	18/20
Deep burn area, %	35 [30; 55]
Concurrent conditions, n	
Tobacco smoking	18
Arterial hypertension	9
Chronic obstructive pulmonary diseases	8

below the navel, for 12 patients—in the abdominal wall above the navel, for 4 patients—in the buttocks and the outer surface of the thigh (Figure 1b). To reduce the risk of muscular fascia perforation, two types of cannula movement in the subcutaneous tissue were used: reciprocating movements in liposuction areas over 150 mm long and with a subcutaneous tissue depth of over 20 mm; and rotational movement of the cannula in smaller liposuction areas.

Five adverse events associated with the study manipulations were registered during the postoperative period: local reactions of I–II degree according to the Clavien-Dindo system in the liposuction area (3 patients) and in the preparation administration area (2 patients). In two cases, local subcutaneous hematomas of 25 and 45 cm² formed in the subcutaneous tissue at the site of the adipose tissue recovery. One patient had a local reaction to the injection of Klein's solution, in the form of local edema and skin hyperemia (Table 2). Bleeding from the injection wounds was seen in 1 patient after placebo administration at the WDS control site. Hemostasis was conducted by short-term mechanical pressing of the tissue. All complications healed themselves without additional medical or surgical treatment.

Five adverse events associated with the study manipulations were registered during the postoperative period. Three cases of local reaction of I–II degree according to Clavien-Dindo in the area of liposuction: in two cases, local subcutaneous hematomas formed with an area of 25 and 45 cm², in one patient, there was a local reaction to the introduction of Klein's solution in the form of local edema and skin hyperemia. In addition, 2 cases of adverse events in the area of donor wounds were noted: one patient had infectious lysis of the epidermis in the studied area of the wound, and the second patient had bleeding from the peri-wound tissues after the injection of placebo (Table 2). There were no significant differences in the frequency of local complications in the studied and control wound areas (Fischer test - 0.5). The infection was stopped as a result of wound debridement and antibiotic change. Bleeding was stopped by mechanical pressure and electrocoagulation.

2 patients died (18 and 22 days) after autodermal transplant recovery and administration of the SVF and placebo into the donor wound sites. Death in both cases was caused by sepsis, which was not associated with the wound process in the WDS.

Analysis of the effectiveness of enzymatic treatment with adipose tissue in patients with burns

When the obtained primary material—lipoaspirate—was received in the laboratory, it varied in volume but was homogeneous in the proportion of adipose tissue. The Me (Q1;Q3) volume of the primary lipoaspirate from the patients amounted to 20.00 (15.00; 30.00) ml. After blood impurities, Klein's solution, and transport medium were removed, the primary volume of the adipose tissue itself was 5.0 (3.0; 7.5) ml. The median volume of the SVF primary suspension was 9.5 (5.6; 22.0) ml, with content of isolated nucleated cells of 12.0 (8.20; 30.0) million.

The analysis of correlation confirmed a direct relationship between the volume of the adipose tissue and the volume of the primary lipoaspirate: $RS=0.415$ ($P = 0.015$). Moreover, there was a positive correlation between the amount of adipose tissue recovered from the primary lipoaspirate, and the volume of the SVF suspension obtained therefrom: $RS=0.365$ ($P = 0.034$). However, there was no reliable correlation between the amount of recovered adipose tissue and the content of nucleated cells ($RS=0.300$, $P = 0.084$). There was also no correlation between the number of nucleated cells in the SVF and the volume of the primary lipoaspirate ($RS=-0.011$; $P = 0.951$). This indicates the variability of cellularity—i.e., the content of cells in the volume of the lipoaspirate and the adipose tissue—in patients with burns. Despite this, there was a high degree of correlation between the volume of the SVF suspension and the content of nucleated cells— $RS= 0.863$ ($P = 0.001$). This provides justification that the technique of SVF isolation we used permits the collection of similar SVF suspensions in terms of the number of cells from lipoaspirate and adipose tissues with different degrees of cellularity. The concentration of nucleated cells in the obtained suspension was 1.00 (1.00; 1.70) mln/ml.

Table 2. Frequency and severity of postoperative complications

Localization	Postoperative complications (according to Clavien-Dindo)		
	I	II	III–IV
1. Liposuction area, n=38	3	0	0
Test site of the WDS, n=38 (test group)	1	0	0
3. Control site of the WDS, n=38 (control group)	0	1	0
4. Total	4	1	0

The SVF suspension was adjusted to a concentration of 1 million/ml before use. The duration of the full procedure cycle from the receipt of the primary material at the laboratory until the availability of the SVF for the clinic was 2.8 (2.5; 3) hours.

Epithelialization of wounds at the donor site

On Day 12, after the skin transplant collection and injection of the preparations into the test and control areas, the wounds of the donor sites in all patients in the study had become epithelialized to around 88 (84; 92) % of the area. During the examination, the test and control areas of the wound looked the same: the major part of their area was covered with newly formed pink cyanotic skin without visible derivatives or the presence of eschar fragments (Figure 2).

There were no statistically significant differences in the area of epithelialization of the test and control areas (Wilcoxon test, $P = 0.109$): the area of tissue epidermis in the test areas was 89.5 (84; 94.3)%, while the control areas were epithelialized by 87 (83.7; 93.3)%.

Functional characteristics of the WDS cover tissues

There were statistically significant differences between the test and control sites in terms of transepidermal water loss (TEWL). The median indicator of the transdermal water loss in the test sites of the WDS was 4 (3.5;6) c.u., whereas in the control sites, it was 8 (5;9.5) c.u. ($P = 0.001$) (Figure 3 a). The elasticity of the newly formed skin in the test and control sites of the wound did not differ significantly. The test site indicator was 77 (75; 97) c.u., while the control site indicator was 76 (71;97) c.u. ($p=0.740$) (Figure 3 b).

Results of thermography of the surface of the donor site wounds

The temperature in the test and control sites of the wounds immediately after removing the dressings did not differ: the indicator for the wound test site was 34.7 (33.9; 36.0) 0C, whereas, for the control areas, it was 34.8 (33.8; 35.9) 0C ($P = 0.456$) (Figure 3 c). However, the temperature of the test areas of the wounds was restored faster after the cold test; after 180 seconds, it was significantly

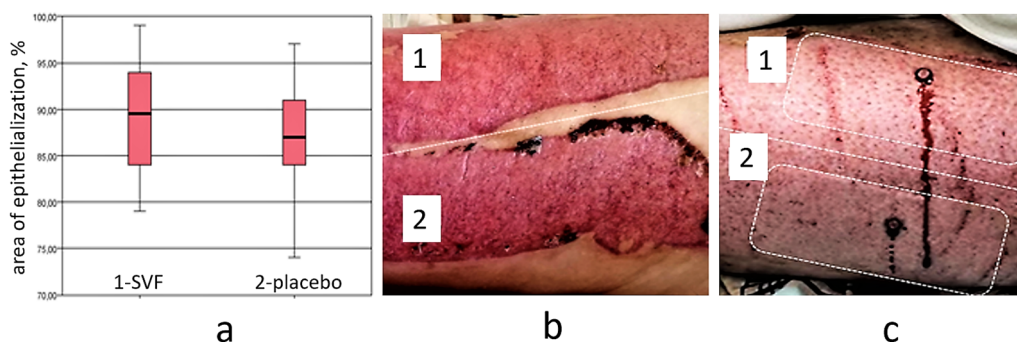


Figure 2. Epithelialization of the WDS areas: a —proportion of the epithelialized area of the WDS areas on Day 12 after SVF and placebo administration, %; b, c —examples of the epithelialized WDS at the time of biopsy, 12 days after transplant collection and the SVF and placebo administration (1 —test site, 2 —control site).

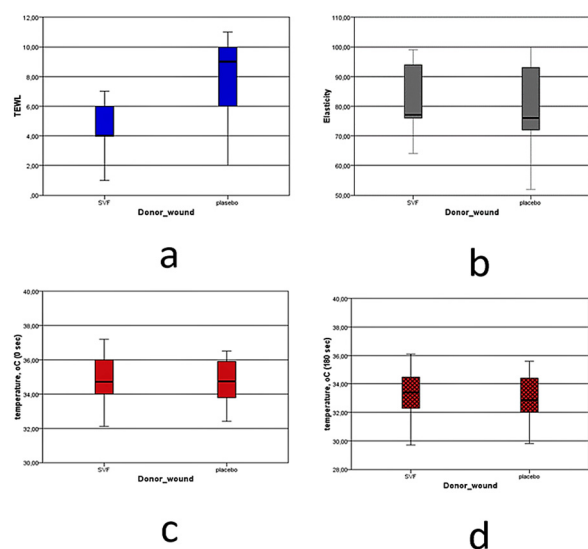


Figure 3. Functional characteristics of the skin in the WDS sites. a —transdermal water loss ($p=0.001$); b —elasticity ($p=0.740$), c —thermography, initial skin temperature in the WDS sites ($p=0.456$), 0C; d —thermography, skin temperature of the sites 180 seconds after application of the cold test ($p=0.042$).

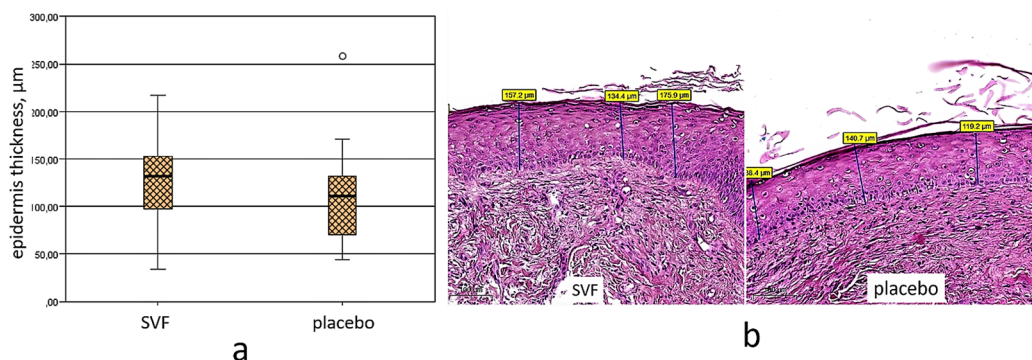


Figure 4. Thickness of the epidermis of the newly formed skin in the WDS sites. a—thickness of the epidermis, b—histological structure of skin preparations in the WDS sites (SVF—study site, placebo—control site).

higher than in the control areas: 33.4 (32.2; 34.6) and 32.6 (32.0; 34.4) OC, respectively ($P = 0.042$) (Figure 3 d).

Histological examination of WDS skin biopsy specimens

Histological examination of WDS skin biopsy specimens obtained after the SVF administration (in the test site) and placebo (in the control site) revealed epidermal skin layers in both the test and control WDS sites with a comparable frequency (Fischer's test, $P = 0.857$). However, morphometric analysis of the skin layers showed differences in the epidermis thickness in the test and controlled WDS sites. The thickness of the epidermis in the test wound sites was 132 (97; 165.5) µm by the time of biopsy, which was 18.9% thicker than that in the control wound sites—111 (68; 137.5) µm ($P = 0.043$) (Figure 4 a). Here, there were no signs of hyperkeratosis, neither in the test nor in the control sites (Figure 4 b). Such signs of inflammation as edema and cell infiltration in the preparations from the test WDS sites were less expressed than in the biopsy specimens from the control wound sites.

Discussion

A very high level of clinical biomedical technology safety is essential. Postoperative complications of liposuction can be registered even for patients of aesthetic plastic surgeons—examined and operated on during planned procedures, and usually having no severe concomitant pathologies. Such patients can develop hematomas, paresthesia, pain in the area of lipoaspiration, and wound infection after liposuction; sometimes, there is also damage to the underlying tissues due to intraperitoneal or intramuscular penetration by the cannula (43). The likelihood of complications inevitably increases in elderly patients having chronic diseases. Predictors of local complications are the presence of an insignificant thickness of adipose tissue and a lack of skin elasticity: Japanese authors report that after aspiration of the adipose tissue in 16 elderly male patients, 16 of them had subcutaneous hematomas, and 10 had decreased tactile sensitivity (44). Such predictors in patients with burns are additionally supplemented by the general severity of the body damage, depletion of subcutaneous tissues, as well as by thermal and infectious damage to the skin. The combination of such factors can significantly increase the risk of liposuction complications. The combined application of reciprocating and rotational

cannula movements in the patients we studied prevented excessive trauma and tissue infection. The frequency of our local postoperative complications was kept down to 13%. It is important to note that all the registered adverse events were mild and could be stopped without additional therapy or surgical interventions. This result, from the authors' point of view, negates a significant proportion of the concerns related to using liposuction and lipotransplantation in patients with burns.

The authors found characteristics of the skin peculiar to donor site wounds that represent a complex of consistent, interrelated pathophysiological and pathomorphological phenomena. The most expressed functional change in the skin after SVF administration was a decrease in the amount of transepidermal water loss. It is known that TEWL correlates to the greatest extent with the state of the skin surface layer—the epidermis: in the case that its integrity is damaged or it is thinned, water loss increases, while, on the contrary, full epithelialization of the wound surface is followed by a decrease in the level of TEWL (45). Other authors have described a direct correlation between the state of the newly formed cover tissues and their ability for thermal regulation: the horny layer of epidermal keratinocytes is crucial as a physical barrier (46). The interaction mechanisms of skin derivatives, pain receptors, TRPV4 ion channels, and thermoregulation are functionally associated with the effects of the introduction of mesenchymal stem cells into the tissue (47). Thus, the specified complex of morphofunctional manifestations in the wounds of the donor sites after SVF administration, unlike the wounds injected with placebo, is probably an essential consequence of the administration of a cell suspension with a high MSC content into the surface skin layers.

It should be noted that this study has original clinical limitations that prevent an even more profound assessment of the morphological and functional changes in the skin over time. First of all, these limitations are related to the use of only a single skin biopsy on Day 12 after the administration of the preparation. The selected timeframe for the wound process control is due to consideration of the following: the known physiological pattern of re-epithelialization of donor wounds is 10–14 days (48); the need to minimize damage to the wounds of the patients' donor sites. Repeated or earlier biopsy specimen examina-

tion in a clinical trial would entail the risk of damage to wound epithelialization. The development of technologies for non-invasive tracking of the wound recovery process that does not require multiple dressing removal from the wound will enable the identification of greater detail of the process of re-epithelialization and restoration of the dermis in donor site wounds. However, even the currently available data provide for stating the clinically significant effect of the use of MSC-containing SVF injections into the dermis of wounds of the donor sites in patients with deep burns.

Conclusion

Transplantation of autologous SVF adipose tissue into wounds of the donor sites in patients with deep thermal burns proceeded without complications in 87% of the clinical cases, 5 patients developed mild local reactions of the first or second degree according to the Clavien-Dindo system. Cover tissues in the SVF injection area were characterized by a significant (19%) increase in the thickness of the skin epidermis, together with optimization of the functional parameters of the newly formed cover tissue—a twofold decrease in the rate of transdermal water loss ($P = 0.001$) and accelerated recovery of thermal distribution after a cold test ($P = 0.042$).

Overall, the complex of indicators evidencing clinical safety and the effectiveness of the studied technology proves the feasibility of its use to stimulate wound healing in the donor sites of patients with deep thermal skin burns.

Author Contributions

Conceptualization, MR, ME; Data curation, NA, AM, DL, IK; Funding acquisition, ME and IA; methodology, MR, IO, IC, DA, IK; Project administration, IA; validation, IEP, IYA; formal analysis, MGR, MNE; investigation NK, KP, MV, AM, IC, DA and IK; resources, IP and IA; supervision, ME and IA; visualization, KP, MV, NO and AM; writing – original draft, NK, KP and MV; writing – review & editing, MR, ME, NO and DA.

All authors have read and agreed to the published version of the manuscript.

Institutional Review Board Statement

The study was approved by the Local Ethics Committee of the Federal State Budgetary Educational Institution of Higher Education, the "Privolzhsky Research Medical University" of the Ministry of Health of the Russian Federation (FSBEI HE PRMU MOH), MoM No. 19 of 19.11.2021.

Informed Consent Statement

Informed consent was obtained from all subjects involved in the study.

Conflict of Interests

The authors declare that they have no competing interests.

References

1. Borisov VS, Sachkov AV, Kaplunova MY, Titova GP, Borovkova NI,

- Ponomaryov IN, et al. Experience in Use of Biological Coatings in Complex Treatment of Extensive Burn Wounds. *Med Alph.* 2020;39–43.
2. Bogdanov SB, Karakulev AV, Polyakov AV, Gilevich IV, Petrov AA, Ivaschenko YV, et al. Possibilities of Using Innovative Technologies for Treating a Victim with Thermal Injury (Case Report). *Pediatr. Traumatol Orthop Reconstr Surg.* 2022;10:71–78.
3. Momeni M, Fallah N, Bajouri A, Bagheri T, Orouji Z, Pahlevanpour P, et al. A Randomized, Double-Blind, Phase I Clinical Trial of Fetal Cell-Based Skin Substitutes on Healing of Donor Sites in Burn Patients. *Burns.* 2019;45:914–922.
4. MacHaria, M.; Nangole, F.W. Effects of Dressing Materials on Donor Site Morbidity: A Comparative Study at a Tertiary Hospital in Kenya. *Ann Plast Surg.* 2019;83:22–25.
5. Burusapat C, Supawan M, Pruksapong C, Pitiseree A, Suwantemee C. Topical Aloe Vera Gel for Accelerated Wound Healing of Split-Thickness Skin Graft Donor Sites: A Double-Blind, Randomized, Controlled Trial and Systematic Review. *Plast Reconstr Surg.* 2018;142:217–226.
6. Hussain Z, Thu HE, Rawas-Qalaji M, Naseem M, Khan S, Sohail M. Recent Developments and Advanced Strategies for Promoting Burn Wound Healing. *J Drug Deliv Sci Technol.* 2022;68:103092.
7. Li JY, Ren KK, Zhang WJ, Xiao L, Wu HY, Liu QY, et al. Human Amniotic Mesenchymal Stem Cells and Their Paracrine Factors Promote Wound Healing by Inhibiting Heat Stress-Induced Skin Cell Apoptosis and Enhancing Their Proliferation through Activating PI3K/AKT Signaling Pathway. *Stem Cell Res Ther.* 2019;10:1–17.
8. Artsimovich IV, Zinoviev EV, Gostimskiy AV, Asadulayev MS, Vissarionov SV, Manukovskiy VA, et al. Experimental Evaluation of the Effectiveness of Adipose Mesenchymal Stem Cells in Full-thickness Skin Wounds. *Pediatr Traumatol Orthop Reconstr Surg.* 2021;9:175–181.
9. Rezaei Yazdi F, Ghahary A, Mirdoraghi M, Sarvnaz H, Asgardoost MH, Rastegar T, et al. Promotion of Burn Wound Healing by Local Application of Adipose-Derived Mesenchymal Stem Cells: An Experimental Study. *Med J Islam Repub Iran.* 2021;35:172.
10. Riedl J, Popp C, Eide C, Ebens C, Tolar J. Mesenchymal Stromal Cells in Wound Healing Applications: Role of the Se-cretome, Targeted Delivery and Impact on Recessive Dystrophic Epidermolysis Bullosa Treatment. *Cytotherapy* 2021;23:961–973.
11. Xiong W, Zhang R, Zhou H, Liu Y, Liang M, Li K, et al. Application of Nanomed-icine and Mesenchymal Stem Cells in Burn Injuries for the Elderly Patients. *Smart Mater Med.* 2022.
12. Maranda E, Rodriguez-Menocal L, Badiavas E. Role of Mesenchymal Stem Cells in Dermal Repair in Burns and Diabetic Wounds. *Curr Stem Cell Res Ther.* 2016;12:61–70.
13. On Biomedical Cell Products: Federal Law No. 180-FZ of June 23, 2016 // *Rossiyskaya Gazeta.* – 2016. – (139). // SPS “Consultant Plus”.
14. Trivisonno A, Alexander RW, Baldari S, Cohen SR, Di Rocco G, Gentile P, et al. Intraoperative Strategies for Minimal Manipulation of Autologous Adipose Tissue for Cell- and Tis-sue-Based Therapies: Concise Review. *Stem Cells Transl Med.* 2019;8:1265–1271.
15. Bora P, Majumdar AS. Adipose Tissue-Derived Stromal Vascular Fraction in Regenerative Medicine: A Brief Review on Biology and Translation. *Stem Cell Res Ther.* 2017;8.
16. Klar AS, Zimoch J, Biedermann T. Skin Tissue Engineering: Application of Adipose-Derived Stem Cells. *Biomed Res Int.* 2017;2017.
17. Aletto C, Francesco O, Maffulli N. Knee Intra-Articular Administration of Stromal Vascular Fraction Obtained from Ad-ipose Tissue: A Systematic Review. *J Clin Orthop Trauma.* 2022;5:101773.
18. Fotouhi A, Maleki A, Dolati S, Aghebati-Maleki A, Aghebati-Maleki L. Platelet Rich Plasma, Stromal Vascular Fraction and Autologous Conditioned Serum in Treatment of Knee Osteoarthritis. *Biomed Pharmacother.* 2018;104:652–660.
19. Lavagnolo U, Veronese S, Negri S, Magnan B, Sbarbati A. Lipoaspirate Processing for the Treatment of Knee Osteoarthritis: A Review of Clinical Evidences. *Biomed Pharmacother.* 2021;142:111997.
20. Dallo I, Morales M, Gobbi A. Platelets and Adipose Stroma Combined for the Treatment of the Arthritic Knee. *Arthrosc Tech.* 2021;10:e2407–e2414.
21. Andia I, Maffulli N. New Biotechnologies for Musculoskeletal Injuries. *Surg.* 2019;17:244–255.

22. Pak J, Lee JH, Pak N, Pak Y, Park KS, Jeon JH, et al. Cartilage Regeneration in Humans with Adipose Tissue-Derived Stem Cells and Adipose Stromal Vascular Fraction Cells: Updated Status. *Int J Mol Sci.* 2018;19.
23. Zhao X, Guo J, Zhang F, Zhang J, Liu D, Hu W, et al. Therapeutic Application of Adipose-Derived Stromal Vascular Fraction in Diabetic Foot. *Stem Cell Res Ther.* 2020;11.
24. Di Matteo B, Vandenbulcke F, Vitale ND, Iacono F, Ashmore K, Marcacci M, et al. Minimally Manipulated Mesenchymal Stem Cells for the Treatment of Knee Osteoarthritis: A Systematic Review of Clinical Evidence. *Stem Cells Int.* 2019;2019.
25. Suh A, Pham A, Cress MJ, Pincelli T, TerKonda SP, Bruce AJ, et al. Adipose-Derived Cellular and Cell-Derived Regenerative Therapies in Dermatology and Aesthetic Rejuvenation. *Ageing Res Rev.* 2019;54.
26. Anderi R, Makdissy N, Azar A, Rizk F, Hamade A. Cellular Therapy with Human Autologous Adipose-Derived Adult Cells of Stromal Vascular Fraction for Alopecia Areata. *Stem Cell Res Ther.* 2018;9.
27. Epstein GK, Epstein JS. Mesenchymal Stem Cells and Stromal Vascular Fraction for Hair Loss: Current Status. *Facial Plast Surg Clin North Am.* 2018;26:503–511.
28. Behrangi E, Moradi S, Ghassemi M, Goodarzi A, Hanifnia A, Zare S, et al. The Investigation of the Efficacy and Safety of Stromal Vascular Fraction in the Treatment of Nanofat-Treated Acne Scar: A Randomized Blinded Controlled Clinical Trial. *Stem Cell Res Ther.* 2022;13:L298.
29. Choi JS, Chae DS, Ryu HA, Kim SW. Transplantation of Human Adipose Tissue Derived-SVF Enhance Liver Function through High Anti-Inflammatory Property. *BBA - Mol Cell Biol. Lipids* 2019;1864:158526.
30. Carstens M, Haq I, Martinez-Cerrato J, Dos-Anjos S, Bertram K, Correa D. Sustained Clinical Improvement of Parkinson's Disease in Two Patients with Facially-Transplanted Adipose-Derived Stromal Vascular Fraction Cells. *J Clin Neurosci.* 2020;81:47–51.
31. Haney NM, Gabrielson A, Kohn TP, Hellstrom WJG. The Use of Stromal Vascular Fraction in the Treatment of Male Sexual Dysfunction: A Review of Preclinical and Clinical Studies. *Sex Med Rev.* 2019;7:313–320.
32. Minev BR, Lander E, Feller JF, Berman M, Greenwood BM, Minev I, et al. First-in-Human Study of TK-Positive Oncolytic Vaccinia Virus Delivered by Adipose Stromal Vascular Fraction Cells. *J Transl Med.* 2019;17.
33. Cardoso AL, Bachion MM, de Moraes JM, Fantinati MS, De Almeida VLL, Lino Júnior RS. Adipose Tissue Stromal Vascular Fraction in the Treatment of Full Thickness Burns in Rats. *Acta Cir Bras.* 2016;31:578–585.
34. Laididing SR, Josh F, Battung S, Bukhari A, Warsinggi, Patellongij IJ, et al. Combination of Platelet-Rich Plasma and Stromal Vascular Fraction on the Level of Transforming Growth Factor- β in Rat Subjects Experiencing Deep Dermal Burn Injury. *Ann Med Surg.* 2021;64.
35. Prasai A, El Ayadi A, Mifflin RC, Wetzel MD, Andersen CR, Redl H, et al. Characterization of Adipose-Derived Stem Cells Following Burn Injury. *Stem Cell Rev Rep.* 2017;13:781–792.
36. Laididing SR, Josh F, Nur K, Nurhadi AR, Hamzah MR, Ramadhan E, et al. The Effect of Combined Platelet-Rich Plasma and Stromal Vascular Fraction Compared with Platelet-Rich Plasma, Stromal Vascular Fraction, and Vaseline Alone on Healing of Deep Dermal Burn Wound Injuries in the Wistar Rat. *Med. Clin Pract.* 2021;4:100239.
37. Laididing SR, Josh F, Battung S, Bukhari A, Warsinggi, Patellongij IJ, et al. Combination of Platelet Rich Plasma and Stromal Vascular Fraction on the Level of Vascular Endothelial Growth Factor in Rat Subjects Experiencing Deep Dermal Burn Injury. *Ann Med Surg.* 2021;64:102254.
38. Eyuboglu AA, Uysal CA, Ozgun G, Coskun E, Markal Ertas N, Haberal M. The Effect of Adipose Derived Stromal Vascular Fraction on Stasis Zone in an Experimental Burn Model. *Burns.* 2018;44:386–396.
39. Yastı AÇ, Akgün AE, Akın M. Use of Stromal Vascular Fraction Stem Cell Therapy for Functional and Cosmetic Outcomes in a Young Female Patient with Deep Dermal Flame Burns on the Face. *Burn Open.* 2022;6:116–119.
40. Luck J, Smith OJ, Malik D, Mosahebi A. Protocol for a Systematic Review of Autologous Fat Grafting for Wound Healing. *Syst Rev.* 2018;7.
41. Gentile P, Sterodimas A, Pizzicannella J, Dionisi L, De Fazio D, Calabrese C, et al. Systematic Review: Allo-genic Use of Stromal Vascular Fraction (SVF) and Decellularized Extracellular Matrices (ECM) as Advanced Therapy Medicinal Products (ATMP) in Tissue Regeneration. *Int J Mol Sci.* 2020;21:1–14.
42. Laschke MW, Menger MD. The Simpler, the Better: Tissue Vascularization Using the Body's Own Resources. *Trends Biotechnol.* 2022;40:281–290.
43. Simonacci F, Bertozzi N, Grieco MP, Raposio E. From Liposuction to Adipose-Derived Stem Cells: Indications and Technique. *Acta Biomed.* 2019;90:197–208.
44. Toriyama K, Ebisawa K, Yagi S, Takanari K, Nakamura Y, Yamamoto T, et al. Liposuction for Autologous Adipose-Derived Regenerative Cells: Preliminary Results of Donor-Site Complications in Male Stress Urinary Incontinence. *JPRAS Open.* 2019;19:121–124.
45. Klotz T, Ibrahim A, Maddern G, Caplash Y, Wagstaff M. Devices Measuring Transepidermal Water Loss: A Systematic Review of Measurement Properties. *Ski Res Technol.* 2022;28:497–539.
46. Abdayem R, Haftek M. The Epidermal Barrier. *Ann Dermatol Venereol.* 2018;145:293–301.
47. Fujii N, Kenny GP, Amano T, Honda Y, Kondo N, Nishiyasu T. Evidence for TRPV4 Channel Induced Skin Vasodilation through NOS, COX, and KCa Channel Mechanisms with No Effect on Sweat Rate in Humans. *Eur J Pharmacol.* 2019;858:172462.
48. Oh SJ. A Systematic Review of the Scalp Donor Site for Split-thickness Skin Grafting. *Arch Plast Surg.* 2020;47:528–534.