Original Article
http://mjiri.iums.ac.ir
Medical Journal of the Islamic Republic of Iran (MJIRI)

Med J Islam Repub Iran. 2023 (5 Jun);37.62. https://doi.org/10.47176/mjiri.37.62

Extra-anatomical Obturator Bypass Due to Groin Infection

Mahmoud Mohammed Moawed[1]*, Salah Mohammed Abd-Elghany[2]

Received: 22 Jan 2023 Published: 5 Jun 2023

Abstract

Background: A rather common side effect of using prosthetic grafts is infection of the groin area. Infections in the groin may be avoided by performing arterial bypass tenneling via the obturator foramen during lower extremity revascularization. This study aimed to evaluate the safety and efficacy of extra-anatomical bypass obturator in patients with groin infection.

Methods: This cohort included a convenient sample of 100 patients with groin infections who planned to do an extra-anatomical obturator bypass. All patients were subjected to history taking and clinical assessment. Ultrasonography with duplex screening is a good initial technique to assess groin masses. Combination of computed tomography (CT) or magnetic resonance imaging (MRI) with indium-labeled leucocyte scintigraphy can also play a role in the diagnosis.

Results: Inflow from the already-existing graft limb was used in 54% of obturator canal bypass (OCB) procedures, with 32 limbs coming from the main iliac (27.3%) and 6 limbs from the infrarenal aorta (5.1%). The distal superficial femoral artery was used in 21 limbs (17.9%), while the above-knee popliteal artery was selected as the outflow artery in 82% of cases. Primary aided patency was 68% at 24 months, according to Kaplan-Meier analysis, whereas primary patency was 63% at that time. At 24 months, the secondary patency of the OCB was 83%.

Conclusion: In case of groin infections, an excellent option to restore flow is an obturator bypass graft. This graft is strong, reliable, and safe. As a result of its high patency rate, it may be the first choice in certain circumstances.

Keywords: Groin Infections, Obturator Bypass, Extra-anatomical Bypass

Conflicts of Interest: *None declared*
Funding: *None*

This work has been published under CC BY-NC-SA 1.0 license.
Copyright© Iran University of Medical Sciences

Cite this article as: Moawed MM, Abd-Elghany SM. Extra-anatomical Obturator Bypass Due to Groin Infection. *Med J Islam Repub Iran.* 2023 (5 Jun);37:62. https://doi.org/10.47176/mjiri.37.62

Introduction

A rather common complication linked to the utilization of prosthetic grafts in vascular treatment is infections in the groin. Based on the aggressiveness of the implicated microbes and the patient's overall health, it may sometimes be a pathology that poses a concern (1, 2).

The groin area is where infections of both natural and artificial vessels are most commonly seen (3). Infected lymph glands or the surgical split of lymphatic channels, the groin's closeness to the perineum, the relatively superficial site of vascular grafts in the groin, and the emergence of wound infections next to a vascular graft are the key risk factors for vascular groin infections (4).

The patient's life and the damaged limb are in danger.

Corresponding author: *Dr Mahmoud Mohammed Moawed, moawedsurgeon@yahoo.com*

1. Department of Vascular Surgery, Damietta Faculty of Medicine, Al-Azhar University, Damietta, Egypt
2. Department of Plastic Surgery, Damietta Faculty of Medicine, Al-Azhar University, Damietta, Egypt

↑What is "already known" in this topic:
Infection of the groin is a major concern after prosthetic grafts for vascular access. Different modalities are in action, and obturator bypass is one of these modalities that is sometimes used as a treatment modality. However, its efficacy and safety profile are not sufficiently covered in the literature.

→What this article adds:
This article added to the available literature about the use of obturator bypass. It confirmed its use as a relevant alternative with a good patency rate (either primary or secondary). In addition, it adds much to the safety profile of the obturator bypass. However, the results must be treated cautiously, as it is a major surgery and a sufficient number of cases is crucial to building up the evidence.

Massive bleeding, systemic infections, extreme limb ischemia, and septic embolism are a few possible side effects (5).

Effective management of arterial or prosthetic graft infection requires the removal of the infected segment or graft, adequate debridement, and restoration of circulation (6).

Either an in situ or an extra-anatomic prosthetic bypass may be used to restore arterial circulation. The most popular extra-anatomic bypasses for lower-limb revascularization in situations of groin infections are the obturator and lateral femoral bypasses (7).

This procedure's justification is to prevent polluted, infected, or damaged tissues in the groin by constructing an arterial conduit from the aortoiliac section to the superficial femoral, popliteal, or deep femoral artery, depending on run-off circumstances (8). The femoral triangle is avoided by directing the vascular graft via the obturator foramen, dorsally to the hip joint, in a layer between the adductor magnus and longus muscles. It has been shown that autologous saphenous vein provides satisfactory outcomes and lowers the risk of subsequent graft infection (9).

Our goal was to assess the safety and efficacy of extra-anatomical bypass obturator in patients with groin infections.

Figure 1. Planning of exposure

Methods

A prospective cohort research on a convenient sample of 100 patients with groin infection who planned to do an extra-anatomical obturator bypass at the Vascular Surgery Department, Al Azhar University hospitals from January 2019 to May 2020. Al-Azhar University Local Ethics Committee approved the research procedure, and a signed informed consent was acquired from each patient.

We included all cases with groin infections who were fit for surgery during the study period.

Clinical evaluation and history-taking were performed for all patients. Ultrasonography with duplex scanning is a good initial modality to assess groin masses. Combination of computed tomography or magnetic resonance imaging with indium-labeled leucocyte scintigraphy.

Operative Technique

The aorta or the ipsilateral common iliac artery provides inflow. Based on the patient's anatomy and the surgeon's discretion, either a transperitoneal or retroperitoneal method may be used to expose inflow channels. PTFE, autologous saphenous vein, and cryopreserved cadaveric saphenous vein are available as conduit options. The diameter of the autologous tissue and the necessary length of the graft has an impact on the conduit options. The majority of patients in our study had PTFE conduit because doctors chose it because of the concerns about vein kinking during tunneling. Peripheral pulses were measured and recorded before surgery. The patient was placed supine with a little towel (Figure 1) or bump under the hip ipsilateral to bypass insertion if a retroperitoneal route was used. When necessary, the patient was then prepared from the xiphoid to both lower extremities. The external oblique was then separated by making a curvilinear incision parallel to its fibers in the ipsilateral lower quadrant. Incisions were made at the transverse abdominis and internal oblique muscles' insertion locations. One should continue with a typical infrarenal abdominal aortic exposure if employing a transperitoneal technique. To enable iliac exposure, a table-mounted retraction mechanism, such as an Omni or Bookwalter, was installed. The common iliac artery was separated from its surroundings and ringed by loops of elastic vascular tissue. The superficial femoral artery (SFA) was dissected proximally to the entry into Hunter's canal and distal to the afflicted groin (Figure 2). A conventional popliteal exposure (Figure 3) was acquired above or below the knee if the popliteal artery was used for distal outflow. Circumferential silastic vessel loops should be used to provide proximal and distal control.

Tunneling was done beginning with the retroperitoneal incision via the obturator foramen flowing through the medial thigh posterior to the adductor longus after proper vascular exposure. Dissection was done medial to the iliac bifurcation until the pubic bone was reached if employing a transperitoneal technique. The obturator foramen had to be felt posteriorly and medially, as well as the superior pubic ramus. The obturator membrane was cut when the obturator internus muscle was first bluntly removed. The obturator membrane is difficult to pierce and would need a clean cut. It is done similarly to puncturing the chest wall to implant a surgical chest tube, commonly with the point of a clamp. The retroperitoneal incision was used to insert a curved Kelly-Wick tunneler, and the bullet end was felt when it passed into the foramen. To avoid the obturator neurovascular bundle, which is conventionally believed to reside on the lateral side of the foramen, the tunneler should enter the foramen from the anteromedial aspect. The obturator artery has a large variety of anatomical variants. The anterior

branch of the hypogastric artery is where the obturator artery originates in the majority of people. However, reports of inferior epigastric artery origin have also been made. In this treatment, the physician must be wary of a "corona mortis." The origin of the obturator foramen may also be triangulated using multiplanar fluoroscopy. To follow the route of least resistance, tunneling moves in an oblique or lateral direction after entering the foramen. To reduce the visceral damage, notably harm to the bowel and bladder, fluoroscopic guiding ensures that tunneling follows the proper trajectory. Similarly, tunneling may similarly start along the adductor longus but reverse from the medial thigh counter-incision toward the retroperitoneal incision. The first tunneling location should be chosen based on patient anatomy, physician comfort, and personal taste. The tunnel was filled with and lengthened using a 7-8 mm externally supported ringed polytetrafluoroethylene (PTFE) graft (or another conduit option). The patient should receive a bolus of 80 units of unfractionated heparin per kilogram before being clamped. The end-to-side anastomosis was used for the proximal joint (Figure 4). Before executing the distal anastomosis, cleanse the graft. To verify patency, Doppler signals should be examined distal to the bypass. Multiple layers should be used to seal incisions.

Follow-up

Regular check-in intervals ranged from one month to three years. The grafts have undergone routine duplex scanning and clinical evaluation. Angiography using computed tomography (CT) was performed.

Outcome

The patency rate represented the primary outcome. The time of re-intervention was recorded, including its details to differentiate primary from secondary patency. Primary patency is defined as the absence of any intervention to preserve the patency, while secondary patency was recognized if the bypass was still patent after re-intervention for stenosis or thrombosis. Otherwise, the blood flow in targeted arteries was used to define patency. Secondary outcomes include mortality and different complications (10).

The primary outcome was considered a measure of procedure effectiveness, while the incidence of complications was considered a measure of procedure safety profile.

Statistical analysis

SPSS (statistical software for social research), version 25, was employed to analyze the data (IBM®, Armonk, NY, USA). For qualitative (categorical variables), relative frequencies and percent distributions were calculated. For quantitative data, the normality of data was tested by Kolmogorov–Smirnov. The mean and standard deviation (SD) were calculated for normally distributed variables, while the median and range were used for non-normally distributed data. Estimating patency rates was done with the Kaplan-Meier technique.

Results

A total of 100 patients (117 limbs) with groin infections

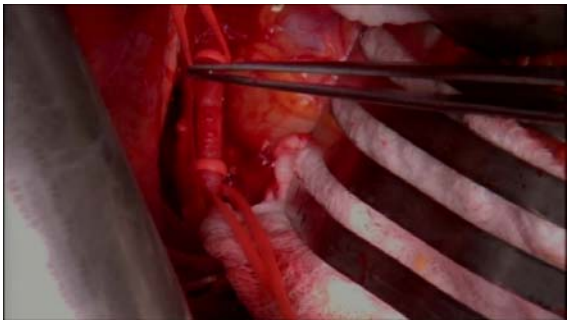

Figure 2. Exposure of obturator artery

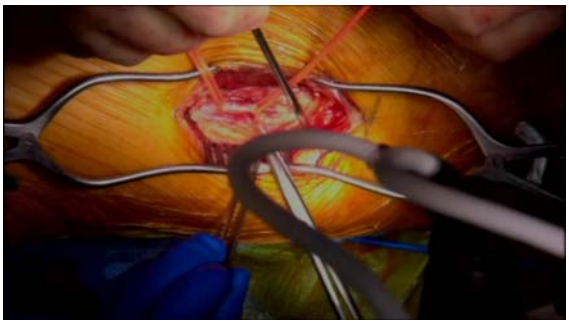

Figure 3. Exposure of popliteal artery

Figure 4. Completion of anastomosis through the obturator artery

were involved in this research. Their mean±SD age was 54.72 + 8.24 years, with a range of 24 to 68 years. The majority were males (62%). Comorbidities are summarized in Table 1.

Inflow from the already-existing graft limb was used in 54% of OCB procedures, with 32 limbs coming from the common iliac (27.3%) and 6 limbs from the infrarenal aorta (5.1%). The distal superficial femoral artery was selected in 21 limbs (17.9%), and the above-knee popliteal artery in 82% of cases.

Regarding intervention needed after OCB surgery, 7 (6%) patients needed OB thrombectomy, and 4 (3.4%) needed OB thrombectomy with graft stenting, right femoral to left SFA bypass was done in 2 (1.7%) patients. Revision OCB distal anastomosis was undergone in 2 (1.7%) patients (Table 2).

The follow-up period varied from 8 to 35 months, with a median of 26 months. During follow-up, eighteen patients were misplaced. Operative times varied from 114 to 360 minutes, with a median of 215 minutes. The median blood loss was 800 mL, although the range was 300 to 2500 mL (Table 3).

Regarding postoperative complications, superficial

Table 1. Demographic data of studied patients

Variable		Cases (n=100)	
		No	%
Age (year)	Mean ±SD	54.72 ± 8.24	
	Range	24 - 68	
Gender	Male	62	62%
	Female	38	38%
Comorbidity	Cardiac diseases	9	9%
	Diabetes mellitus	13	13%
	Hypertension	21	21%
	Renal diseases	6	6%

Table 2. Type of reintervention needed after obturator canal bypass

Variable	Limbs (n=117)	
	No	%
OB thrombectomy	7	6
OB thrombectomy with graft stenting	4	3.4
Right femoral to left SFA bypass	2	1.7
Revision OCB distal anastomosis	2	1.7
Total	15	12.8

SFA: superficial femoral artery.

Table 3. Operative data of studied patients

Variable		Cases (n=100)
Follow-up (month)	Median	26
	Range	8 - 35
Operative time (minute)	Median	215
	Range	114 - 360
Blood loss (mL)	Median	800
	Range	300 - 2500

Table 4. Post-operative complications of studied patients

Variable	Limbs (n=117)	
	No	%
Superficial Wound infections	9	7.7%
Deep venous thrombosis	5	4.3%
Above-knee amputation	3	2.6%
Total	17	14.5%

wound infection occurred in 9 limbs (7.7%) (7 due to Staphylococcus aureus, 1 Pseudomonas aeruginosa, and 1 Escherichia coli), deep vein thrombosis (DVT) in 5 (4.3%) and above-knee amputation in 3 (2.6%) patients (Table 4). All infections were mild and treated by responding to broad-spectrum antibiotics according to the department policy. We reported that 30- the day mortality rate was 3.4%.

Kaplan-Meier analysis was used to assess primary patency, which was 63% at 24 months (Figure 5); primary assisted patency was 68% at 24 months (Figure 6). At 24 months, the secondary patency of the OCB was 83% (Figure 7). Mean estimates of patency are presented in Table 5.

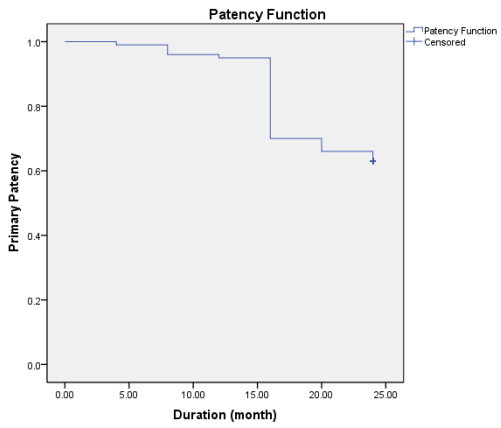

Figure 5. Primary patency at 24 months

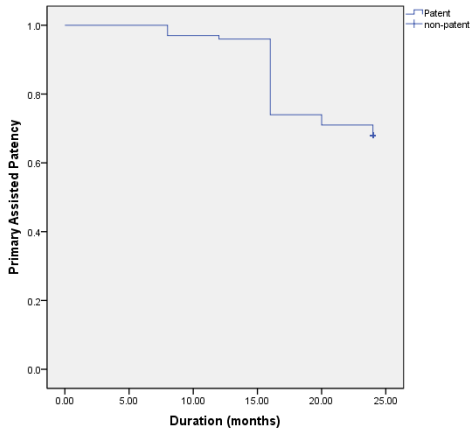

Figure 6. 24-month primary assisted patency

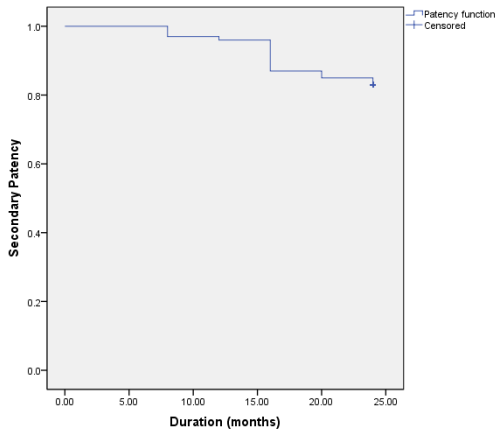

Figure 7. 24-month secondary patency

Discussion

Obturator bypass is primarily performed to preserve the continuity of the novel graft away from the infection site and to guard the graft against bacterial contamination (11, 12). Additionally, using muscular flaps is necessary to maintain graft functionality and guarantee effective wound healing (4, 13). The surgeons must be skilled and knowledgeable about the local anatomy. Injury to the obturator artery and nerve, which travel through the lateral superior edge of the obturator canal, is the most frequent consequence. Hip adduction and movement may be reduced as a consequence of obturator nerve injury. The rupture of the bladder and a false aneurysm of the graft itself are further dangers. The obturator bypass also has the drawback of requiring a big surgical site for the pathway's construction (14, 15).

There are no defenses against the complicated and deadly

Table 5. The Means and Medians for patency time

variable	Mean			
	Estimate	Std. Error	95% Confidence Interval	
			Lower Bound	Upper Bound
Primary patency	21.040	0.465	20.129	21.951
Primary assisted patency	21.52	0.425	20.686	22.354
Secondary patency	22.60	0.375	21.865	23.335

nature of groin infection, which has been associated with a 17% reported fatality rate and a 41% reported amputation rate (16). As a result of its depth and distance from the affected region, we believe that OBG is a suitable alternative.

There have been no prospective studies on infrainguinal arterial infections. However, statistics on morbidity and death have been recorded in a sizable number of case reports and case series. Dubouis et al. (10) reported on obturator bypass for 23 limbs in 22 patients. As in the current study, their patients were mainly males. However, their mean age is higher than the current work. The median operative time was 224 minutes and the median blood loss was 900 ml. These results are comparable to the current work. They added the primary patency rates were 84%, 78%, and 63%, in the first, second, and third years respectively. Their secondary patency rates were 94%, 94%, and 80%, in the first, second, and third years respectively.

Masaki et al. (4) revealed that 16 patients received OFB at their facility, and a 12.5% in-hospital death rate and a 6.25% major amputation rate were also recorded. According to data on this series' long-term survival at 5 years, 55%. A study by Bath et al. (17) involved 18 individuals who underwent OFB was investigated to ascertain long-term results. They discovered that 81% of patients were amputation-free after 3 years, and 83% of patients lived to that point.

Numerous case series have reported long- and short-term patency rates. Bath et al. (17) revealed main and secondary patency rates for their series at 24 months of 65% and 88%, respectively. It's interesting to note that two perioperative fatalities were excluded for non-atherosclerotic grounds.

It was crucial to pay attention to the finer aspects to ensure that the graft would run straight (18). Follow-up CT angiographies might reveal this. Other investigators also employed an 8 mm PTFE graft (19).

Mortality rates range from 0% to 17%, depending on the series, with the following parameters playing a role in fatalities: atherosclerotic disease, germ virulence, patient age or general health, or surgical group experience (20).

When working with vascular grafts, there is a harmful consequence that invariably arises: graft thrombosis. Because both femoral arteries are often strangulated and collateral vessels are sacrificed in surgery, this is a serious problem that might cause severe ischemia symptoms and jeopardize the viability of the limb. The OBG should be immediately subjected to thrombectomy or thrombolysis in those situations. We performed a thrombectomy on 11 (9.4%) of the limbs in our research.

We reasoned that an autologous vein would not have been appropriate in the presence of severe fibrosis in the groin and that extraanatomical OBG would be a superior solution. As the groin infection is often simpler to treat with an "in situ" method, we do not support this procedure as a first step. The OBG may be a useful option if carried out correctly when the latter is not feasible or advised due to a pathogenic bacterium.

Conclusion

When "in situ" repair is neither feasible nor advised, obturator bypass grafting is a suitable option to restore the flow in groin infection instances. Although this transplant involves considerable surgical expertise and solid anatomical knowledge, it is safe, effective, and permanent. Due to its high patency rate, it should be taken into account as a first choice in certain situations.

Acknowledgments

Prof. M. Helmy, for his assistance.

Conflict of Interests

The authors declare that they have no competing interests.

References

1. Caicedo D, Requena J, Villardefrancos R. Obturator Foramen By-Pass Graft for Groin Infection: Case Report and Literature Review. J Surg. 2016; 2016: J105.
2. Elens M, Dusoruth M, Astarci P, Mastrobuoni S, Bosiers MJ, Nardella J, et al. Management and Outcome of Prosthetic Vascular Graft Infections: A Single Center Experience. Vasc Endovascular Surg. 2018; 52(3):181-187.
3. Muthanna DR, Sabah N, Mohammed H, Hussien U. Extra-Anatomic prosthetic bypass grafts in management of Sub-inguinal vascular infections. Al-Kindy College Medical Journal. 2014 Jun 30;10(2):19-20.
4. Masaki H, Tabuchi A, Yunoki Y, Kuwata N, Tamura T, Honda T, et al. Long-Term Results of Obturator Bypass. Ann Vasc Dis. 2016;9(2):80-4.
5. Wilson WR, Bower TC, Creager MA, Amin-Hanjani S, O'Gara PT, Lockhart PB, et al. Vascular Graft Infections, Mycotic Aneurysms, and Endovascular Infections: A Scientific Statement From the American Heart Association. Circulation. 2016 Nov 15;134(20):e412-e460.
6. Andercou O, Marian D, Olteanu G, Stancu B, Cucuruz B, Noppeney T. Complex treatment of vascular prostheses infections. Medicine (Baltimore). 2018 Jul;97(27):e11350.
7. Zhang YG, Guo XL, Song Y, Miao CF, Zhang C, Chen NH. Diagnosis and Treatment of Vascular Surgery Related Infection. Open Biomed Eng J. 2015 Sep 17;9:250-5.
8. Conte MS, Bradbury AW, Kolh P, White JV, Dick F, Fitridge R, et al. Global vascular guidelines on the management of chronic limb-threatening ischemia. J Vasc Surg. 2019 Jun;69(6S):3S-125S.e40.
9. Dunphy KM, Hassey J, Vallabhaneni R, Alfawaz AA, Kiguchi MM, Fatima J, Woo EY, Abramowitz SD. Results of Obturator Foramen Bypass in Patients with Groin Infection and Arterial Involvement. Ann Vasc Surg. 2021 Aug;75:144-149.
10. Dubouis A, Gatinot A, Foret T, Rinckenbach S, Salomon Du Mont L. Obturator Bypass Remains a Useful Option. Ann Vasc Surg. 2022 Aug 1:S0890-5096(22)00434-4.
11. Altun G, Pulathan Z, Hemsinli D. Obturator bypass in the treatment of prosthetic graft infection: Classic but still effective. Turk Gogus Kalp Damar Cerrahisi Derg. 2018 Jul 3;26(3):480-483.

12. Engin C, Posacioglu H, Ayik F, Apaydin AZ. Management of vascular infection in the groin. Tex Heart Inst J. 2005;32(4):529-34.
13. Price A, Contractor U, White R, Williams I. The use of vascularised muscle flaps for treatment or prevention of wound complications following arterial surgery in the groin. Int Wound J. 2020 Dec;17(6):1669-1677.
14. Dobrovic K, Fila B, Janes A, Civljak R. Campylobacter fetus Bacteremia Related to Vascular Prosthesis and Pseudoaneurysm Infection: A Case Report and Review. Pathogens. 2022 Dec 14;11(12):1536.
15. Onoda M, Furutani A, Akiyama N, Morikage N, Yoshimura K, Hamano K. Infected aneurysms of bilateral deep femoral arteries due to Campylobacter fetus subspecies fetus. Ann Vasc Surg. 2008 May-Jun;22(3):476-80.
16. Etkin Y, Rao A, Jackson BM, Fishbein JS, Shyta K, Baig H, Landis GS. Infections of Prosthetic Grafts and Patches Used for Infrainguinal Arterial Reconstructions. Ann Vasc Surg. 2019 May; 57:152-159.
17. Bath J, Rahimi M, Long B, Avgerinos E, Giglia J. Clinical outcomes of obturator canal bypass. J Vasc Surg. 2017 Jul;66(1):160-166.
18. Ruangsetakit C, Chinsakchai K, Hahtapornsawan S, Wongwanit C, Sermsathanasawadi N, Mutirangura P. Successful outcome of obturator bypass surgery in infected femoral pseudoaneurysm: three cases report and literature review. J Med Assoc Thai. 2012 Mar; 95 (3):470-5.
19. Rabbani A, Moini M, Rasouli MR. Obturator bypass as an alternative technique for revascularization in patients with infected femoral pseudoaneurysms. Arch Iran Med. 2008 Jan;11(1):50-3.
20. Busch A, Lorenz U, Tiurbe GC, Bühler C, Kellersmann R. Femoral vein obturator bypass revascularization in groin infectious bleeding: two case reports and review of the literature. J Med Case Rep. 2013 Mar 18; 7:75.