

Migration of the Gamma Nail Neck Screw into the Pelvis with Bladder Damage

Ergali Nabiye¹, Ramazan Askerov², Khadisha Kashikova^{2*}, Arnat Baizakov², Zhassulan Argynbayev², Zhenisbek Baubekov³, Kuanysh Baikubesov⁴

Received: 12 Sep 2023

Published: 22 May 2024

Abstract

Background: Medial migration of the cervical screw is a frequent complication of Gamma nails and is observed in 4.3% - 6% of cases. The reasons are a violation of the surgical technique of osteosynthesis of a trochanter fracture, including an unrepaired fracture, a breach of the insertion point of the fixator, and a suboptimal position of the cervical screw. However, the migration of the Gamma nail neck screw into the pelvic cavity is sporadic, and only a few cases have been published in the literature.

Case description: This is the case of a patient born in 1952 who was admitted to the hospital with pain syndrome in the pelvis and dysuric phenomena. As a result of clinical X-ray examination, CT, and MRT examination of the pelvis, medial migration of the Gamma nail cervical screw with damage to the bladder was revealed. The patient was urgently operated on the day of admission. The cervical screw from the bladder was removed, the bladder was sutured, and an epicystostomy was installed. The Gamma nail from the right femur was also released. There were no intraoperative complications. In the postoperative period, the patient was prescribed antibiotics and analgesics. The duration of hospitalization was six days. Being examined for five weeks after the operation, the patient does not make any particular complaints, walks without means of support, and the intertrochanteric fracture of the right femur fused incorrectly. The patient was offered an endoprosthesis of the right hip joint, but he and his relatives refused.

Conclusion: The traumatologist should be aware of the possibility of such complications after osteosynthesis and its associated risks. They should be able to recognize the etiological factors causing the medial migration of the cervical screw of the intramedullary retainer. If medial screw migration is detected, the traumatologist should assess the function of internal organs and the condition of the main vessels and take measures to safely remove the migrated fixator from the anatomical cavity of the body in one team with a surgeon, urologist and vascular surgeon.

Keywords: Trochanter Fracture, Osteosynthesis, Gamma Nail, Cervical Screw, Migration, Bladder, Perforation

Conflicts of Interest: None declared

Funding: None

***This work has been published under CC BY-NC-SA 1.0 license.**

Copyright© Iran University of Medical Sciences

Cite this article as: Nabiye E, Askerov R, Kashikova Kh, Baizakov A, Argynbayev Zh, Baubekov Zh, Baikubesov K. Migration of the Gamma Nail Neck Screw into the Pelvis with Bladder Damage. *Med J Islam Repub Iran*. 2024 (22 May);38:58. <https://doi.org/10.47176/mjiri.38.58>

The relevance of the topic

Fractures of the trochanter region of the femur are most common in elderly and senile people with osteoporosis

and are treated by an operative method for the early mobilization of patients (1, 2).

Many intraosseous rods have been proposed for the sur-

Corresponding author: Dr Khadisha Kashikova, hadisha.kash@gmail.com

¹ KazNMU named S.D. Asfendiyarov, Kazakhstan

² Kazakhstan's Medikal University "KSPH", Kazakhstan

³ West Kazakhstan, Marat Ospanov Medical University, Kazakhstan

⁴ Caspian University, International School of Medicine, Almaty, Kazakhstan

↑What is "already known" in this topic:

Intramedullary nailing systems have become popular in treating unstable fractures of the trochanteric region with positive clinical outcomes. The two most commonly used nailing systems are the Gamma nail and the proximal femoral nail PFN. Medial migration of the cervical screw is a frequent complication of Gamma nails but, the migration of the Gamma nail neck screw into the pelvic cavity is rare.

→What this article adds:

This study reported a rarely described complication of osteosynthesis of the right femur with the Gamma nail: the medial migration of the Gamma nail cervical screw with damage to the bladder. In case of medial screw migration, the function of vital organs and the condition of the main vessels should be assessed, then the fixator should be removed safely.

gical treatment of fractures of the trochanter femoral region. The most popular are the Gamma nail and the proximal femoral nail PFN (3, 4).

Currently, the intramedullary nail fixation system, including Gamma nails, PFNA, and Gamma 3 (TFN), is more commonly used than extramedullary implants (5). Their advantages are minimal surgical trauma, short operation time, and firm fracture fixation. In addition, intramedullary rods may be helpful in the treatment of unstable and subtrochanteric femoral fractures (6).

According to most researchers, intramedullary osteosynthesis of trochanteric femoral fractures is the preferred treatment method, especially for unstable fractures, due to its biomechanical advantages (7-9).

For osteosynthesis, the most common complications are fracture of metal structures, suppuration of a postoperative wound, post-traumatic osteomyelitis, marginal necrosis of the injury, and migration of metal structures. Each of these complications proceeds differently. So, a broken system is removed with subsequent replacement and “flows without features” in a complicated version. The metal structure can migrate and perforate internal organs and large vessels during its movement (10, 11).

Complications associated with Gamma nails have been repeatedly reported in the literature: migration of the cervical screw is the most frequent complication (observed with a frequency of 3%-10%), especially medial migration of the cervical screw is an exceptionally unique complication (12-16).

According to Tsai S.W. et al. and Bojan AJ et al. I., medial migration of the cervical screw is the most common complication of the Gamma 3 fixator and is observed in 6%-4.3% of cases. The reasons are a violation of the surgical technique of osteosynthesis of a trochanter fracture, including an unrepaired fracture, a breach of the insertion point of the fixator, and a suboptimal position of the cervical screw (17, 18). However, the Gamma nail neck screw migration into the pelvic cavity is sporadic. Only a few cases have been published in the literature (17, 18).

The purpose of the study is to present a clinical case of a rare and life-threatening complication of osteosynthesis of a trochanter fracture - migration of the Gamma nail cervical screw into the pelvic cavity, complicated by damage to the bladder.

Methods

A clinical case of migration of the Gamma nail neck screw into the pelvic cavity, complicated by damage to the bladder, is described.

A clinical case. Patient A., born in 1952, was admitted to the hospital's surgical department on 18.07.2022 with complaints of paroxysmal pains in the lower abdomen, frequent urination, urinary incontinence, and pain in the right hip joint. These complaints appeared two months before admission. The patient did not seek medical help, and due to the deterioration of his general condition, only on 07/19/2022 he turned to a medical institution. From the patient's anamnesis, it turned out that on April 2, 2021, he received an injury to his right femur due to a fall on the street. He was delivered to the emergency room of the

hospital 1 hour after receiving the damage. After a clinical and X-ray examination, a clinical diagnosis was made: “Closed intertrochanteric fracture of the right femur with separation of the large and small trochanter” (Figure 1).

After preoperative preparation, a day later, the patient underwent osteosynthesis of the right femur with the Gamma nail under epidural anesthesia (Figure 2).

The postoperative period was completed without complications. The patient was discharged for outpatient treatment without immobilization.

Eight months after osteosynthesis of the right femur, the patient noted a deterioration in the general condition, increased pain in the right hip joint, intermittent pain in the lower abdomen, and frequent urination, and therefore took analgesics. The increase in paroxysmal pains in the lower abdomen, their non-coping with painkillers, and

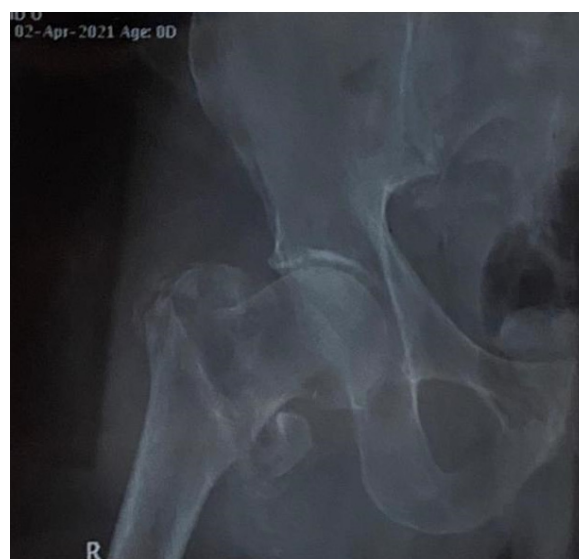

Figure 1. An anterior-posterior radiograph of the right hip joint shows an intertrochanteric fracture of the right femur with separation of the large and small trochanter.

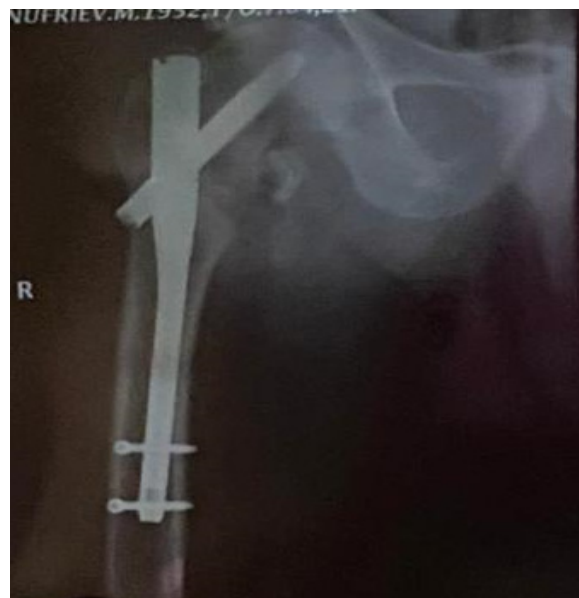

Figure 2. Anteroposterior radiograph of the right hip joint, demonstrating the reposition of an intertrochanteric fracture of the right femur with fixation of the fracture with a short Gamma nail.

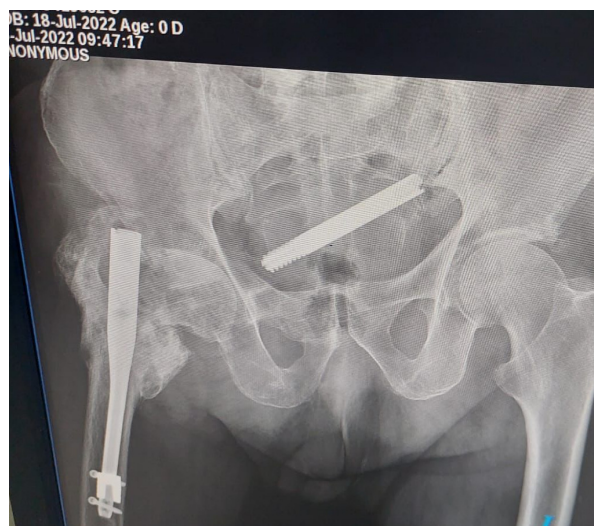

Figure 3. Anteroposterior radiograph of the pelvis, showing the medial migration of the Gamma nail cervical screw into the pelvic cavity eight months after osteosynthesis of the right femur, an irregularly grown intercostal fracture of the right femur

urinary incontinence were the basis for the patient's request for medical help.

Upon admission to the hospital's emergency department, the patient's general condition is of moderate severity. The skin is moderately pale, BH – 20 / min, heart rate – 90 beats/min, blood pressure – 130/80 mm Hg. The abdomen is not swollen, palpation is soft, not tense, the symptoms of irritation of the peritoneum are harmful, and there is pain in the lower parts of the belly and above the womb. A catheter removes urine with an admixture of blood.

An overview radiograph of the pelvis was performed for the patient (**Figure 3**). On the radiograph in the pelvic cavity, there is a metal foreign body - a Gamma nail neck screw up to 10 cm long and 7 mm thick, which migrated medially through the acetabulum, an irregularly grown varus intervertebral fracture of the right femur as a result of secondary displacement of bone fragments after migration of the metal tool neck screw - Gamma nail with two screws for distal blocking in the medullary canal of the thigh, destruction and osteoporosis of the head of the right femur.

The patient underwent CT and MRT pelvic examinations for a more accurate topical diagnosis. CT examination revealed no neck screw in the Gamma nail hole. It migrated and was freely located in the pelvic

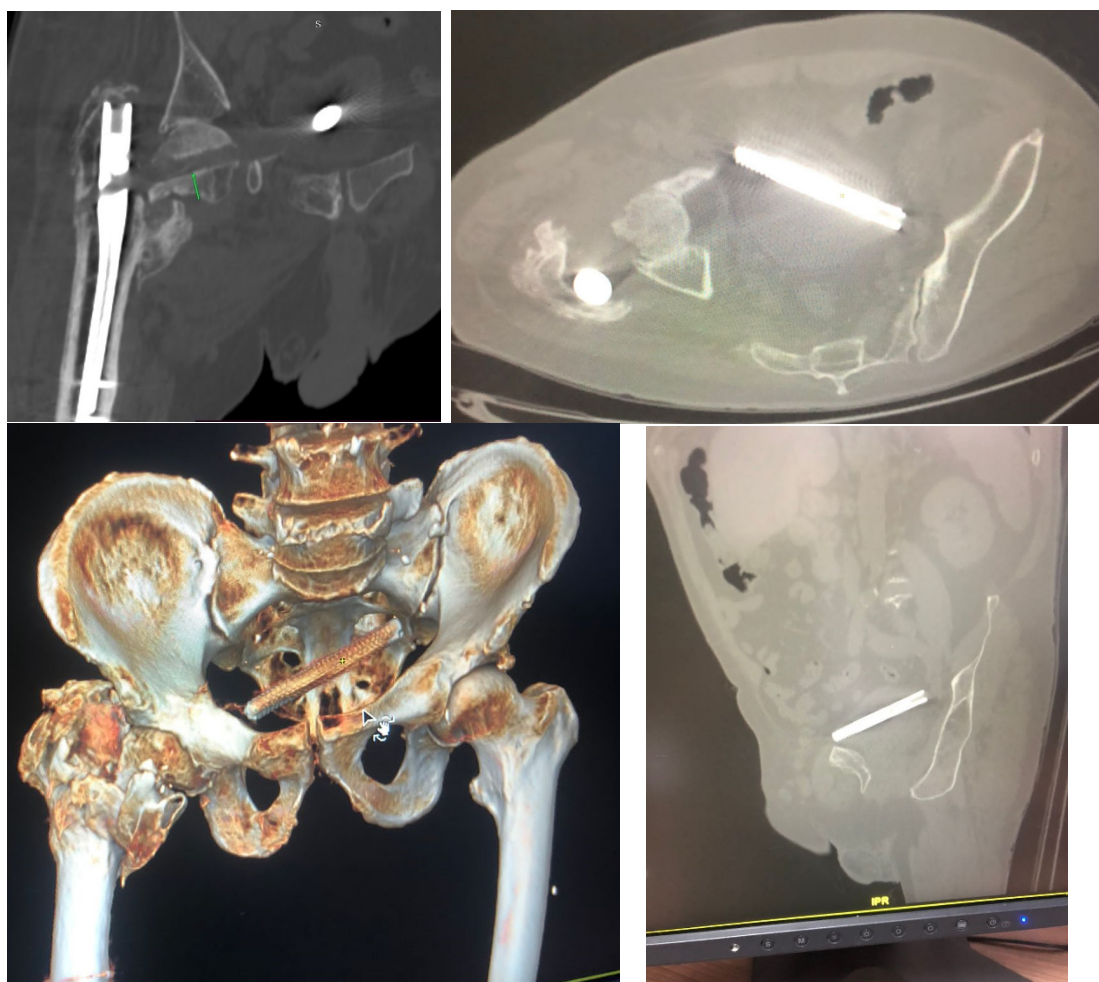


Figure 4. CT of the pelvis: the neck screw of the Gamma nail was freely located in the pelvic cavity, and the threaded part of the screw was directed toward the right hip joint

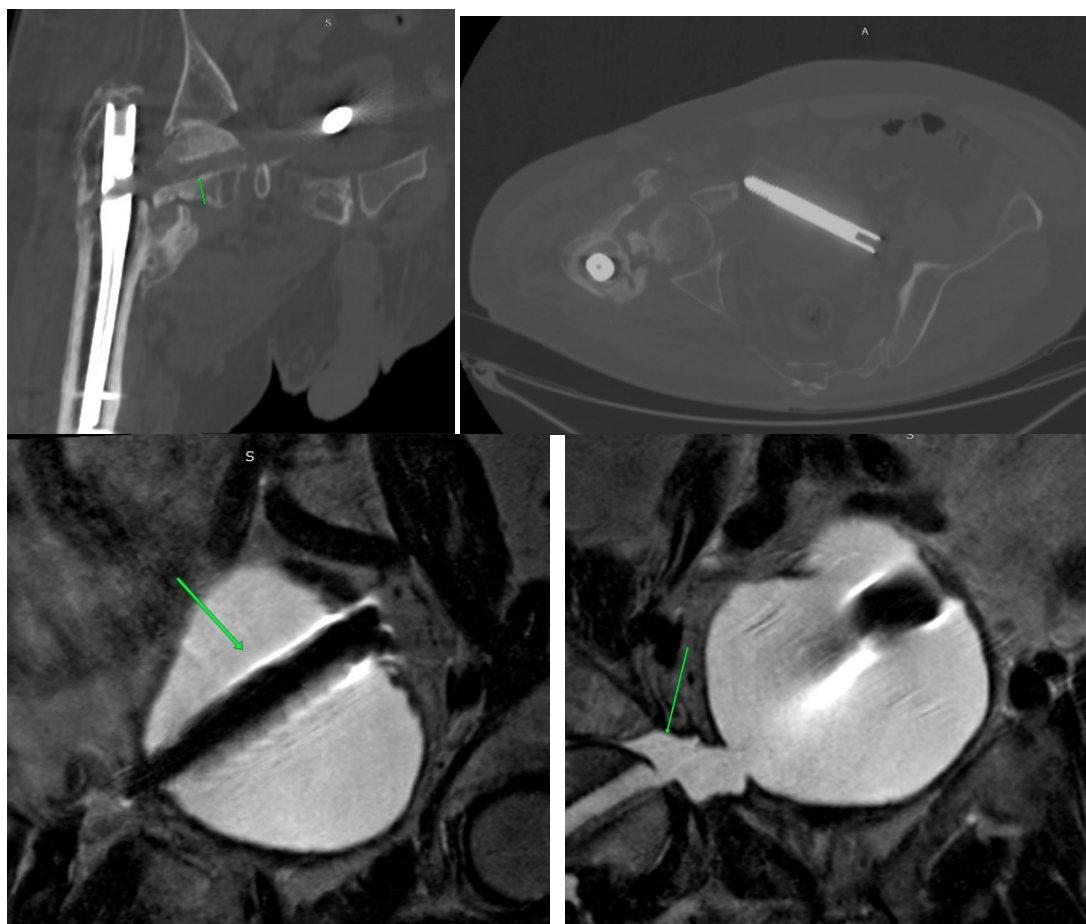


Figure 5. On an MRT of the pelvic organs: MR is a picture of a foreign body in the bladder cavity with a defect in the right wall.

cavity. The threaded part of the screw was directed towards the right hip joint (operated hip) (Figure 4).

On the MRT of the pelvic organs, an MR picture of a foreign body in the bladder cavity with a defect in the right wall of the bladder was established (Figure 5).

According to the results of a clinical X-ray examination, the patient was sent to the operating room to remove a foreign body. After a short preoperative preparation, the patient underwent surgery under endotracheal anesthesia – removal of a foreign body – a cervical screw from the bladder and a Gamma nail from the right femur. During the operation, a pronounced adhesive process was detected in the right iliac region, and the mooring lines were separated. A defect of 0.7 x 1.0 cm was found in the right wall of the bladder. The bladder was dissected, and a foreign body (a neck screw) lying freely in the cavity, with a threaded part facing the right half of the pelvis, which was removed without technical difficulties, was revealed. Suturing of the bladder wall was performed, and an epicystostomy was installed. Serous hemorrhagic effusion was found in the pelvic cavity. It should be noted that the gamma nail in the medullary canal was freely located and removed without any effort. Drains were installed, and stitches were applied to the wounds in layers. There were no intraoperative complications. In the postoperative period, the patient was prescribed antibiotics

and analgesics. The drainage tube was removed on the second day. The duration of hospitalization was six days. The patient was discharged under the supervision of a urologist and a traumatologist at the place of residence. The stitches were removed on the 11th day after the operation. Being examined five weeks after the operation, the patient does not make any particular complaints, feels satisfactory, and walks without means of support. The intervertebral fracture of the right femur fused incorrectly. The patient was offered an endoprosthesis of the right hip joint, but he and his relatives refused.

Discussion

According to previous studies, the advantage of the intramedullary fixation system of a proximal femur fracture is to reduce intraoperative blood loss, the time of surgery, and the early load on the operated limb. It is also reported that good results of using their fixation of unstable fracture of the proximal femur compared with bone fixators (19, 20).

Despite the widespread use of intramedullary fixators for osteosynthesis of proximal femur fractures, they are characterized by complications such as loss of repositioning and migration of the cervical screw. Medial migration of the Gamma nail neck screw is the most characteristic complication for this fixator. Few cases of

such a complication are described in well-known publications (21-29). For many researchers, the origin of such a complication is still unknown (30-33).

The causes may be iatrogenic damage to the femoral head during drilling of the femoral neck, improper installation of the neck screw, excessive early loading, repeated direct trauma leading to loosening of the screw, violation of the structure of the neck screw in the nail hole, etc. (30-33).

In this clinical case, we cannot declare any errors of osteosynthesis, as a result of which a medial migration of the cervical screw could occur. Judging by the radiograph from 07.04.2021, we can say that the reposition of bone fragments has been achieved well, the cervical-diaphyseal angle of the femur has been restored, the neck screw is installed correctly, the length of the neck screw is optimal, and dynamic and static screws block the proximal section of the Gamma nail. At first glance, all the stages of osteosynthesis are adequately performed.

Judging by the X-ray taken after eight months, it is possible to state the consequences of the secondary displacement of bone fragments, varus deformation of the proximal femur, migration of the intramedullary nail, and shortening of the thigh. The removal of the intramedullary retainer in the medullary canal (in the proximal direction) is indicated by the deformation of the dynamic and static screws. An etiological moment can be an early load or a direct injury, which the patient himself does not report. Violations of the neck screw installation technique, when the set screw does not fall into the grooves of the neck screw, could also serve as causal factors.

According to our assumption, due to the unstable nature of the intervertebral fracture of the femur as a result of early and active load on the operated limb, over time, the Gamma nail shifted within the intraosseous canal, which led to the migration of the cervical screw in the medial direction. Weil et al. described a similar mechanism of medial migration development in the results of biomechanical studies (19). Everyone knows that each neck screw has four grooves, and the correct position of the set screw in the grooves ensures lateral sliding and prevents rotation. In this case, the set screw could be outside the track, or the set screw was loosely tightened to dynamize the neck screw, leading to the migration of the neck screw.

Possible migration of the cervical screw into the pelvis is more likely to be observed in bone osteoporosis (34).

Conclusion

In the practice of an orthopedic traumatologist, the migration of metal structures is an infrequent complication. However, with the increase in the number of operations on the human musculoskeletal system, it still occurs. The migrated metal structure can damage internal organs and main vessels and threaten the patient's life. In particular, the cervical screw of the intramedullary fixation system of a femoral fracture, due to certain biomechanical features of the hip joint, as a result of violations of the osteosynthesis technique, can migrate in the medial direction. The migration of fixators into the pelvic cavity, pleural, and

abdominal cavities are described. In this regard, the traumatologist should be aware of the possibility of such complications after osteosynthesis and its associated risks. The traumatologist should be able to recognize the etiological factors causing the medial migration of the cervical screw of the intramedullary retainer. If medial screw migration is detected, the traumatologist should assess the function of vital organs and the condition of the main vessels and take measures to safely remove the migrating fixator from the anatomical cavity of the body in one team with a surgeon, urologist and vascular surgeon.

Authors' contribution

All the authors took an active part in writing this article.

Conflict of Interests

The authors declare that they have no competing interests.

References

1. Ballane G, Cauley JA, Luckey MM, Fuleihan GEH. Secular trends in hip fractures worldwide: opposing trends East versus West. *J Bone Miner Res.* 2014;29:1745-1755.
2. Lix LM, Quail J, Teare G, Acan B. Performance of comorbidity measures for predicting outcomes in population-based osteoporosis cohorts. *Osteoporos Int.* 2011;22(10):2633-2643.
3. Mattisson L, Bojan A, Enocson A. Epidemiology, treatment and mortality of trochanteric and subtrochanteric hip fractures: data from the Swedish fracture register. *BMC Musculoskelet. Disord* 2018;19:369.
4. Lu Y, Uppal HS. Hip fractures: relevant anatomy, classification, and biomechanics of fracture and fixation. *Geriatr Orthop Surg Rehabil.* 2019;10:310.
5. Cheng Y, Sheng X. Optimal surgical methods to treat intertrochanteric fracture: a Bayesian network meta-analysis based on 36 randomized controlled trials. *J Orthop Surg Res.* 2020;15:402.
6. Jackson C, Tanios M, Ebraheim N. Management of subtrochanteric proximal femur fractures: a review of recent literature. *Adv Orthop.* 2018; 2018:1326701.
7. Valente M, Crucil M, Alecci V. Treatment of lateral femoral neck fractures with the Proximal Femoral Nail Antirotation (PFNA) GIOT. 2009;35:79-83.
8. Chen Q, Zhou Z, Guan L. Comparison of effects between two operating methods of treating intertrochanteric hip fracture with Gamma nail fixation. *Zhongguo Xiu Fu Chong Jian Wai Ke Za Zhi.* 2007;21(10):1027-1030.
9. Pelet S, Arlettaz Y, Chevalley F. Osteosynthesis of per- and subtrochanteric fractures by blade plate versus gamma nail. A randomized prospective study. *Swiss Surg.* 2001;7(3):126-133.
10. Mavrogenis AF, Panagopoulos GN, Megaloikonomos PD, Igoimenou VG, Galanopoulos I, Vottis CT, et al. Complications after hip nailing for fractures. *Orthopedics.* 2016;39:108-116.
11. Tubbax H, Hendzöl P, Sergeant P. Cardiac perforation after Kirschner wire migration. *Acta Chir Belg.* 1989;89:309-311.
12. Hesse B, Gächter A. Complications following the treatment of trochanteric fractures with the gamma nail. *Arch Orthop Trauma Surg.* 2004;124(10):692-698.
13. Kukla C, Heinz T, Gaebler C, Heinze G, Vécsei V. The standard Gamma nail: a critical analysis of 1,000 cases. *J Trauma.* 2001;51(1):77-83.
14. Socci AR, Casemyr NE, Leslie MP, Baumgaertner MR. Implant options for the treatment of intertrochanteric fractures of the hip: rationale, evidence, and recommendations. *Bone Joint J.* 2017;99-B:128-133.
15. Tauber M, Resch H. Sigmoid perforation after medial migration of lag screw in gamma nailing. *Arch Orthop Trauma Surg.* 2006;126(2):118-122.
16. Lasanianos N, Mouzopoulos G, Georgilas I. Hip screw lateral migration with no cut-out or non-union implication: a case report.

- Cases J. 2009;2:6419.
17. Tsai SW, Lin CFJ, Tzeng YH. Risk factors for cut-out failure of Gamma3 nails in treating unstable intertrochanteric fractures: an analysis of 176 patients. J Chin Med Assoc. 2017;80(9):587–594.
18. Bojan AJ, Beimel C, Taglang G, Collin D, Ekholm C, Jönsson A. Critical factors in cut-out complication after Gamma Nail treatment of proximal femoral fractures. BMC Musculoskel Disord. 2013;14:1.
19. Weil Y, Gardner M, Mikhail G, Pierson G, Helfet DL, Lorch DG. Medial migration of intramedullary hip fixation devices: a biomechanical analysis. Arch Orthop Trauma Surg. 2008;128:227-234.
20. Park SY, Yang KH, Yoo JH, Yoon HK, Park HW. The treatment of reverse obliquity intertrochanteric fractures with the intramedullary hip nail. J Trauma. 2008 Oct;65(4):852-7.
21. Sehat K, Baker RP, Pattison G, Price R, Harries WJ, Chesser TJ. The use of the long gamma nail in proximal femoral fractures. Injury. 2005;36(11):1350-1354.
22. Valente M, Crucil M, Alecci V. Treatment of lateral femoral neck fractures with the Proximal Femoral Nail Antirotation (PFNA). GIOT. 2009;35:79–83.
23. Chen Q, Zhou Z, Guan L. Comparison of effects between two operating methods of treating intertrochanteric hip fracture with Gamma nail fixation. Zhongguo Xiu Fu Chong Jian Wai Ke Za Zhi. 2007;21(10):1027-1030.
24. Pelet S, Arlettaz Y, Chevalley F. Osteosynthesis of per- and subtrochanteric fractures by blade plate versus gamma nail. A randomized prospective study. Swiss Surg. 2001;7(3):126-133.
25. Hesse B, Gächter A. Complications following the treatment of trochanteric fractures with the gamma nail. Arch Orthop Trauma Surg. 2004;124(10):692–698.
26. Lee JW, Cho HM, Seo JW. Intrapelvic penetration of lag screw in proximal femoral nailing: a case report. J Korean Fract Soc. 2017;30:203-208.
27. Brunner A, Jöckel JA, Babst R. The PFNA proximal femur nail in treatment of unstable proximal femur fractures—3 cases of postoperative perforation of the helical blade into the hip joint. J Orthop Trauma. 2008;22:731-736.
28. Nikoloski AN, Osbrough AL, Yates PJ. Should the tip-apex distance (TAD) rule be modified for the proximal femoral nail antirotation (PFNA)? A retrospective study. J Orthop Surg Res. 2013;8:35.
29. Lasanianos N, Mouzopoulos G, Georgilas I. Hip screw lateral migration with no cut-out or non-union implication: a case report. Cases J. 2009;2:6419.
30. Flint JH, Sanchez-Navarro CF, Buckwalter JA, Marsh JL. Intrapelvic migration of a gamma nail lag screw: review of the possible mechanisms. Orthopedics. 2010;33(4).
31. Lucke M, Burghardt RD, Siebenlist S, Ganslmeier A, Stöckle U. Medial migration of lag screw with intrapelvic dislocation in gamma nailing – a unique problem? A report of 2 cases. J Orthop Trauma. 2010;24(2):6–11.
32. Li X, Heffernan MJ, Kane C, Leclair W. Medial pelvic migration of the lag screw in a short gamma nail after hip fracture fixation: a case report and review of the literature. J Orthop Surg Res. 2010;50:62.
33. Lozano-Alvarez C, Alier A, Pelfort X, Martinez-Díaz S, Puig L. Cervicocephalic medial screw migration after intertrochanteric fracture fixation, OTA/AO 31-A2, using intramedullary nail Gamma3: report of 2 cases and literature review. J Orthop Trauma. 2013;27(11):264–267.
34. Leung K, So W, Shen W, Hui PW. Gamma nails and dynamic hip screws for peritrochanteric fractures. A randomized prospective study in elderly patients. J Bone Joint Surg Am. 1992;74:345-351.