




## A 12-year Life History of a Girl with Profound Intellectual Disability and Leukoencephalopathy: A Rare Clinical Presentation of X Chromosome Pentasomy

Akmaral Izbassarova<sup>1</sup>, Aisulu Zholdybayeva<sup>2</sup>, Galiya Kadrzhanova<sup>3</sup>, Khadisha Kashikova<sup>2\*</sup> , Asel Izbassarova<sup>1</sup>, Natalya Petrova<sup>2</sup>, Alima Tolybekova<sup>3</sup>

Received: 18 Apr 2023

Published: 10 Apr 2024

### Abstract

This paper presents a unique 12-year case analysis of a girl with Penta-X syndrome, a chromosomal abnormality characterized by five X chromosomes instead of the normal two in healthy women. Pentasomy of X is a genetic, but not a hereditary disease affecting only women. Our patient demonstrated delayed mental, speech, and motor development along with physical anomalies such as craniofacial deformities, and eye pathology and was diagnosed with pentasomy of the X chromosome at the age of 3 after a cytogenetic examination. She developed epileptic seizures at the age of nine. Magnetic resonance imaging (MRI) revealed leukoencephalopathy with ventriculomegaly. The peculiarity of this observation is that the polysomy 49, XXXXX detected in the patient is characterized by a typical phenotypic presentation combined with demyelinating leukoencephalopathy, which has not been a typical feature of the disorder.

**Keywords:** Pentasomy X, Chromosome Aberrations, Aneuploidy, Mental Retardation, Leukoencephalopathy

**Conflicts of Interest:** None declared

**Funding:** None

**\*This work has been published under CC BY-NC-SA 1.0 license.**

Copyright © Iran University of Medical Sciences

**Cite this article as:** Izbassarova A, Zholdybayeva A, Kadrzhanova G, Kashikova Kh, Izbassarova A, Petrova N, Tolybekova A. A 12-year Life History of a Girl with Profound Intellectual Disability and Leukoencephalopathy: A Rare Clinical Presentation of X Chromosome Pentasomy. *Med J Islam Repub Iran*. 2024 (10 Apr);38:40. <https://doi.org/10.47176/mjiri.38.40>

### Introduction

Chromosomal aberrations are a frequent cause of mental disability, accounting for 15% of all cases (1, 2). Diagnosis of chromosomal forms of mental disability is based on a complex of indicators obtained through clinical and cytogenetic examination (3). Chromosomal deviations can arise from changes in the number or structure of autosomes or sex chromosomes. The frequency of chromosomal diseases among newborns is approximately 1% (4, 5).

Sex chromosome polysomy is a large group of chromosomal diseases with different combinations of additional X- or Y-chromosomes and a variety of other clones in the case of mosaicism (4). The total frequency of sex chromosome

polysomy among newborns is 1.5:1000 - 2:1000, with mosaic types accounting for 25% of cases. Syndromes of X-chromosome polysomy include trisomy X (47, XXX), tetrasomy X (48, XXXX), and pentasomy X (49, XXXXX) (5). The additional X-chromosomes in these individuals are inactivated, making these pathological conditions viable despite the evident chromosomal imbalance. The severity of developmental anomalies, including mental disability, increases with an increase in the number of X-chromosomes (48, XXXX; 49, XXXXX). The diagnosis of X-chromosome polysomy is based on examination of the karyotype (6).

**Corresponding author:** Dr Khadisha Kashikova, [hadisha.kash@gmail.com](mailto:hadisha.kash@gmail.com)

<sup>1</sup> KazNMU named S.D. Asfendiyarov, Almaty, Kazakhstan

<sup>2</sup> Caspian University, International School of Medicine, Almaty, Kazakhstan

<sup>3</sup> Kazakhstan-Russian Medical University, Almaty, Kazakhstan

#### ↑What is “already known” in this topic:

Pentasomy of the X chromosome, results in a combination of craniofacial, skeletal, genital, and neuropsychiatric features.

#### →What this article adds:

This paper highlights the necessity for comprehensive genetic consultation and chromosome analysis in diagnosing syndrome-specific intellectual disabilities. It also expands the clinical understanding of the disorder, introducing a new associated feature: leukoencephalopathy.

Girls with tetra and pentasomy exhibit mental disability, maxillofacial dysmorphism, and anomalies of the teeth, skeleton, and genitalia (6). Polysomy 49, XXXXX is a sporadic chromosomal disease, with the first case being registered in 1963 (7). Pentasomy X-chromosomal anomaly affects only girls and is characterized by five instead of two X-chromosomes, leading to a karyotype of 49, XXXXX (5). The disorder occurs due to occasional errors during reproductive cell division in one of the parents (2). The natural frequency of X-pentasomy is currently unknown due to its rarity, varied phenotype, and accompanying symptoms.

We present the case of a currently 18-year-old girl who was diagnosed with pentasomy X at the age of 3, describing the clinical features of the disorder and its special features like leukoencephalopathy and relatively long survival to highlight the importance of cytogenetic examination in patients assessed for intellectual disabilities.

### Case Presentation

We present the clinical features of Pentasomy X syndrome in a girl (born in 2005) who was diagnosed at the age of 3 and followed up until the age of 15 years.

The patient was the firstborn child to healthy non-related parents (mother 22 years old and father 25 years old at the time of birth). She was born in 2005 in the first pregnancy of a 22-year-old mother at 42/43 weeks of gestational age. She had an Apgar score of 7 and weighed 2800 grams at birth. An isolated soft palate cleft was detected, pertaining it to intrauterine developmental defects. She had delayed motor, mental, and verbal development. She started walking independently at the age of three.


At the age of three, she was referred to the genetic department for cytogenetic examination due to concomitant cleft palate and ventriculomegaly. The patient exhibited a characteristic phenotypic picture, including a small head, a round face, low-set ears, micrognathia, a short neck with a low hairline on the forehead and neck, cleft palate (which had been surgically repaired at this visit), clinodactyly of the fifth fingers of the hands, small hands and feet, valgus deformity of the knee joints and feet, in addition to moderate mental retardation and general underdevelopment of speech (Figure 1). Additionally, she had ophthalmologic abnormalities, including congenital atrophy of chorioretinal tissue and moderate anisometric myopia with astigmatism. She had been treated under the diagnoses of infantile cerebral palsy (ataxic form), Mental disability, and Inborn ataxia with defused hypomyelination of the central nervous system.

Cytogenetic analysis based on cultured peripheral blood lymphocytes revealed the karyotype: 49, XXXXX, also referred to as Pentasomy of X (Figure 2). She was then kept under observation in the Republican Children's Clinical Hospital, following psychoneurological rehabilitation center with a diagnosis of polysomy 49 XXXXX associated with mental disability, one degree of speech underdevelopment, and an inborn isolated cleft of a soft palate (operated), and anisometric myopia with astigmatism.

On magnetic resonance imaging of the brain, leukoencephalopathy with ventriculomegaly was observed. The patient's motor activity, assessed with a Gross Motor

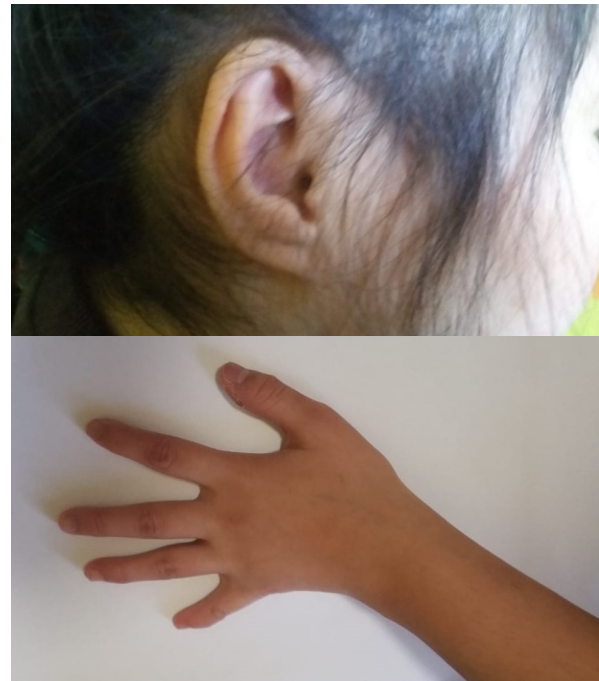

Figure 1. The patient had specific X pentasomy syndrome phenotypic characteristics of (49,XXXXX). Minor developmental anomalies attract attention: note flat middle part of the face, low-set ears, deformation of ear pavilion, short neck with a low line of hair on forehead and neck (The upper image). And talipes valgus, clinodactyly and brachydactyly of fifth fingers (The lower image).



Исследуемый материал: периферическая кровь.  
Кариотип  
49, XXXXX  
Заключение: Полисомия по X-хромосоме

Figure 2. The patient's karyotype of cultured peripheral lymphocytes showing a 49, XXXXX pattern characteristic of X-chromosome polysomy.

Function Classification System (GMFCS), was at level 2, and the Upper Limb Functioning Scale Manual Ability Classification System (MACS) was at level 1. A modified Bartel daily activity index of 75 points (maintenance with the help of another person) and a functional independence scale (FIM) of 70 points (average degree) were recorded as her level of functioning. She also developed epileptic seizures when she was nine.

### Follow-up on the patient's clinical status

At 15 years (the last visit to our clinic), the patient had a typical personal appearance with a flat middle part of the face, low-set ears, short neck with a low-set hairline on the forehead and neck. She could not communicate appropriately due to her underdeveloped thought processes and speech. She had primary amenorrhea and lacked secondary genital development like breast buds and hair growth in her underarms and genitalia. The parents did not report an increased rate or severity of infections. Basic self-care skills were not present, and cleanliness skills were partially present.

Her speech was word-bound, unclear, and nasalized. Her vocabulary was poor and limited to 20 single words. Her thinking was concrete, rigid, and inconsistent. Complex mental operations were impossible because of evident intellectual underdevelopment and rapid wear-out. Perception and memory were also underdeveloped. She had a short attention span and was highly distractible. Her interest was limited to eating; of which she would demand in an excess amount (hyperphagia).

She received multi-disciplinary care from a psychiatrist, logopedist, ophthalmologist, and orthopedist for different aspects of her disorder.

At nine years, the girl developed seizures with severe attacks until she was ten years old when her seizures were controlled with the anticonvulsant, Convulex (Valproic Acid).

Her neurological examination was significant for muscular hypotonia syndrome with brisk tendon reflexes and mild ataxia. She was clumsy and had disturbances in her balance and movement coordination; she also had difficulty switching from one object to another.

### Paraclinical Aspects

Brain CT suggested a periventricular leukomalacia with internal hydrocephaly (Figure 3). Brain MRI was consistent with leukoencephalopathy of non-defined origin (Figure 4).

In the electroencephalogram (EEG), the sleep-state rhythmic cortical discharge was disorganized. Physiological transitions of sleep were present, albeit ill-defined. The following abnormalities were also notable: regional sporadically scattered isolated epileptiform activity, mainly in frontal, central, and dorsal derivations, short episodic periods of diffuse secondary bilateral rhythmic synchronization with a pattern progressing with sleep deepening. The amplitude was the highest and arose from frontal, central, and temporal regions, and sometimes on parietooccipital derivations; with amplitude tone discharge on the right.

Electromyography was conducted on the arms and legs' muscles. With voluntary muscle contraction, 1 type of EMG was registered with decreased amplitude up to 200 mV. During EMG, no spontaneous activity was detected.

Echocardiography showed a non-expanded cardiac cavity. A first-degree prolapse of mitral valve anterior leaflet (0.6 cm). Myocardial contractility was normal.

### Discussion

In the reported case, polysomy 49 XXXXX, which was diagnosed when the patient was three, presented a typical phenotype of the disease with a combination of profound intellectual disability with inborn isolated cleft palate, typical appearance, clinodactyly of the fifth fingers with ventriculomegaly and leukoencephalopathy. Demyelinating leukoencephalopathy was the unique feature of our patient.

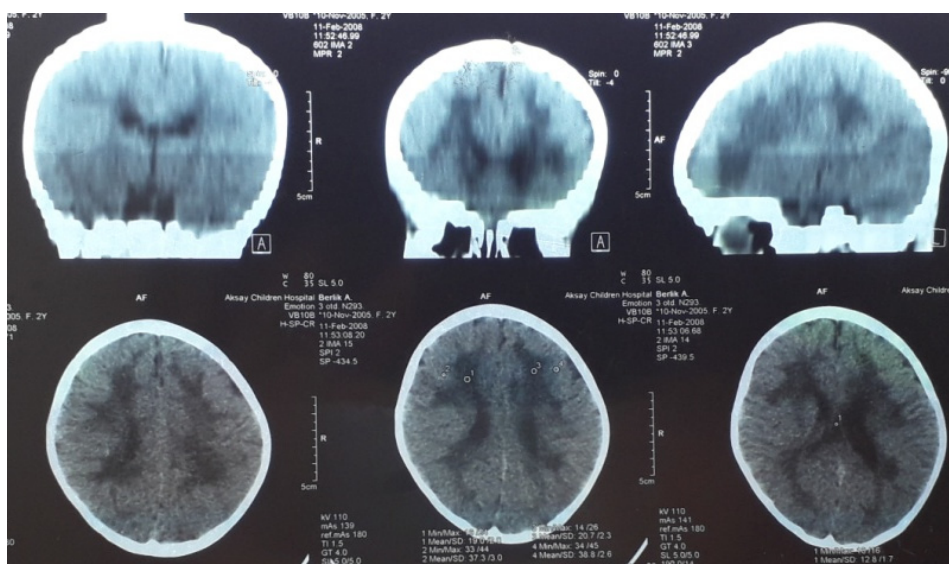
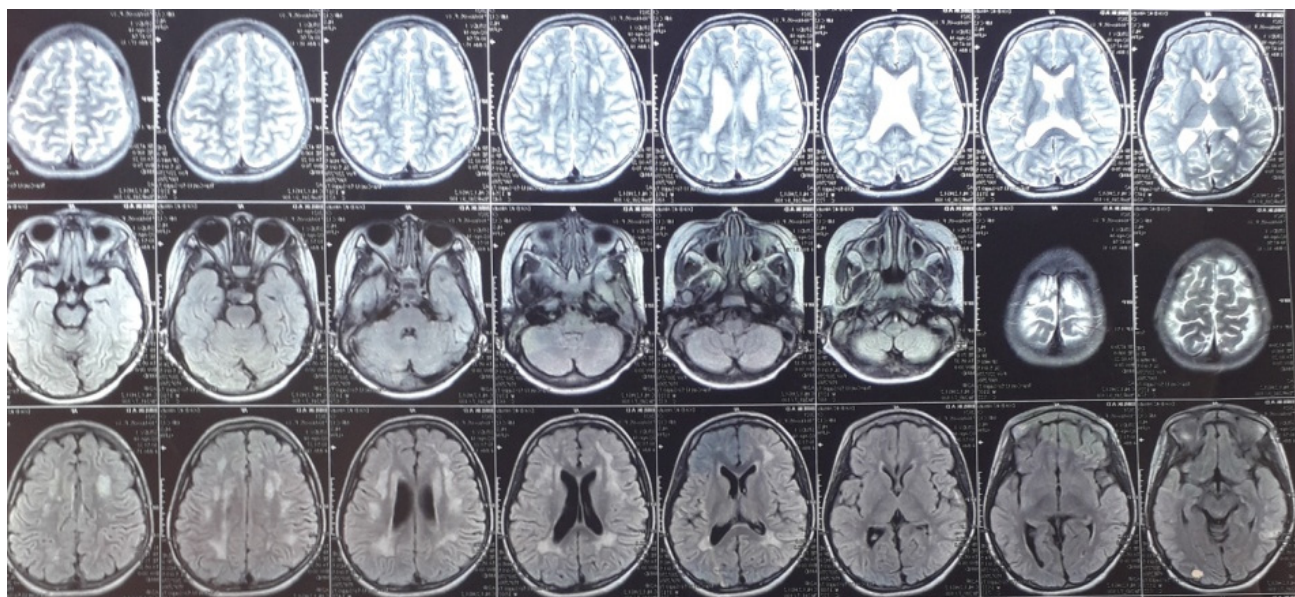


Figure 1. Computer tomography of a brain in a series of CT scans – The sulci convexity is smoothed. The subarachnoid cavity in the parietal-frontal space is expanded. Parasagittal and Midline structures are not displaced. In periventricular sections of the brain, decreased density of white matter zones up to 10-20 Hanzfield units. Moderate and symmetrical expansion of the tricorn is noted. Parasellar sections, cerebellum, and orbits are not changed.



**Figure 2.** Magnetic resonance imaging of the brain: FLAIR, T2, and T1 weighted images of sub and supratentorial brain structures in white substance periventricular showed zones with MP's high intensity – signals until the border of the grey matter of the brain. No evidence of mass lesion was identified. The craniocervical junction, stem brain divisions and tentorium don't have any local changes. Midline cerebral structures are not dislocated. Extracerebral liquor spaces are not expanded. The cerebral ventricles' volume is slightly extended; symmetry is preserved. Tentorium glands are located somewhat higher than Chamberlain's line.

Different case reports on Penta X Syndrome describe various clinical features, and the rate of individual features such as leukoencephalopathy in these patients is not well-established due to the rarity of the condition (8). To the best of our knowledge, cerebral leukodystrophy was reported as an additional finding in a 3-year-old patient with pentasomy X who had presented with refractory epileptic seizure (9).

Females with 49, XXXXX may present with a range of different symptoms such as craniofacial dysmorphism, cleft palate, teeth anomalies, underdevelopment of genitalia, epileptic seizures, clinodactyly (finger arcuation), dysmelia (small-sized, adherence of radial and elbow bone), congenital heart diseases, and unusual personal appearance. The severity of hypotonia at birth may be a prognostic factor (10). Our patient has most of the reported features except for serious heart defects plus the significant imaging finding of leukoencephalopathy. Notably, our patient had a longer follow-up (12 years) than most previously reported cases.

Polysomy 49, XXXXX is a sporadic chromosomal disease (11). The disorder occurs due to occasional errors during meiosis in one of the parents, which is referred to as nondisjunction (2, 12). Non-disjunction is a process that occurs during meiosis, where chromosomes fail to separate properly, resulting in parental gametes with either more or less than the normal haploid number of chromosomes (3). This can lead to chromosomal aberrations in the resulting zygote, which may be either trisomic for the chromosome involved or deficient in one chromosome (4). Non-disjunction can occur during meiosis I or meiosis II, or both and it is the leading cause of pregnancy loss and birth defects (12, 13).

### Conclusion

This case report highlighted a rare clinical presentation of a female patient with signs of penta X syndrome. The patient's polysomy 49, XXXXX was accompanied by a characteristic phenotypic picture of the disease combined with demyelinating leukoencephalopathy. The diagnosis of X-chromosome polysomy is based on examination of the karyotype. Genetic consultation and cytological examination are essential for diagnosing syndrome-based profound intellectual disabilities, especially when in combination with other syndromic features.

### Conflict of Interests

The authors declare that they have no competing interests.

### References

- Schoubben E, Decaestecker K, Quaegebeur K, Danneels L, Mortier G, Cornette L. Tetrasomy and pentasomy of the X chromosome. *Eur J Pediatr.* 2011;170(10):1325-7.
- De Falco L, Suero T, Savarese G, Savarese P, Ruggiero R, Di Carlo A, et al. Non-Invasive Prenatal Screening: The First Report of Pentasomy X Detected by Plasma Cell-Free DNA and Karyotype Analysis. *Diagnostics (Basel).* 2022;12(7).
- Hirschhorn K, Cooper HL. Chromosomal aberrations in human disease: A review of the status of cytogenetics in medicine. *Am J Med.* 1961;31(3):442-70.
- Johnson NA, Lachance J. The genetics of sex chromosomes: evolution and implications for hybrid incompatibility. *Ann N Y Acad Sci.* 2012;1256:E1-22.
- Wellesley D, Dolk H, Boyd PA, Greenlees R, Haeusler M, Nelen V, et al. Rare chromosome abnormalities, prevalence and prenatal diagnosis rates from population-based congenital anomaly registers in Europe. *Eur J Hum Genet.* 2012;20(5):521-6.
- Samango-Sprouse CA, Lasutschinkow PC, McLeod M, Porter GF, Powell S, St Laurent J, et al. Speech and language development in children with 49, XXXXY syndrome. *Am J Med Genet A.* 2021;185(12):3567-75.

7. Kesaree N, Woolley PV, Jr. A phenotypic female with 49 chromosomes, presumably XXXXX. a case report. *J Pediatr.* 1963;63:1099-103.
8. Pirolo LM, Salehi LB, Sarta S, Cassone M, Capogna MV, Piccione E, et al. A new case of prenatally diagnosed pentasomy x: review of the literature. *Case Rep Obstet Gynecol.* 2015;2015:935202.
9. Chekhlabi N, Haoudar A, Hamdaoui H, Dini N. Report of a New Case of Pentasomy X Revealed by Status Epilepticus. *Cureus.* 2021;13(6):e16062.
10. Demirhan O, Tanriverdi N, Yilmaz MB, Kocaturk-Sel S, Inandikloglu N, Luleyap U, et al. Report of a new case with pentasomy X and novel clinical findings. *Balkan J Med Genet.* 2015;18(1):85-92.
11. Pirolo LMA, Salehi LB, Sarta S, Cassone M, Capogna MV, Piccione E, et al. A New Case of Prenatally Diagnosed Pentasomy X: Review of the Literature. *Case Rep Obstet Gynecol.* 2015;2015:935202.
12. Markholt S, Graakjaer J, Thim SB, Høst B, Skytte AB. A case of penta X syndrome caused by nondisjunction in maternal meiosis 1 and 2. *Clin Case Rep.* 2017;5(7):1136-40.
13. Oliver TR, Feingold E, Yu K, Cheung V, Tinker S, Yadav-Shah M, et al. New Insights into Human Nondisjunction of Chromosome 21 in Oocytes. *PLOS Genet.* 2008;4(3):e1000033.