

An unusual case of median nerve compression with ipsilateral supracondylar process

Dawood Jafari, MD.¹, Hamid Taheri, MD.², Hooman Shariatzadeh, MD.³,
Alireza Pahlevansabagh, MD.⁴, Farid Najd-Mazhar, MD.⁵

Department of Hand Surgery, Shafa Yahyaian Hospital, Iran University of Medical Sciences, Tehran, Iran.

Abstract

The supracondylar process is a beak-like bony projection that arises from the anteromedial surface of the humerus. The process has rarely been associated with compression of the median nerve and seldom requires treatment. We report a case of a supracondylar process that caused tenting of the median nerve with elbow extension and pronation.

Keywords: median nerve, Struthers' ligament, supracondylar process.

Introduction

The supracondylar process is a rare anatomic variation of the distal humerus [1]. It is a beak-like bony projection that arises from the anteromedial surface of the humerus approximately 5 cm proximal to the medial epicondyle [2]. Struthers' ligament- a fibrous arc- may extend from the tip of the process to the medial epicondyle, ossifying in rare cases [3]. The median nerve and the brachial artery pass through this small arch formed by the supracondylar process, Struthers' ligament and the medial epicondyle, [2].

Supracondylar process syndrome of the humerus has received little attention in the orthopedic literature [4]. This report presents a patient with such a condition.

Case report

A 24-year-old right-handed mechanic presented with a 7-year history of pain and pares-

thesia involving the right hand. He complained of tingling in the thumb, index, and middle fingers, and discomfort in the forearm. The pain increased with extension and pronation of the forearm. He noted increasing weakness in power and pinch grip. These symptoms had been refractory to conservative management, as well as to a right carpal tunnel release done 2 years ago. There was no history of trauma.

In physical examination, there was thenar atrophy and weak thumb opposition. The muscles of the forearm on the medial side also were atrophied. Tinnel and Phalen's test were negative over the carpal tunnel. Direct compression of the median nerve at the elbow produced pain. Examination of the right elbow revealed a bony process 6 cm proximal to the medial epicondyle. The movements of the elbow joint were normal. Radial and ulnar pulses were normal, and no trophic changes were noted in the extremity. Radiographs of the right wrist revealed normal anatomy. Radiographs of the right elbow revealed a supracondylar process approximately

1-3. Assistant Professor of Orthopedic Surgery, Iran University of Medical Sciences, Tehran, Iran.

4. **Corresponding author**, Hand Surgery Fellow, Department of Hand Surgery, Shafa Yahyaian Hospital, Baharestan Sq., Tehran, Iran. Tel: +9821 33542022, email: pahlevansabagh@yahoo.com.

5. Hand Surgery Fellow, Iran University of Medical Sciences, Tehran, Iran

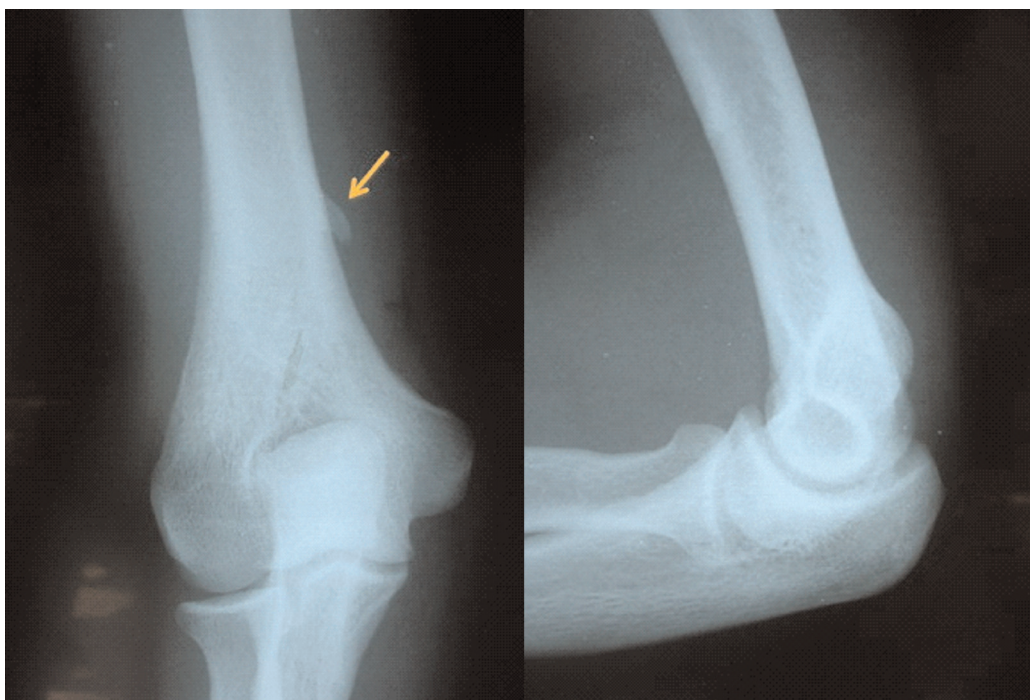


Fig. 1. Radiographs of right elbow showed a supracondylar process (arrow).

1.5 centimeter long, located 6 cm above the medial epicondyle of the humerus and extending obliquely downwards on anteroposterior view, while it was not apparent in the lateral view (Fig. 1). The electrophysiologic examination was consistent with median nerve palsy at the

elbow.

On the basis of the radiographs and clinical findings, the probable diagnosis of supracondylar process syndrome was made and we planned surgical decompression under general anesthesia. Following an approach through the medial

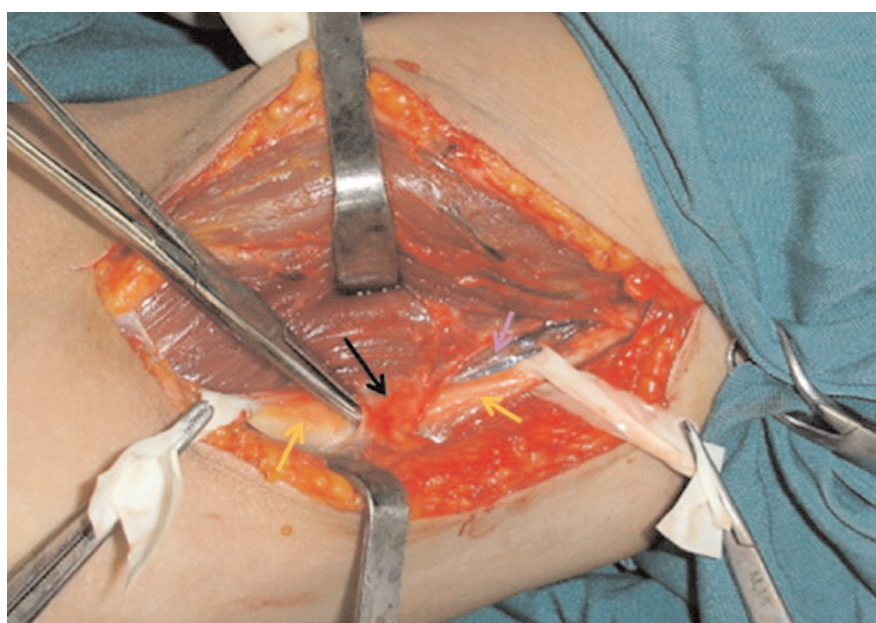


Fig. 2. Intraoperative finding of the median nerve (yellow arrow) and brachial artery (blue arrow) passing under Struthers' ligament (black arrow).

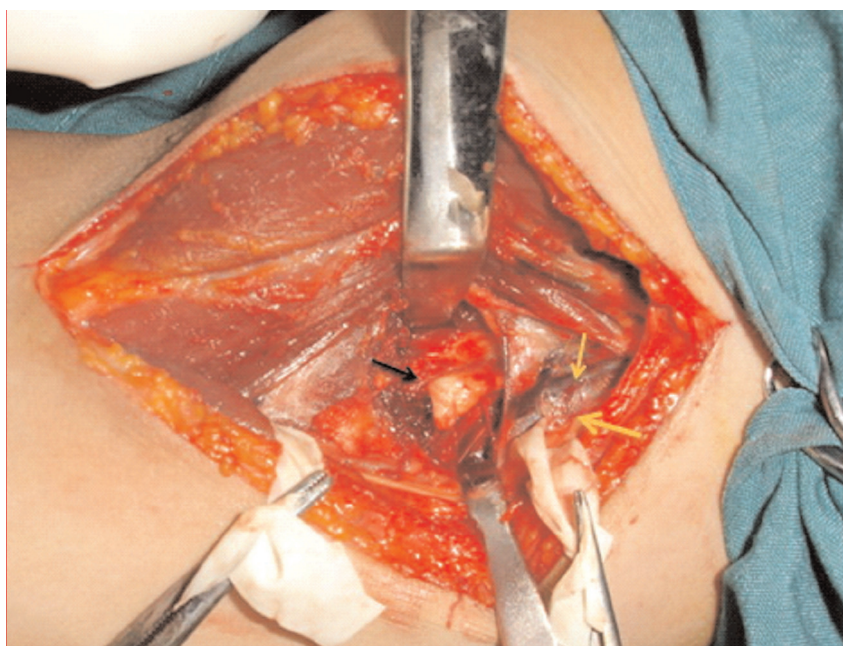

Fig. 3. Intraoperative finding of the supracondylar process (black arrow).

bicipital sulcus, we identified the median nerve and followed it as it and the brachial artery passed under Struthers' ligament (Fig. 2 and Fig. 3). Struthers' ligament was identified as a thick and firm broad fibrous band running from the apex of the supracondylar process to the distal and medial arm, where after 4 cm it was inserted to the medial epicondyle of the humerus. The median nerve did not show any signs of compression. Before the excision of Struthers' ligament and the supracondylar process, functional testing was performed. With full extension of the elbow and forearm pronation the median nerve stretched over the process. Struthers' ligament and the supracondylar process were removed entirely. The symptoms were relieved after operation and the patient was able to return to his previous job after 12 weeks of postoperative therapy.

Discussion

The supracondylar process was first described by Sir John Struthers in 1854. He also described a fibrous band from this process to the medial epicondyle, which we know as the Ligament of Struthers [5]. This process exists in

0.3%-2.7% of the population [6]. Although it usually occurs unilaterally, Subasi et al [7] reported a case with bilateral involvement. This anatomic variation has rarely been associated with median nerve compression neuropathy [8]. Patients complain of pain and numbness in the hand, and weakness in the forearm muscles innervated by the entrapped nerve, usually the median. The symptoms can be aggravated by extension of the elbow and forearm pronation [9]. Muscle weakness and atrophy are signs of prolonged nerve compression. Nerve conduction velocity testing and electromyography have rarely been helpful in confirming the diagnosis but have been useful in identifying concomitant nerve compression at other sites in the limb [3].

The authors acknowledge that it is difficult to ascertain definitively if this patient's symptoms were the result of median nerve compression proximally, distally, or a combination of both sites. Electrodiagnostic testing did not reveal any distal abnormalities. Nonetheless, the combination of proximal symptoms, lack of response to previous carpal tunnel release, intraoperative findings of proximal median nerve

compression, and ultimate response to treatment make the authors believe that localized proximal compression of the median nerve played a prominent role in producing the patient's symptoms.

References

1. Kazuki K, Egi T, Okada M, Takaoka K. Anatomic variation: a bony canal for the median nerve at the distal humerus: a case report. *J Hand Surg* 2004, 29A:953–956.
2. Kolb WL, Moore RD. Fractures of the supracondylar process of the humerus. *J Bone Joint Surg* 1976, 49A:532–534.
3. Ivins KG. Supracondylar process syndrome: a case report. *J Hand Surg* 1996, 2A: 279–281.
4. Sener E, Takka S, Cila E. Supracondylar process syndrome. *Arch Orthop Trauma Surg* 1998, 117: 418–419.
5. De Jesus R, Dellon AL. Historic Origin of the “Arcade of Struthers”. *J Hand Surg* 2003, 28A: 528-531.
6. Ay S, Bektas U, Yilmaz C, Diren B, An unusual supracondylar process syndrome. *J Hand Surg* 2002, 27A: 913-915.
7. Subasi M, Kesemenli C, Necmioglu S, Kapukaya A, Demirtas M. Supracondylar process of the humerus. *Acta Orthop Belg* 2002, 68:72-75.
8. Al-Naib I. Humeral supracondylar spur and Struthers' ligament. A rare cause of neurovascular entrapment in the upper limb. *Int Orthop* 1994, 18: 393-394.
9. Al-Qattan MM, Husband JB. Median nerve compression by the supracondylar process: a case report. *J Hand Surg* 1991, 16B: 101-3.