

## Prevalence of Ponticulus Posticus among Orthodontic Patients of Iranian Population by Lateral Cephalogram

Ali Bagherpour<sup>1</sup>, Behzad Motaharian<sup>2</sup>, Farzaneh Lal Alizadeh<sup>1</sup>, Maryam Valizadeh<sup>1</sup>, Kosar Hosseini<sup>2\*</sup> 

Received: 10 Jan 2024

Published: 2 Jul 2024

### Abstract

**Background:** The term Ponticulus Posticus (PP) refers to a complete or partial bony bridge on the vertebral artery that passes through the superior-lateral surface of the posterior arch of the atlas. This study was conducted with the aim of investigating the prevalence of ponticulus posticus in orthodontic patients referred to Mashhad Dental School.

**Methods:** In this cross-sectional study, one thousand cephalograms were selected from the patients referred to the orthodontics department of Mashhad Dental School between 2017 and 2021. In lateral cephalogram images with appropriate quality, the type of malocclusion was determined using the AudaxCeph software (Audax d.o.o., Ljubljana, Slovenia). Then, the images were evaluated for the presence or absence of PP. For the statistical analysis, chi-square and t-test were used.

**Results:** In this study, 861 lateral digital cephalograms were analyzed. The overall prevalence of PP in the studied population was 17.5%. The prevalence of PP was higher in males than in females ( $P < 0.001$ ). The variables “presence of PP” ( $P = 0.056$ ) and “type of PP” ( $P = 0.522$ ) were found to be independent of age groups. Although class II subjects showed a higher prevalence of PP, skeletal malocclusion classes were not found to be correlated with the presence of PP ( $P = 0.104$ ) nor with its types ( $P = 0.958$ ).

**Conclusion:** The current study is considered the primary study that provides data concerning the prevalence of PP in the East of Iran. Our study showed that PP was not rare in this region. More studies with 3D radiological examination are needed to increase the accuracy of diagnosing PP and its prevalence in Iran.

**Keywords:** Lateral Cephalogram, Ponticulus Posticus, Malocclusion, Radiography

**Conflicts of Interest:** None declared

**Funding:** None

\*This work has been published under CC BY-NC-SA 1.0 license.

Copyright© Iran University of Medical Sciences

**Cite this article as:** Bagherpour A, Motaharian B, Lal Alizadeh F, Valizadeh M, Hosseini K. Prevalence of Ponticulus Posticus among Orthodontic Patients of Iranian Population by Lateral Cephalogram. *Med J Islam Repub Iran*. 2024 (2 Jul);38.75. <https://doi.org/10.47176/mjiri.38.75>

### Introduction

Ponticulus Posticus (PP) is a bony anomaly situated between the posterior part of the superior articular process and the posterolateral part of the superior posterior arch of the first cervical vertebra (Atlas) (1). This anomalous ossification could completely or partially cover the groove of the vertebral artery and the sub-occipital nerve passage (2). Therefore, other terms, such as arcuate foramen, retroarticular canal of the atlas, and canalis arteriae vertebralis, are

sometimes used interchangeably with PP (1). Although this condition is considered a simple anatomical variant, its clinical significance has been highlighted in several studies (3, 4). It has been suggested that vertebral artery compression due to the anatomical position of PP could result in ischemia, leading to severe unexplained head and neck pain. Moreover, the possible association of PP existence

**Corresponding author:** Dr Kosar Hosseini, [hoseinik971@iums.ac.ir](mailto:hoseinik971@iums.ac.ir)

<sup>1</sup> Dental Research Center, School of Dentistry, Mashhad University of Medical Sciences, Mashhad, Iran

<sup>2</sup> Student Research Committee, School of Dentistry, Mashhad University of Medical Science, Mashhad, Iran

#### ↑What is “already known” in this topic:

The anatomical anomaly known as Ponticulus Posticus (PP), which is a bony projection located in the first cervical vertebra (Atlas), can potentially impact structures like the vertebral artery and the sub-occipital nerve passage. It seems that there is a gap in research regarding the prevalence and morphologic characteristics of Ponticulus Posticus in the Iranian population.

#### →What this article adds:

In the study group, 17.5% of individuals displayed PP. The ratio of males to females with PP was roughly 2:1. No significant variations in the frequency of PP were found when the different kinds of malocclusion or age groups were compared.

with the development of cervical pain syndrome and Migraine without aura has been reported in some patients (5). On the other hand, these related symptoms are not universally present. In this context, the primary diagnosis of PP could be more challenging (6). Furthermore, recognition of PP's presence is essential for spine surgical intervention, especially in treating atlantoaxial instability (4, 7). Therefore, before this intervention, it is necessary to prescribe radiography to investigate the presence of PP (4).

This risk and other mentioned complications highlight the importance of evaluating PP's prevalence in different geographical population contexts. Its frequencies in the general population have been estimated to be approximately between 1.3% and 45.9% (8, 9). Moreover, the occurrence of PP has been reported to be 5 to 37% in Western countries, with a majority in women (10, 11). The results of a study on the Iranian population showed that PP was detected in 38.3% of patients with a predominance in males (12). In addition, it has been suggested that PP formation could be influenced by age (13). However, there is a large discrepancy concerning the results of current studies regarding the prevalence of PP and its association with gender and age. Some previous studies have investigated the presence of PP and its association with skeletal malocclusion, styloid process, and cleft palate and lip (14, 15). However, some studies have generally questioned this relationship (1, 12).

Various radiographic techniques like computed tomography (CT), cone-beam computed tomography (CBCT), and lateral cephalometry have been used in different studies to investigate this anomaly. Among these techniques, lateral cephalometry has less radiation exposure and is also more common in orthodontics for assessing dentofacial skeletal patterns. Moreover, this method is suitable for the primary detection of anomalies in the cervical vertebrae area (16). However, during routine orthodontic examination, less attention is paid in this regard. Therefore, increasing dentists' awareness about specific clinical symptoms of PP and directing their attention toward the patient's lateral cephalogram can help recognize PP more accurately. While many studies have been conducted on the prevalence of this appendage in different populations, reports concerning the

prevalence or morphologic characteristics of this anomaly in the Iranian population are still insufficient.

To the best of our knowledge, limited studies have investigated the distribution of such variants and their relation to other anomalies and occlusion patterns in this geographical context. Therefore, the aim of the present study was to evaluate the prevalence of complete and partial PP in a sample of Iranian orthodontic patients; this will provide additional population data concerning this specific anomaly.

## Methods

In this cross-sectional study, lateral digital cephalogram radiographs of 1000 patients were retrieved from the Orthodontic Department of Mashhad Dental School between 2017 and 2021. Ethical approval was obtained from Mashhad University of Medical Science [number IR.MUMS.DENTISTRY.REC.1400.122], and all the patients' personal information will be kept confidential. First, the documents of all patients were reviewed by the second author (BM). To eliminate any error, 86 randomly selected lateral cephalograms ( $\approx 10\%$ ) were re-examined separately by the same author 2 weeks after the initial examination. There was complete agreement between the two examinations. Individuals with sufficient personal information, a minimum age of ten (17), and no history of systemic diseases affecting bone density, genetic, syndromic, cleft lip, and palate diseases were selected. Then all lateral cephalograms that were taken by Vatech Pax-i PCH-2500 (Korea) machine were evaluated using AudaxCeph software (Audax d.o.o., Ljubljana, Slovenia) with sufficient screen light. Radiographs with low diagnostic quality, superimposition of mastoid, interference in the true vertical chain, the presence of pathological or traumatic lesions, and the presence of developmental skeletal abnormalities were excluded. Finally, 861 cases were included in the study.

Patient demographic information, presence/absence of PP, PP type (complete or partial), and dentofacial skeletal pattern were recorded according to lateral cephalometry. Figure 1 a-c shows different types of PP on lateral cephalograms. The subjects were categorized according to gender (male and female) and also according to two age groups: 10 to 24 years and 25 to 39 years. Then, through tracing with

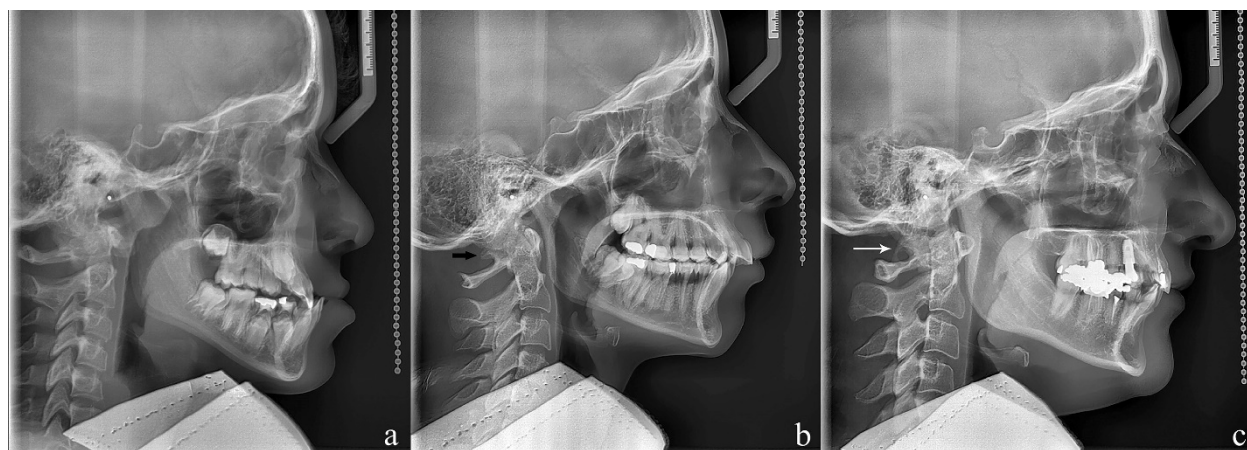


Figure 1 a-c. Different types of Ponticulus Posticus (PP) seen on lateral cephalograms. a, Without PP. b, Partial PP (black arrow). c, Complete PP (white arrow)

AudaxCeph software (ver 6.1.4) and McNamara analysis, the dentofacial skeletal pattern of the patient was determined. SNA, SNB, ANB, and SN-FH angles were determined in the software. In cases where the landmarks were not clear or the SN-FH angle was abnormal (more or less than 6 degrees), we consulted with an orthodontist, and then abnormal cases were modified or excluded from the study. The skeletal pattern was categorized as Class I, Class II, and Class III. Then, all cephalograms were investigated for the presence or absence of PP and the type of PP (partial, complete). Any ambiguity was resolved by discussion with an oral and maxillofacial radiologist and an orthodontist.

Finally, IBM SPSS 18 software (SPSS Inc., Chicago, IL, USA) was used for statistical analysis. The chi-square test was used to compare the relationship between gender and the presence of PP and the type of skeletal class and the presence of PP. Independent t-test was used to compare the mean age of two groups (with PP and without PP). If the *P*-value was less than 0.05, the results were considered statistically significant.

### Results

Out of 861 patients, 561 (65.2%) were females and 300 (34.8%) were males. The age range of samples was 10-39 years, with a mean age of  $17.5 \pm 6.5$ . The mean age of females was higher than that of males ( $17.89 \pm 6.52$  and

$16.84 \pm 6.37$ , respectively). Most of the patients were classified as having Class II malocclusion (54.9%). The prevalence of PP (both complete and partial) was 17.5% (151/861) in the study population. The complete types of PP were observed in 22.5% of cases (34/151) and the partial variant was found in 77.5% (117/151) of cases.

As shown in Table 1, the relationship between the presence of PP in patients with different characteristics and variables was investigated. The prevalence of PP was higher in males and in patients aged 10-24 years with Class II malocclusion. However, only gender showed a significant relationship with the presence of PP ( $P < 0.001$ ). Furthermore, none of the cases' characteristics were significantly associated with PP types. The partial variant was generally more prevalent than the complete type. Among those with PP, 80.0% of females, 86.7% of individuals aged 25-39, and 78.6% of those with Class III malocclusion presented with the partial type of PP. The prevalence of these two types relative to patient characteristics is compared in Figure 2. Moreover, an independent t-test was used to compare the mean age of the two groups (with PP and without PP). Results showed no significant difference between the mean age of participants without ( $17.68 \pm 6.51$ ) and with PP ( $16.82 \pm 6.35$ ) ( $P = 0.141$ ).

### Discussion

Table 1. Pearson's Chi-square test to assess the association between PP and demographic characteristics

Patient characteristics		N (%)	PP*		<i>P</i> <sup>#</sup>	PP types		<i>P</i>
			Yes (%)	No (%)		Partial (%)	Complete (%)	
Gender	Male	300 (34.8)	76 (25.3)	224 (74.7)	<0.001	57 (75.0)	19 (25.0)	0.462
	Female	561 (65.2)	75 (13.4)	486 (86.6)		60 (80.0)	15 (20.0)	
Age group	10-24	732 (85.0)	136 (18.6)	596 (81.4)	0.056	104 (76.5)	32 (23.5)	0.522
	25-39	129 (15.0)	15 (11.6)	114 (88.4)		13 (86.7)	2 (13.3)	
Malocclusion classes	Class I	204 (23.7)	33 (21.9)	171 (78.1)	0.104	25 (75.8)	8 (24.2)	0.958
	Class II	473 (54.9)	76 (50.3)	397 (49.7)		59 (77.6)	17 (22.4)	
	Class III	184 (21.4)	42 (27.8)	142 (72.2)		33 (78.6)	9 (21.4)	

\*: Ponticulus Posticus, #: *P*-value

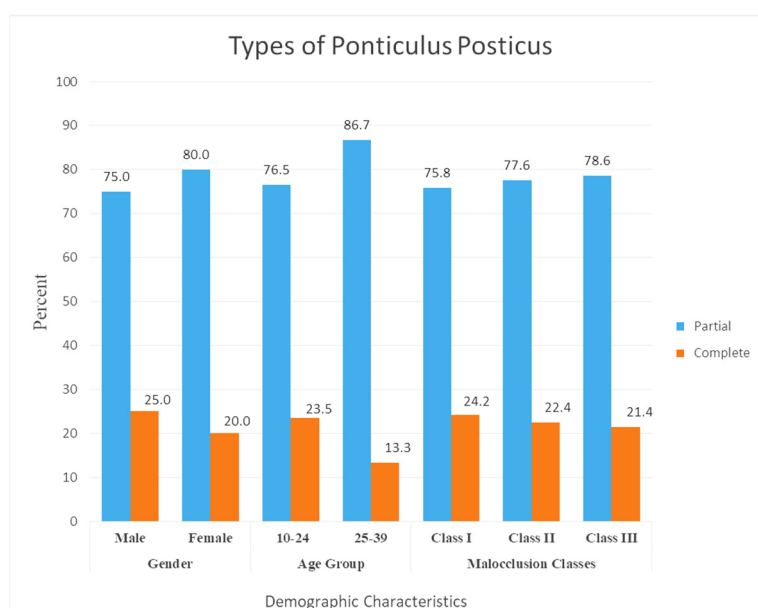


Figure 2. Comparison of PP types according to participants' demographic characteristics

This cross-sectional study aimed to evaluate the prevalence of PP and to assess its relationship with gender, age, and skeletal malocclusion in a group of orthodontic patients by using lateral cephalograms in Eastern Iran. The results of the current study showed that this anomaly is relatively common, having been found in 17.5% of the study population. In two similar studies conducted in the west and center of Iran, the prevalence of PP was reported to be 38.3% and 21.3%, respectively (12, 18). Overall, the prevalence of PP in different populations has been reported to range between 1.3% and 45.9% (19). This variation across different populations could highlight the effects of ethnic and geographical contexts on the prevalence of this anomaly. Among Asian populations, several studies have been conducted in different geographic regions. The lowest presence of PP was reported in India (4.3%- 11.1%) and South Korea (14.0%- 15.5%) (7, 20-22). On the other hand, studies in Nepal (35.7%) and Turkey (36.8%- 43.04%) showed a higher frequency of PP in comparison to our study (2, 19, 23). It is important to note that the prevalence rate of PP in Western countries has been estimated to be between 5% and 37% (10).

In addition to ethnic diversity, another factor that could explain the discrepancy in prevalence values is the different methodologies used in studies. To date, various methods, such as the examination of cadavers, lateral cephalograms, CT scans, and CBCT images, have been employed to investigate the presence of PP in different studies (24). Lateral cephalometry is the most commonly used type of radiography for orthodontic evaluations and treatments (21). In the studies by Gibelli et al. (25), Mudit et al. (21), and Sharma et al. (20), lateral cephalogram imaging was used, similar to the present study. Conversely, Kim et al. (7), and Serkeci et al. (19) utilized CT scans. The prevalence of this anomaly was reported to be slightly higher in studies using CT and CBCT. A meta-analysis that compared the frequencies of ponticulus posticus using lateral cephalometry and 3D imaging found no significant difference between the reports from CT and lateral cephalograms (24).

In the present study, the prevalence of PP was higher in males than in females, which is consistent with the findings of Adisen et al. (1), Sekerci et al. (19), Sharma et al. (20), Giri et al. (23) and Hong et al. (26). Moreover, this association was statistically significant, similar to another study conducted in Iran (12). However, some studies found no significant relationship in this regard (7, 21, 25). Conversely, a female predilection for this anatomical variation has been reported in some research (4, 18).

Some previous studies have suggested that the formation of PP could increase with chronological age, especially after puberty, within the first two decades. Furthermore, due to progressive mineralization and calcification over time, the partial type of PP has the potential to develop into the complete type (5, 13, 27). Hence, some studies have suggested that the partial type of PP is more prevalent at younger ages (13, 25). In the current study, the age group of 10 to 39 years was investigated. Additionally, the complete type of PP was present in 22.5% of our study population. Some studies have also investigated lower age groups due to the possible effect of age on the prevalence of PP

(13, 18). However, the results of our study did not show any clear relationship between the incidence of PP and increasing age, which is consistent with several other studies (1, 19). Therefore, it seems that further studies with larger sample sizes and a wider age group are needed to clarify this relationship.

Since the embryonic stage, the base of the cranium and its related structures, such as the jaws and the cervical vertebrae, share a common origin (the notochord) (28). Several studies have investigated the possibility of a link between the presence of cervical vertebral anomalies and skeletal malocclusion traits (1, 28, 29). In this respect, we found no significant relationship between PP and different classes of occlusion. Our results are consistent with the previous studies by Adisen and Misirlioglu et al. (1), Kamak and Yildirim et al. (29) and Falah-Kooshki et al. (12). Although in the present study, PP was most frequently reported in subjects with Angle's Class II occlusion, followed by Class III and Class I. Some studies have shown a higher frequency of PP in Class III malocclusion (30). In the study of Adisen et al. (1) and Bayrakdar et al. the highest prevalence was found in Class III patients. On the other hand, in line with our findings, Antonino Lo Giudice et al. (28) reported a higher prevalence of this anomaly in Class II patients, but no significant difference was observed between the different types of malocclusion. Therefore, the association between such vertebral anomalies, jaw position, and craniofacial profile is still unclear, and more research is needed to shed light on the controversy surrounding the association of craniofacial morphologies and deviations with vertebral anomalies.

In this study, a large sample size was examined. The subject of the study, which investigated the relationship between PP and jaw malocclusions, is new and has seldom been the subject of similar Iranian studies (12). This study had some limitations related to lateral cephalometric analysis. Although this technique is a suitable tool for the primary diagnosis and detection of PP, previous studies have shown that one-dimensional radiography, in comparison to 3D CT scans, may underestimate the accurate prevalence and has more limitations in detecting a partial bridge (1, 9). Furthermore, with this method, it is not possible to reconstruct morphologies and determine the unilateral or bilateral presence and size of PP (1). On the other hand, a lateral cephalogram, as a routine radiograph in orthodontic examinations, could easily be considered for screening this anomaly and documenting the presence of PP in a patient's health record for future reference. Future studies are recommended to use three-dimensional radiography to investigate the morphological types and dimensions of this anomaly. In addition, further studies are needed to investigate the relationship between PP and temporomandibular disorders (TMD).

### Conclusion

This study provides insights into the prevalence and characteristics of PP in lateral cephalogram images of the Iranian population. Results showed that PP should not be considered a rare anatomical feature in this region, based on the 17.5% prevalence observed. The presence of PP was not influenced by the patient's type of skeletal malocclusion or



their age group. However, there was a significant relationship between the prevalence of PP and gender. Further research is needed to better understand the factors associated with the presence of PP.

### Authors' Contributions

Conceptualization: Ali Bagherpour, Farzaneh Lal Alizadeh

Data curation: Ali Bagherpour, Farzaneh Lal Alizadeh

Investigation: Ali Bagherpour, Behzad Motaharian

Methodology: Ali Bagherpour, Farzaneh Lal Alizadeh, Behzad Motaharian

Project administration: Ali Bagherpour

Supervision: Ali Bagherpour

Validation: Ali Bagherpour, Farzaneh Lal Alizadeh

Writing—original draft: Kosar Hosseini, Maryam Valizadeh

Writing—review & editing: Ali Bagherpour, Kosar Hosseini, Maryam Valizadeh

### Ethical Considerations

The present study was approved by the Ethics Committee of Mashhad University of Medical Science [number IR.MUMS.DENTISTRY.REC.1400.122]. All data collected was kept confidential and only used for research purposes. Any personal information was de-identified to protect the subjects' privacy. The researcher followed ethical guidelines and standards throughout the study. Copyright laws and regulations were followed while using translated materials or scientific references in our research.

### Acknowledgment

This study was based on an undergraduate thesis by Behzad Motaharian (No. 3492), and was supported by the Vice Chancellor for Research of Mashhad University of Medical Sciences, Mashhad, Iran (Protocol No. 4001173).

### Conflict of Interests

The authors declare that they have no competing interests.

### References

- Adisen MZ, Misirlioglu M. Prevalence of ponticulus posticus among patients with different dental malocclusions by digital lateral cephalogram: a comparative study. *Surg Radiol Anat*. 2017;39(3):293-7.
- Buyuk SK, Sekerci AE, Benkli YA, Ekizer A. A survey of ponticulus posticus: Radiological analysis of atlas in an orthodontic population based on cone-beam computed tomography. *Niger J Clin Pract*. 2017;20(1):106-10.
- Sekerci AE, Soyulu E, Arikian MP, Aglarci OS. Is there a relationship between the presence of ponticulus posticus and elongated styloid process? *Clin Imaging*. 2015;39(2):220-4.
- Tambawala SS, Karjodkar FR, Sansare K, Motghare D, Mishra I, Gaikwad S, et al. Prevalence of Ponticulus Posticus on Lateral Cephalometric Radiographs, its Association with Cervicogenic Headache and a Review of Literature. *World Neurosurg*. 2017;103:566-75.
- Bayrakdar IS, Miloglu O, Altun O, Gumussoy I, Durna D, Yilmaz AB. Cone beam computed tomography imaging of ponticulus posticus: prevalence, characteristics, and a review of the literature. *Oral Surg Oral Med Oral Radiol*. 2014;118(6):e210-9.
- Baba I, Shah A, Yousuf A, Adhnan MM, Manzoor H, Safdar Z. Prevalence of ponticulus posticus in Kashmiri population. *Ann Dent*. 2015;3(1):6-8.
- Kim KH, Park KW, Manh TH, Yeom JS, Chang BS, Lee CK. Prevalence and Morphologic Features of Ponticulus Posticus in Koreans: Analysis of 312 Radiographs and 225 Three-dimensional CT Scans. *Asian Spine J*. 2007;1(1):27-31.
- Hassel B, Farman AG. Skeletal maturation evaluation using cervical vertebrae. *Am J Orthod Dentofacial Orthop*. 1995;107(1):58-66.
- Geist JR, Geist SM, Lin LM. A cone beam CT investigation of ponticulus posticus and lateralis in children and adolescents. *Dentomaxillofac Radiol*. 2014;43(5):20130451.
- Stubbs DM. The arcuate foramen. Variability in distribution related to race and sex. *Spine J*. 1992;17(12):1502-4.
- Wight S, Osborne N, Breen AC. Incidence of ponticulus posterior of the atlas in migraine and cervicogenic headache. *J Manip Physiol Ther*. 1999;22(1):15-20.
- Falah-Kooshki S, Nikkerdar N, Imani MM, Faraji R, Golshah A. Correlation of Ponticulus Posticus with Dentofacial Skeletal Patterns. *Contemp Clin Dent*. 2022;13(1):35-9.
- Kendrick GS, Biggs NL. Incidence of the ponticulus posticus of the first cervical vertebra between ages six to seventeen. *Anat Rec*. 1963;145:449-53.
- Lippold C, Danesh G, Hoppe G, Drerup B, Hackenberg L. Sagittal spinal posture in relation to craniofacial morphology. *Angle Orthod*. 2006;76(4):625-31.
- Mosavat F, Sarmadi S, Amini A, Asgari M. Evaluation of Dimension and Bridging of Sella Turcica and Presence of Ponticulus Posticus in Individuals With and Without Cleft: A Comparative Study. *Cleft Palate Craniofac J*. 2023;60(6):695-700.
- Tetradis S, Kantor ML. Prevalence of skeletal and dental anomalies and normal variants seen in cephalometric and other radiographs of orthodontic patients. *Am J Orthod Dentofacial Orthop*. 1999;116(5):572-7.
- Rao RD, Tang S, Lim C, Yoganandan N. Developmental morphology and ossification patterns of the C1 vertebra. *J Bone Joint Surg Am*. 2013;95(17):e1241-7.
- Mokhtari N, Ashtari F, Razavi M, Ghaffari R. Prevalence and characteristics of ponticulus posticus and its association with cervicogenic headache and migraine: A lateral cephalometric study. *JRMS*. 2022;27:61.
- Sekerci AE, Soyulu E, Arikian MP, Ozcan G, Amuk M, Kocoglu F. Prevalence and Morphologic Characteristics of Ponticulus Posticus: Analysis Using Cone-Beam Computed Tomography. *J Chiropr Med*. 2015;14(3):153-61.
- Sharma V, Chaudhary D, Mitra R. Prevalence of ponticulus posticus in Indian orthodontic patients. *Dentomaxillofac Radiol*. 2010;39(5):277-83.
- Mudit G, Srinivas K, Satheesha R. Retrospective analysis of ponticulus posticus in Indian orthodontic patients-a lateral cephalometric study. *Ethiop J Health Sci*. 2014;24(4):285-90.
- Cho YJ. Radiological analysis of ponticulus posticus in Koreans. *Yonsei medical journal*. 2009;50(1):45-9.
- Giri J, Pokharel PR, Gyawali R. How common is ponticulus posticus on lateral cephalograms? *BMC Res*. 2017;10(1):172.
- Elliott RE, Tanweer O. The prevalence of the ponticulus posticus (arcuate foramen) and its importance in the Goel-Harms procedure: meta-analysis and review of the literature. *World Neurosurg*. 2014;82(1-2):e335-43.
- Gibelli D, Cappella A, Cerutti E, Spagnoli L, Dolci C, Sforza C. Prevalence of ponticulus posticus in a Northern Italian orthodontic population: a lateral cephalometric study. *Surg Radiol Anat*. 2016;38(3):309-12.
- Hong JT, Lee SW, Son BC, Sung JH, Yang SH, Kim IS, et al. Analysis of anatomical variations of bone and vascular structures around the posterior atlantal arch using three-dimensional computed tomography angiography. *J Neurosurg Spine*. 2008;8(3):230-6.
- Paraskevas G, Papaziogas B, Tsonidis C, Kapetanios G. Gross morphology of the bridges over the vertebral artery groove on the atlas. *Surg Radiol Anat*. 2005;27(2):129-36.
- Lo Giudice A, Caccianiga G, Crimi S, Cavallini C, Leonardi R. Frequency and type of ponticulus posticus in a longitudinal sample of nonorthodontically treated patients: relationship with gender, age, skeletal maturity, and skeletal malocclusion. *Oral Surg Oral Med Oral Radiol*. 2018;126(3):291-7.
- Kamak H, Yildirim E. The distribution of cervical vertebrae anomalies among dental malocclusions. *J Craniovertebr Junction Spine*. 2015;3(1):6-8.

2015;6(4):158-61.

30. Bayrakdar I, Miloğlu Ö, Yeşiltepe S, Yılmaz AB. Ponticulus posticus in a cohort of orthodontic children and adolescent patients with different sagittal skeletal anomalies: a comparative cone beam computed tomography investigation. *Folia Morphol.* 2018;77(1):65-71.