

# MAST CELLS IN INFLAMMATORY AURAL POLYPS

DRAGOSLAVA R. DJERIC', M.D., Ph.D.

*From the Institute of Otorhinolaryngology and Maxillofacial Surgery, Pasterova 2, Belgrade 11000, Yugoslavia.*

## ABSTRACT

This study investigated the presence of mast cells in inflammatory aural polyps using light microscopy. The number of mast cells was increased in all examined cases and varied from 2.33 to 41.54 per mm<sup>2</sup>. The cells were located most commonly around small blood vessels. Occurrence of mast cells was not different in various types of polyps, but their density was severely increased in active inflamed polypous tissue. These findings suggest that mast cells may be a contributory factor in the pathogenesis of middle ear inflammatory processes.

*MJIRI, Vol. 13, No. 4, 257-259, 2000.*

**Keywords:** Mast cells, Inflammatory aural polyps, Pathogenesis.

## INTRODUCTION

Mast cells were first discovered by Paul Ehrlich over a century ago, who found specific metachromatic properties of their granules.<sup>1</sup> These granules contain histamine, heparin, several neutral proteases and acid hydrolases, and other enzymes.<sup>2</sup> The biological effects of mast cells rely on the release of potent active mediators from the cytoplasmic granules, and also on production of lipid mediators (prostaglandins, leukotrienes) and cytokines (TNF- $\alpha$ ). This is induced by cross-linkage of their surface IgE receptors and the subsequent biochemical cascade that results in mast cell degranulation.<sup>3</sup>

Although mast cells are found in all human tissue, they are most commonly seen at the interface between the host and its environment, under the epithelial linings. The role of mast cells in various inflammatory and allergic diseases, tumors and systemic pathological processes has been postulated.<sup>4-6</sup> It is mostly based on the increase in the number of mast cells during these processes, as has also been shown in chronic middle ear inflammation.<sup>7,8</sup>

The purpose of this study was to examine the occurrence and cytologic properties of mast cells in inflammatory aural polyps and to suggest their role in the pathogenesis of chronic middle ear diseases.

## MATERIAL AND METHODS

The study included 40 patients with chronic suppurative otitis media, who had undergone tympanomastoid surgery. The polypous mass was obtained during surgery and included sixty specimens which were fixed in 4% buffered formaldehyde, routinely processed and embedded in paraffin. Some of the tissue samples (n=20) were also fixed in recommended mast cell fixatives (Carnoy's) and basic lead acetate.<sup>9</sup> Serial sections, 5  $\mu$ m thick, were obtained from paraffin block using a microtome (Reichert). They were routinely stained by hematoxylin and eosin to study the histological changes which might affect mast cell number.

Mast cells were stained with 1% toluidine blue in 0.5M HCl (pH=0.5) for 48 to 72 h at room temperature, that was preceded and followed by a rinse in 0.5M HCl. This long toluidine blue technique (LTB) stained both mucosal and connective tissue types of mast cells in formalin fixed preparation. We also stained the mast cells by classical toluidine blue and alcian blue/safranine O (A/S) staining procedures.<sup>10,11</sup> Mast cells were counted in at least 5 discontinuous sections of each block using the  $\times 40$  objective and ocular grid, and were expressed as the number of cells/mm<sup>2</sup> of tissue.

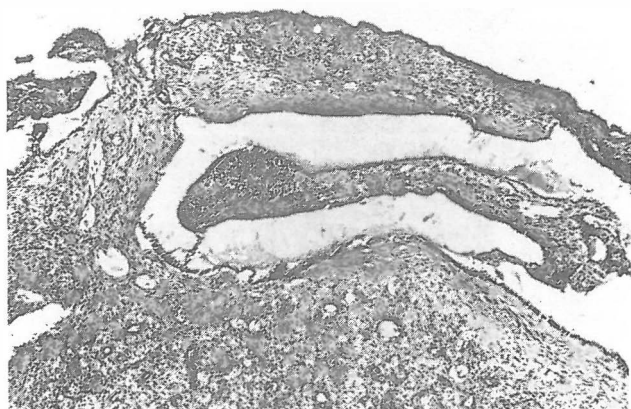


Fig. 1. Inflammatory aural polypous tissue stained with hematoxylin and eosin ( $\times 135$ ). The stroma showed various degrees of edema, fibrosis, increased vascularity and infiltration by plasma cells and lymphocytes.

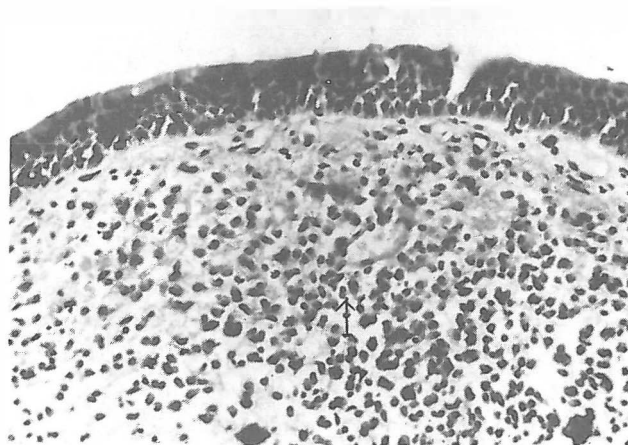


Fig. 2. The mast cells were located mostly around small blood vessels (arrow) in the stromal tissue. Other inflammatory cells are also present (H&E  $\times 150$ ).

## RESULTS

Analysis of hematoxylin and eosin sections of aural polyps revealed various histopathological changes which were more developed in the stroma. The changes manifested as edema, fibrocystic spaces and increased vascularity with infiltration of lymphocytes and plasma cells (Fig. 1). Mast cells were increased in all specimens. Their number varied largely from 2.33 to 41.54 cells/mm<sup>2</sup> (mean  $\pm$  22.3). The cells were concentrated mostly around small blood vessels (Fig. 2), or scattered throughout the stromal and epithelial tissue. The mast cell counts varied within each specimen and from specimen to specimen. However, there was no significant correlation between the number of mast cells and the variety of pathologic changes of the polyps. Degranulation of the mast cells was present in all cases but was observed more frequently in specimens with more active inflammation (Fig. 3).

## DISCUSSION

Previous studies have shown that an aural polyp may be an indicator of active middle ear disease. It has been postulated that in cases of aural polyps with clinically non-cholesteatomatous disease, histological examination can predict the development of cholesteatoma.<sup>12,13</sup>

An increased number of mast cells has been found in various inflammatory diseases including chronic otitis media,<sup>8</sup> implicating their role in the pathogenesis of this disease. There is no question that mast cells are exceedingly good at initiating inflammation. In this study we also found an overall increase of mast cells in polypous mucosa, and noticed cells with morphological characteristics signifying degranulation and release of active mediators. These substances are known to induce various biological activities.

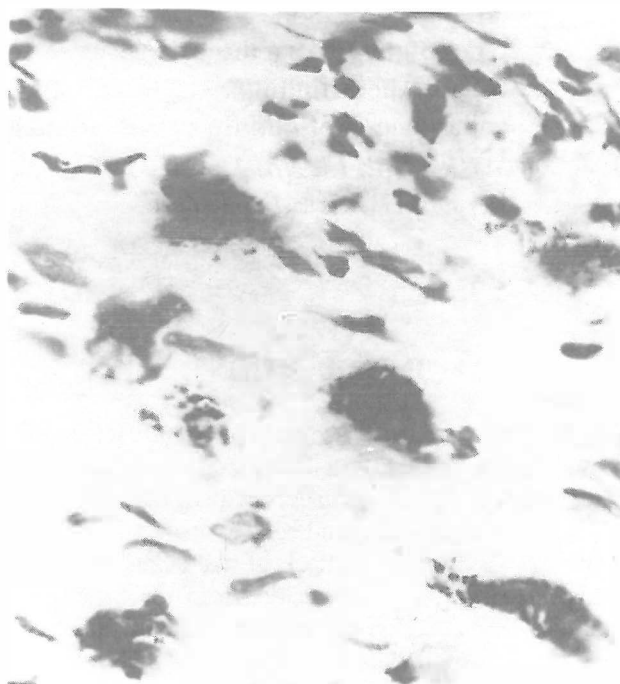


Fig. 3. The mast cells showed degranulation on the section stained with toluidine blue. Granular staining is present within the mast cells (LTB  $\times 150$ ).

It was found that injection of degranulated products of mast cells such as histamine or platelet-activating factor into the middle ear induced the occurrence of middle ear effusion.<sup>14</sup> Also, it was suggested that mast cells play an important role in the pathogenesis of secretory otitis media.<sup>14</sup> Our study has also shown an increased number of mast cells in inflammatory aural polyps, indicating their involvement in the pathogenesis of chronic otitis media. However, further studies need to be done by electron microscopy for evaluation of mast cell degranulation and differentiation of their role.

REFERENCES

1. Ehrlich P: Beitrage zur Theorie und Praxis der histologischen. Farburg. Leipzig, the Thesis, 1878.
2. Wasserman S: Mast cell biology. *J Allergy Clin Immunol* 86: 590-593, 1990.
3. Galli S: New concepts about the mast cells. *New Engl J Med* 328: 265-275, 1993.
4. Schulman E: The role of mast cells in inflammatory responses in the lung. *Crit Rev Immunol* 13: 35-70, 1993.
5. Lim D: Functional morphology of the lining membrane of the middle ear and eustachian tube. *Ann Otol Rhinol Laryngol* 98: 2-9, 1974.
6. Enerbach L : Mast cells in rat gastrointestinal mucosa. *Acta Path Microbiol Scand* 66: 289-302, 1966.
7. Alm P, Bloom G, Hellstrom S, et al: The release of histamine from the pars flaccida mast cells in one case of otitis media with effusion. *Acta Otolaryngol* 94: 517-522, 1982.
8. Berger C, Hawke M, Ekem J: Mast cells in human middle ear mucosa in health and in disease. *J Otolaryngol* 13: 370-374, 1984.
9. Gomez E, Corrado O, Davies R: Histochemical and functional characteristics of the human nasal mast cells. *Arch Allergy* 83: 52-56, 1987.
10. Wingren U: Mucosal mast cells of the rat intestine: a reevaluation of fixation and staining properties with special reference to protein blocking and solubility of the granule's glucosaminoglycans. *Histochem J* 15: 571-582, 1983.
11. Stead R, Franks A, Goldsmith C, et al: Mast cells, nerves, and fibrosis of the appendix: a morphological assessment. *J Pathol* 161: 209-219, 1990.
12. Hussain S: Histology of aural polyp as a predictor of middle ear disease activity. *J Laryngol Oto* 110: 268-269, 1991.
13. Milroy C, Slack R, Maw A, Bradfield J: Aural polyp as predictor of underlying cholesteatoma. *J Clin Pathol* 42: 460-465, 1989.
14. Rhee C, Jung T, Miller S, et al: Experimental otitis media with effusion induced by platelet activating factor. *Ann Otol Rhinol Laryngol* 102: 600-605, 1993.

