


Anesthetic Management of Bronchobiliary Fistula as a Complication of Liver Hydatid Cyst: A Case Report

Faranak Rokhtabnak¹, Masoud Baghai-Wadji², Parinaz Morovati Sharifabadi³, Nasrin Nouri^{3*} 

Received: 16 Mar 2024

Published: 11 Jun 2024

Abstract

Bronchobiliary fistula (BBF) in adults is a quite infrequent complication characterized by the abnormal interconnection between the right bronchial system and the biliary tract. BBF may occur due to various causes, including trauma, infections, malignancies, and complications of certain surgical procedures involving the liver or the hepatobiliary system. In this paper, we report a case of BBF following liver hydatid cyst resection that developed in a 58-year-old Iranian male. The patient had acute dyspnea with yellowish sputum. After diagnostic measures such as bronchoscopy, computed tomography (CT) scan, endoscopic retrograde cholangiopancreatography (ERCP), and confirmation of the diagnosis of BBF, the patient underwent Intravenous (IV) antibiotic therapy, placement of pleural drain, sphincterotomy and CBD stents insertion but unfortunately, these measures were not effective and the patient was a candidate for thoracotomy and resection of fistula and the involved lung. During surgery, absolute lung isolation was done by insertion of a left-sided double-lumen endobronchial tube and uneventful anesthesia was maintained for about 5 hours. Patients with BBF present unique challenges in terms of anesthetic management. Sepsis, pulmonary impairment, electrolyte imbalances and malnutrition will make anesthesiologists face many perioperative challenges. During surgery, absolute lung isolation is typically necessary and achieving effective lung isolation can be quite challenging due to the presence of the fistula. Postoperatively, intensive respiratory support, chest tube drainage, and appropriate antibiotic therapy may be required. In addition, a multidisciplinary approach involving anesthesiologists, thoracic surgeons, and other specialists is crucial.

Keywords: Anesthesia, One-Lung Ventilation, Broncho-Biliary Fistula, BBF, Thoracotomy

Conflicts of Interest: None declared

Funding: None

*This work has been published under CC BY-NC-SA 1.0 license.

Copyright© Iran University of Medical Sciences

Cite this article as: Rokhtabnak F, Baghai-Wadji M, Morovati Sharifabadi P, Nouri N. Anesthetic Management of Bronchobiliary Fistula as a Complication of Liver Hydatid Cyst: A Case Report. *Med J Islam Repub Iran*. 2024 (11 Jun);38:66. <https://doi.org/10.47176/mjiri.38.66>

Introduction

Bronchobiliary fistula (BBF) in adults is a quite infrequent complication characterized by the abnormal interconnection between the right bronchial system and the biliary tract, leading to the passage of bile into the bronchus and subsequently into the sputum (biloptysis) (1). The first reported case of BBF was described by Peacock in 1850 (2). The patient in that case had hepatic hydatidosis; since then,

several other cases of BBF have been reported in the medical literature. BBF can occur due to various causes, including trauma, infections, malignancies, and complications of certain surgical procedures involving the liver or the biliary system (3, 4). Treatment options for bronchobiliary fistula depend on the underlying causes, severity of symptoms, and overall patient's health. Conservative management

Corresponding author: Dr Nasrin Nouri, nouri.na@iums.ac.ir

¹ Department of Anesthesiology, Firoozgar Hospital, School of Medicine, Iran University of Medical Sciences, Tehran, Iran

² Department of Surgery, Firoozgar Hospital, School of Medicine, Iran University of Medical Sciences, Tehran, Iran

³ Department of Anesthesiology, Rasoul Akram Hospital, School of Medicine, Iran University of Medical Sciences, Tehran, Iran

↑What is “already known” in this topic:

Bronchobiliary fistula (BBF) in adults characterized by the abnormal interconnection between the right bronchial system and the biliary tract, leading to the passage of bile into the bronchus and subsequently into the sputum (biloptysis).

→What this article adds:

This article highlights the challenges in diagnosing and management of BBF. If the patient require surgery for resection of fistula and the involved lung, present unique challenges in terms of anesthetic management. Due to their poor lung function, these patients often have compromised respiratory status.

may involve supportive care, including antibiotics for respiratory infections and nutritional support. However, definitive treatment usually requires surgical intervention to the fistula and addresses any underlying biliary tract pathology (5, 6).

Patients with BBF present unique challenges in terms of anesthetic management. Due to their poor lung function, these patients often have compromised respiratory status (7). During surgery, absolute lung isolation is typically necessary, and achieving effective lung isolation can be challenging due to the presence of the fistula (8). In this paper, we report a case of a broncho-biliary fistula following liver hydatid cyst resection that developed in a 58-year-old male and discuss anesthetic challenges in BBF resection surgery.

Case Presentation

A 58-year-old man (65kg, 172cm) was referred to a thoracic surgeon because of broncho-biliary fistula for not responding to percutaneous biliary drainage, papillotomy and stenting and antibiotic therapy. His medical history was liver hydatid cyst since 2000, and he had undergone laparotomy for liver hydatid cyst for 3 times. The latest was in 2013, when cholecystectomy was done too. He presented with anorexia, fever, productive cough with yellow sputum (biloptysis) and right upper quadrant (RUQ) pain since 2 months ago. Intravenous (IV) antibiotic therapy was used to control the infection. Preoperative chest X-ray represented a right lower lobe infiltration and pleural effusion (Figure 1) and a pleural drain was placed under computed tomography (CT) scan guidance. The bilirubin was positive on a dipstick of sputum and from pleural drained secretions. An endoscopic retrograde cholangiopancreatography (ERCP) was done and revealed a fistula opening near the papillary orifice and common bile duct (CBD) dilatation about 12 mm with filling defect, complete disruption of the right hepatic duct with diffuse extravasation of dye. Sphincterotomy was performed and two plastic CBD (10 cm, 10Fr) stents were placed in the right and left hepatic ducts and bile drainage was established. A bronchoscopy was performed and a bronchobiliary fistula was diagnosed. Bronchoscopy showed massive bilious secretions from the right lower lobe bronchus (Figure 2). Unfortunately, these interventions and frequent endoscopic retrograde biliary drainage (ERBD) were not effective, and after 10 days, biliary stent obstruction led to chest tightness, dyspnea and yellow sputum discharge. The surgical team decided to resect the fistula and the involved lung.

Before the surgery, due to the large volume of yellow sputum, there was a concern that one lung ventilation could not be performed effectively and positive-pressure ventilation would cause ventilatory leakage, pneumothorax, or pneumoperitoneum.

The patient's preoperative laboratory results were as follows: complete blood count (CBC) [white blood cell, 13,300/mm³; hemoglobin, 12.1 gr/dl; platelet, 402000/ml]; total and direct bilirubin of 3 mg/dL and 1.2mg/dL, respectively; alkaline phosphatase of 449IU/L; albumin of 3.2g/dL; international normalized ratio of prothrombin time(INR) of 1.6 and arterial blood gas (ABG) [pH 7.34, PaCO₂ 33 mmHg, PaO₂ 60 mmHg and HCO₃

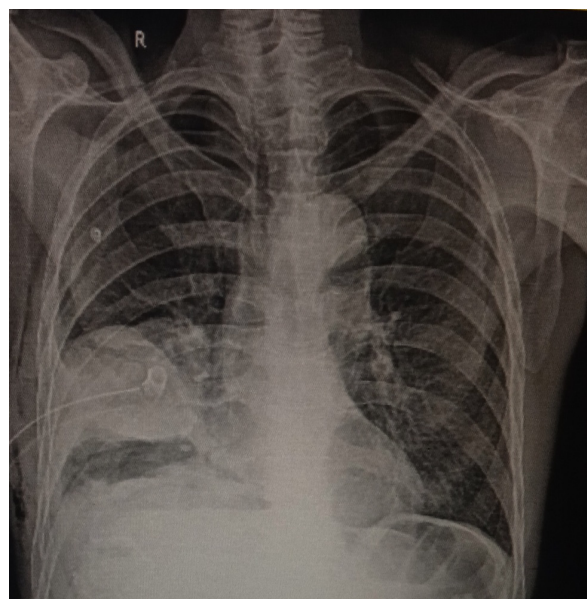


Figure 1. The preoperative chest X-ray showed right lower lobe infiltration and right pleural effusion.

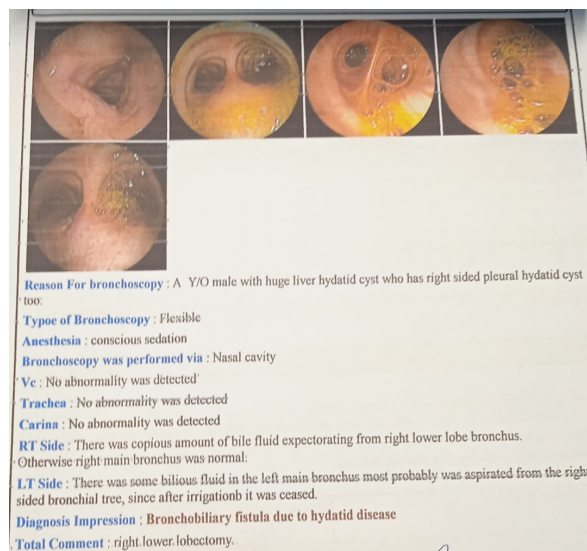


Figure 2. Massive bilious secretions from the right lower bronchus were observed in bronchoscopy.

19.2mmol/L].

On the day of the operation, the patient had a productive cough with yellow serous sputum and jaundice without any significant dyspnea in a semi-sitting position. Continuous monitoring by pulse oximetry, electrocardiogram, and non-invasive blood pressure (NIBP) was performed. The patient's vital signs were as follows: oxygen saturation (SpO₂) of 91% in room air, heart rate of 92 beats/ min, and NIBP of 111/61 mmHg. He underwent hydration and pre-oxygenation in a head-up position with 100% oxygen via a facemask for 3-5 minutes. Anesthesia was induced with rapid sequence induction with propofol 100mg and rocuronium 70mg, followed by the insertion of a left-sided double-lumen endobronchial tube (DLT, human-broncho, 37 Fr). Immediately the tracheal and bronchial cuffs were inflated and the proper location of DLT and ensuring that the

right lung was not ventilated due to the presence of fistula was confirmed by auscultation and fiberoptic bronchoscopy (FOB), and both lungs were ventilated with fraction of inspired oxygen (FiO_2) 100%. Propofol (50-75 mcg/kg/min) and cisatracurium infused as the maintenance of anesthesia. A central vein catheter was inserted in the right internal jugular vein by the anesthesiologist and invasive blood pressure (IBP) was monitored with cannulation of the left radial artery. After insertion of DLT, bilious secretions in the trachea, carina and right bronchus were continuously suctioned under FOB. The patient was positioned in the left lateral decubitus and one-lung ventilation (OLV) with a tidal volume of 6ml/kg ideal body weight, respiratory rate of 16/min, FiO_2 100% and positive end-expiratory pressure (PEEP) of 5cm H_2O was started. The patient's SpO_2 was then decreased to 88%, but gradually increased to 97%; Due to the increase in respiratory dead space by turning the patient to the lateral position, arterial to end-tidal CO_2 tension gradient ($\text{P}_{\text{a-ETCO}_2}$) increased and in order to maintain the eucapnia, minute ventilation was increased by 15-20%.

After frequent bronchial lavage with saline, resection of the fistula between the bronchial (right lower lobe) and biliary trees was done. Due to multiple abscesses and daughter cysts of hydatid cyst, the middle and lower lobes of the right lung were resected (Figure 3). The perforated diaphragm was repaired with sutures and a subphrenic drain was inserted.

The duration of anesthesia and operation were 350 minutes and 270 minutes, respectively. At the end of the surgery, after the recruiting maneuver with 30cm H_2O , two-lung ventilation (TLV) was reestablished. Intraoperative estimated blood loss was 800mL, and 3 Liters of crystalloid and 1 unit of packed red blood cells were administered. His hemodynamic parameters were stable (arterial blood pressure and CVP, 90/ 60 to 125/70 mmHg and 6 to 10 cm H_2O ,

respectively). Urine output was 600mL. At the end of surgery, the DLT was exchanged for a 7.5 single-lumen endotracheal tube, and the patient was extubated and transferred to the surgical intensive care unit while he had no need for mechanical ventilation postoperatively. During the operation, the patient didn't experience instability in the hemodynamic state or hypoxemia. Considering the patient's pre-operative respiratory condition and difficulty in proper positioning for placement of the thoracic epidural catheter, a patient-controlled intravenous analgesia (PCIA) pump containing fentanyl was used to relieve post-operative pain.

The patient was discharged after surgery and reported a good recovery path in follow-up periods.

Discussion

Bronchobiliary fistula in adults is indeed a rare condition leading to the passage of bile into the bronchial tree and subsequently into the sputum (biloptysis) (1). While congenital broncho-biliary fistulas can occur, they are relatively uncommon. The most common causes of acquired broncho-biliary fistulas in adults include thoracoabdominal trauma, such as penetrating injuries or blunt force trauma, which can disrupt the normal anatomical barriers between the biliary system and the bronchial tree. In addition to trauma, iatrogenic injury during surgical procedures involving the liver, gallbladder, or bile ducts can also lead to the formation of broncho-biliary fistulas. This can occur as a complication of procedures like cholecystectomy, hepatic resection, or biliary tract surgeries. Furthermore, longstanding biliary tract diseases and obstructions, such as chronic cholangitis, choledocholithiasis, or biliary strictures, can contribute to the development of broncho-biliary fistulas over time. Although in developing countries, the rupture of the liver hydatid cyst is the most common cause of BBF, in developed countries, biliary pathogenesis and trauma are the most common causes (9-13).

In this case, prior hepatic hydatid cyst resection and cholecystectomy may have contributed to BBF. Bile collection may have eroded the adjoining diaphragm and adhesive pleura.

The clinical presentation of BBF can vary depending on the severity of the condition and the underlying cause. Due to its rarity, broncho-biliary fistula often presents with non-specific symptoms such as cough, recurrent respiratory infections, fever, jaundice, abdominal pain, chest pain, and bilious sputum production as pathognomonic symptoms of this fistula (7, 13).

Diagnosis of BBF typically involves a combination of imaging studies such as computed tomography (CT) scans, magnetic resonance cholangiopancreatography (MRCP), and endoscopic retrograde cholangiopancreatography (ERCP), percutaneous transhepatic cholangiography (PTC), bronchoscopy or fistulography to visualize the abnormal connection between the bile ducts and bronchial tree (4, 5, 14).

Treatment options for BBF depend on the underlying cause, severity of symptoms, and overall health of the patient. In some cases, conservative management with supportive care, including respiratory hygiene, antibiotics for

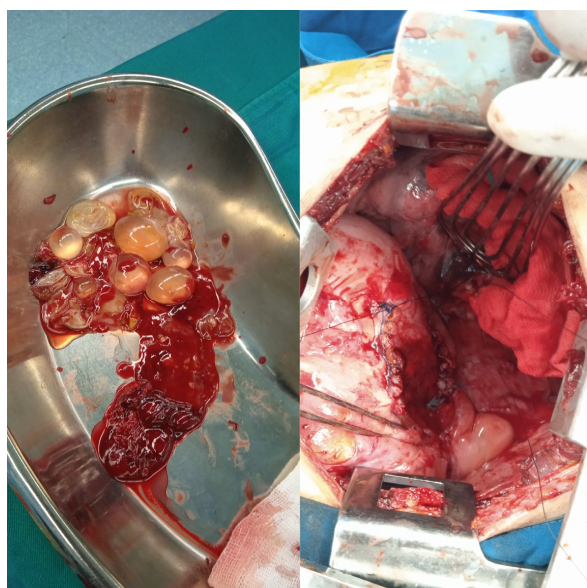


Figure 3. Daughter cysts of hydatid cysts are shown in the middle and lower lobes of the right lung.

associated infections, and nutritional support, may be sufficient. However, surgical intervention is often required when conservative therapies have failed or in more complicated cases. Resection of the involved pulmonary area and removal of the fistula, usually by lobectomy, is recommended in the form of thoracobiliary fistula decortications (7, 15).

Patients with broncho-biliary fistula present unique challenges in terms of anesthetic management. Secondary to their poor lung function preoperatively, these patients often have a compromised respiratory status. Patients often have sepsis, pulmonary function impairment, and electrolyte imbalances as a consequence of bile loss and malnutrition. All of these problems will make anesthesiologists face many perioperative challenges. The main focus of perioperative care is on antibiotic therapy, nutritional support, chest physiotherapy and postural drainage (8, 16).

While there is limited literature specifically addressing the optimal anesthetic management for patients with BBF, a multidisciplinary approach involving anesthesiologists, thoracic surgeons, and pulmonologists is crucial.

The specific anesthetic plan may vary depending on the individual patient's condition, the extent of the fistula, and the planned surgical procedure. Intraoperative problems prominently occur (arise) during thoracoscopic approach or thoracotomy and include oxygen desaturation, ventilation-perfusion (V/Q) mismatch, hypercapnia ($\text{PaCO}_2 > 45\text{mmHg}$), hypothermia and metabolic acidosis in prolonged surgeries (17).

During surgery, absolute lung isolation is typically necessary to prevent contamination of the non-operated lung, with infected or contaminated secretions from the affected lung. Achieving effective lung isolation can be challenging due to the presence of the fistula, and the main goal of anesthesia management in these patients is avoidance of positive-pressure ventilation (PPV) before lung isolation since PPV can potentially increase the risk of air leakage through the fistula (8, 18). In this case, one-lung ventilation was achieved with a left-sided double-lumen endotracheal tube (DLT); whereas other devices, such as bronchial blockers or specialized devices like Univent tubes, can also be employed (19). In patients with BBF, DLT has the following advantages: it prevents contamination of the healthy lung, allows bile drainage and provides CPAP application to correct intraoperative hypoxemia (20). The choice of the technique will depend on the location and the size of the fistula. Using DLT in BBF cases provides lung separation, selective lung ventilation, bronchial lavage, and effective blood oxygenation, which are of particular interest in the intraoperative management of such cases.

Close monitoring of oxygenation, ventilation, airway pressures, and hemodynamics are essential during surgery to help detect any signs of air leakage or compromised lung function promptly. Arterial blood gas analysis and continuous pulse oximetry can help assess the adequacy of oxygenation during lung isolation.

Postoperatively, patients may require intensive respiratory support, including mechanical ventilation, chest tube drainage, and appropriate antibiotic therapy. Close moni-

toring in an intensive care unit (ICU) setting is often necessary (8, 20).

It's important to note that the management of bronchobiliary fistula requires a multidisciplinary approach involving anesthesiologists, surgeons, and other specialists. The specific anesthetic plan may vary depending on the individual patient's condition, the extent of the fistula, and the planned surgical procedure.

Conclusion

Bronchobiliary fistula is a rare condition that carries a high risk of morbidity and mortality. Patients with bronchobiliary fistula often have compromised lung function prior to surgery, making perioperative respiratory management and intraoperative double-lumen tube insertion crucial for their care.

Authors' Contributions

Conceptualization: Rokhtabnak F. Supervision: Rokhtabnak F, Baghai-Wadji M, Nouri N. Writing-original draft: Morovati Sharifabadi F. Writing-review and editing: Nouri N.

Ethical Considerations

A detailed explanation written informed consent was obtained from the participant.

Acknowledgment

None declared.

Conflict of Interests

The authors declare that they have no competing interests.

References

- Cheng AC, Chen HW, Chen PJ, Huang TY, Lin JC. Bronchobiliary Fistula. *Intern Emerg Med*. 2021;16:1093-4.
- Peacock TB. Case in which hydatids were expectorated, and one of suppuration in a hydatid cyst of the liver communicating with the lungs. *Edinb Med Surg J*. 1850 Jul 1;74(184):33-46.
- Nassar Y, Hida S, Richter S. A Biliobronchial fistula in a patient with hepatocellular carcinoma treated with chemoembolization diagnosed by hepatobiliary iminodiacetic acid scan and managed by endoscopic retrograde cholangiopancreatography. *Gastroenterol Res*. 2017;10(6):383.
- Baig S, Mandal A, Sen S. Bronchobiliary fistula. *J Minim Access Surg*. 2008;4:111.
- Aydin U, Yazici P, Tekin F, Ozutemiz O, Coker A. Minimally invasive treatment of patients with bronchobiliary fistula: a case series. *J Med Case Rep*. 2009;3:23.
- Ammirabile A, Rizzo DA, Pedicini V, Lanza E. Percutaneous treatment of bronchobiliary fistula: report of a successful transhepatic embolization and a decision-making strategy driven by systematic literature review. *Cardiovasc Intervent Radiol*. 2021;44:1005-16.
- Liao GQ, Wang H, Zhu GY, Zhu KB, Lv FX, Tai S. Management of acquired bronchobiliary fistula: a systematic literature review of 68 cases published in 30 years. *World J Gastroenterol*. 2011;17:3842-3849.
- Mitra S, Bhatia N, Dey N, Dalal U. Bronchobiliary fistula: an anesthetic challenge! *J Clin Anesth*. 2009;21:360-362.
- Boyd DP. Bronchobiliary and bronchopleural fistulas. *Ann Thoracic Surg*. 1977;24:481-7.
- Li TY, Zhang ZB. Congenital bronchobiliary fistula: a case report and review of the literature. *World J Clin Cases*. 2019;7(7):881.
- Nathani A, Alley M, Modi A, Narayan S, Beegle SH. Bronchobiliary

- fistula caused by diaphragmatic invasion of a hepatic tumour. Case Rep. 2018;2018:224753.
12. Guruvaiiah N, Ponnatapura J. Bronchobiliary fistula: a rare postoperative complication of spilled gallstones from laparoscopic cholecystectomy. BMJ Case Rep. 2021;14(7):e243198.
 13. Eryigit H, Oztas S, Urek S, Olgac G, Kurutepe M, Asim Kutlu C. Management of acquired bronchobiliary fistula: 3 case reports and a literature review. J Cardiothorac Surg. 2007;2:52.
 14. Najjar AG, Maghrabi LA, Yamani IT, Sersar SI. Biliothorax: Review of 3 Centers Experience. World J Surg Surgical Res. 2018;1.
 15. Coughlin JM, Bonomo S, Chan EY, Hasan J, Grevious MA, Geissen N. Surgical Management of Bronchobiliary Fistula After Thoracoabdominal Trauma. Am Surg. 2022 Jun;88(6):1343-1345.
 16. Rose DM, Rose AT, Chapman WC, Wright JK, Lopez RR, Pinson CW. Management of bronchobiliary fistula as a late complication of hepatic resection. Am Surg. 1998;64:873-876.
 17. Yin H, Zhao G, Du Y, Zhao P. Anesthesia management in neonatal congenital bronchobiliary fistula: case report and literature review. BMC Anesthesiol. 2020; 20: 135.
 18. Lee J, Mee Jung S, Lee Y, Kim SY. Anesthetic management for a patient with bronchobiliary fistula after pancreaticoduodenectomy. Medicine (Baltimore). 2019 May;98(19):e15694.
 19. Chandran R, Batra RK, Agarwala S, Mishra R. Selective bronchial blockade with Fogarty catheter in a child with acquired bronchobiliary fistula. Paediatr Anaesth. 2013;23:373-5.
 20. Carr A, Gonzalez N, Hernandez-Alejandro R, Arellano R. A Case Report of the Anesthetic Management for Liver Retransplantation in a Patient With a Bronchobiliary Fistula. A A Case Rep. 2016;7:219-221.