




Transcutaneous Lower Blepharoplasty with Midface Lift by Malar Fat Suspension to Lateral Part of Infraorbital Wall

Mahmoud Abdelhamid Elhendawy¹, Ahmed M Omran^{2*} , Sherif Hamdeno², Hazem Dahshan², Ahmed Abu_Elsoud², Ahmed Salem², Mohamed Ali Abdelaziz², Khallad Sholkamy², Saber M. Abdelmaksoud³

Received: 12 Apr 2024

Published: 31 Jul 2024

Abstract

Background: The anatomy of the eyelid changes with age. Multiple changes were observed in the eyelids and the surrounding structures including the malar region. Aging affects the appearance of eyelids and midface by the formation of tear trough deformity and malar flattening and ptosis. To define the effect of malar fat suspension on the lateral part of the infraorbital wall and orbital fat transposition in tear-trough and malar flattening and ptosis.

Methods: A retrospective study was carried out on 15 patients who had surgeries between January 2020 and January 2022. This technique combines orbital fat transposition to the medial side of the infraorbital wall and malar fat suspension to the lateral side of the infraorbital wall. The average follow-up period was 12 months. Values were compared by paired samples student or Wilcoxon signed rank test for quantitative and qualitative data respectively.

Results: There was a significant improvement in tear trough deformity, malar ptosis, and midface lift ($P < 0.5$). No recurrence was observed on follow-up of 12 months. One patient experienced minor postoperative complications in the form of prolonged ecchymosis for 2 months.

Conclusion: The transcutaneous lower blepharoplasty with orbital fat transposition and malar fat suspension to the lateral part of the infraorbital wall can be considered a safe and effective intervention with improved aesthetic outcome. Thus, it is recommended in patients with tear trough deformity and malar ptosis.

Keywords: Blepharoplasty, Malar ptosis, Midface lift, Lower eyelid

Conflicts of Interest: None declared

Funding: None

***This work has been published under CC BY-NC-SA 1.0 license.**

Copyright© Iran University of Medical Sciences

Cite this article as: Elhendawy MA, Omran AM, Hamdeno S, Dahshan H, Abu_Elsoud A, Salem A, Abdelaziz MA, Sholkamy K, Abdelmaksoud SM. Transcutaneous Lower Blepharoplasty with Midface Lift by Malar Fat Suspension to Lateral Part of Infraorbital Wall. *Med J Islam Repub Iran*. 2024 (31 Jul);38:88. <https://doi.org/10.47176/mjiri.38.88>

Introduction

Facial aging is manifested initially by ptosis of the palpebral soft tissues. The nasojugal groove (also known as “tear trough”) formed under the eyes after the age of 20 years.

This groove extends laterally, as a result of growth, over time (1, 2). This was associated with the development of ptosis (3, 4).

Corresponding author: Dr Ahmed M Omran, Omranplasticsurgeon@gmail.com

¹ Department of Plastic Surgery, Faculty of Medicine, Al-Azhar University, Assiut, Egypt

² Department of Plastic Surgery, Damietta Faculty of Medicine, Al-Azhar University, Damietta, Egypt

³ Department of Plastic Surgery, Faculty of Medicine, Port Said University, Port Said, Egypt

↑What is “already known” in this topic:

Age-related changes of the face (especially lower lid and mid-face) are common. It usually leads to trough deformity, malar flattening, and ptosis. Blepharoplasty is the standard treatment option. Different methods are currently in use for transcutaneous lower lid blepharoplasty. However, most of these techniques usually remove the malar fat. The results are contradictory.

→What this article adds:

In short, we described the results of our transcutaneous lower blepharoplasty with the preservation of malar fat. The technique can be considered as a novel modification for the traditional lower lid blepharoplasty. Results showed that there was a significant improvement in tear trough deformity, malar ptosis and midface lift. No recurrence was reported in the first year after surgery. One minor postoperative prolonged ecchymosis for 2 months was reported. This reflected the value and safety of this technique.

The midface represents an important aesthetic subunit of the face. It may display many of the tell-tale signs of aging. Of importance, it must be noted that the aging process affects each layer of the midface. The changes become evident as early as the third decade of life. The smooth concavity of the eyelid-check junction is changed into a double convexity with aging. This is due to the descent of atrophic skin and attenuation of the orbicularis muscular tissue, which is usually associated with outward pseudo-herniation of orbital fat. Tarsoligamentous laxity leads to visible lengthening of the lower lid (i.e., tarsus supported reduced by aging due to laxity of ligamentous and tendentious support of the tarsus, with subsequent laxity and increased horizontal diameter of the lower eyelid). The process is sometimes described as the senile ectropion (5).

With the advancement of the process, the superolateral boundary of the mid-face showed the development of Crow's-feet form. The malar prominence was reduced, and the inferior orbital rim was skeletonized with the creation of a hollowed appearance. This was attributed to the ptosis and descent of soft tissues over the malar eminence (mainly, the subcutaneous malar fat pad and midface retaining ligaments). A nasojugal trough becomes apparent medially, leading to the development of the so-called tear trough deformity. The dependent region of the nasolabial crease becomes burdened with ptotic superolateral soft tissues, giving rise to a hooded appearance and a deepening of the fold (5-7).

The midface is constituted of the lower eyelid, bony orbital rim, maxilla, malar, and suborbicularis oculi fat (SOOF) pads. In addition to the mimetic muscles (orbicularis oculi, zygomaticus major and minor, and masseter). The fatty constituents of the mid-face include the soft tissue structures of the malar fat pad and SOOF. The junction between the lower lid and the cheek is characterized by a curved line. This line runs below and parallel to the infra-orbital rim. It defines the transition between the palpebral and orbital divisions of the orbicularis oculi muscle. Superior to this junction in the skin of the lower eyelid. This skin is thin and directly lies over the muscle. On the other side, the skin below this junction is thicker and separated from the muscle by the malar fat pad. The orbicularis oculi is attached firmly to the bony orbital rim along the medial aspect of the lid-cheek junction. Laterally, the muscle attached to the orbicularis retaining ligament, which in turn attaches to the bony orbital rim (8, 9).

The SOOF is composed of two compartments: the medial extending from the medial limbus to the lateral canthus and the lateral extending from the lateral canthus to the temporal fat pad (10).

The malar fat pad includes a triangular subcutaneous fat thickening in the cheek, superficial to the superficial musculoaponeurotic system (SMAS) covering the maxilla, which forms the majority of the midface volume (8, 9).

The zygomaticus major and minor muscles are enclosed by the SMAS and are positioned superficial to the SOOF and deep to the malar fat pads. The sum of these parts produces the contour of the youthful midface, which looks like a single continuous smooth convexity extending from the lower lid margin to the oral commissure (11, 12).

This work aimed to define the effect of malar fat suspension on the lateral part of the infraorbital wall and orbital fat transposition in tear-trough and malar flattening and ptosis.

Methods

This was a retrospective study. Data on all patients who had undergone this technique was collected. The aesthetic appearance was assessed using the Garcia-McCollough scale for Lower Eyelid Appearance. It consists of three domains: the overall appearance, visibility of the scar, and eyelid position. Each domain consists of five grades (1 to 5). The overall appearance is scored 1 if the eyelid contour is worsened, 2 for no improvement in eyelid contour, 3 for minimal improvement in eyelid contour, 4 for moderate improvement in eyelid contour, and 5 for significant improvement in eyelid contour. The visibility of the scar scored 1 for elevated, hypertrophic scar, 2 for flat but widened scar, 3 for flat but thin scar, 4 for barely perceptible scar, and 5 for imperceptible scar. The eyelid position scored 1 for frank ectropion, 2 for canthal rounding with a significant scleral show, 3 for mild eyelid retraction with scleral show, 4 for unchanged scleral show, and 5 for improved scleral show (13).

In addition, malar ptosis was evaluated by preoperative and postoperative photos. Finally, patient satisfaction with the aesthetic outcome was subjectively evaluated by the patient. Any complications during the follow-up period were recorded.

Surgical technique

The patient underwent local anesthesia (200 ml normal saline with 1 ml of epinephrine 1mg. Then 20 ml was taken from this solution and added on 20 ml of lidocaine 2%). Finally, 10-15 from the second solution were used for the lower eyelid anesthesia of each eye. A subciliary incision was made and continued laterally to the lateral canthus and then extended inferolateral, corresponding to the crow's feet line (Figure 1). The skin of the lower eyelid is incised horizontally 2-3 mm inferior to the lower lid margin with a No. 15 Bard-Parker blade only through the skin. Dissection with tenotomy scissors to prevent any damage to the hair follicles. The skin flap elevated without orbicularis oculi muscle for about 5mm. Undermining is performed through the orbicularis oculi muscle while maintaining the pre-tarsal strip of the orbicularis oculi muscle (3-4 mm). Maintaining this muscle portion intact was important for lower eyelid closure and support. Skin muscle flap was elevated with exposure of the orbital septum and dissection extended down to the infraorbital wall with the release of orbitomalar ligament. Then, the orbital septum is opened, so the orbital fat is herniated. At this time, meticulous hemostasis is important for bipolar to avoid the most dinger complication retrobulbar hematoma. Then the herniated excess orbital fat is redistributed over the medial half of the infraorbital wall by a vicryl suture 5/0, stitch the herniated excess orbital fat to the periosteum of the infraorbital wall BY interrupted horizontal mattress suture (Figure 2). The redistribution of

orbital fat and release of orbto-malar ligament, led to the correction of tear trough deformity and created a smooth

connection between the lower eyelid and cheek. Then dis-

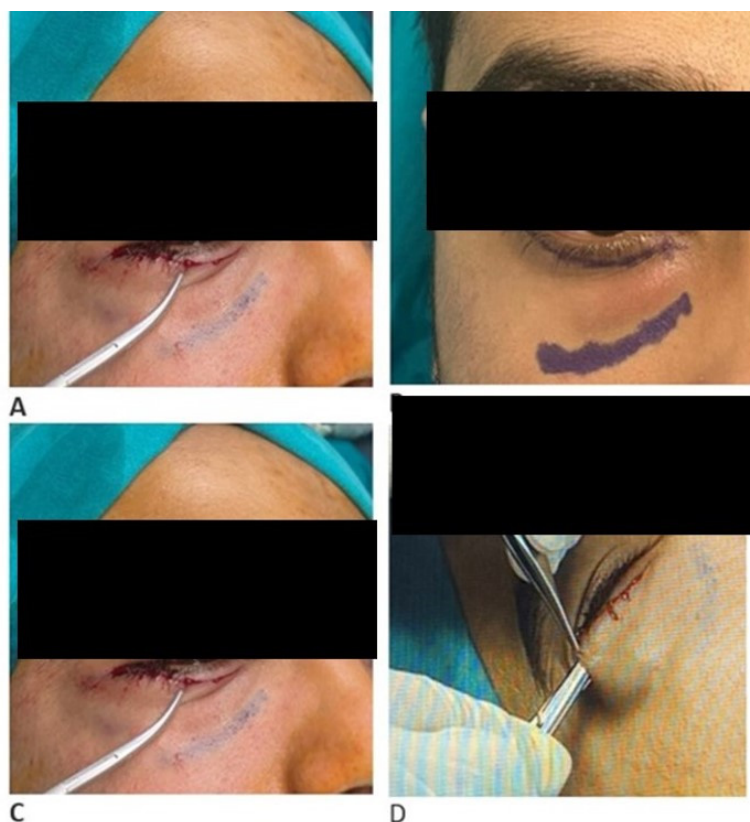


Figure 1. Anaesthesia, incision and initial dissection (A) subciliary incision marking with lateral extension (B) local anesthesia (C) subciliary incision with lateral extension (D) blunt dissection of the skin flap.

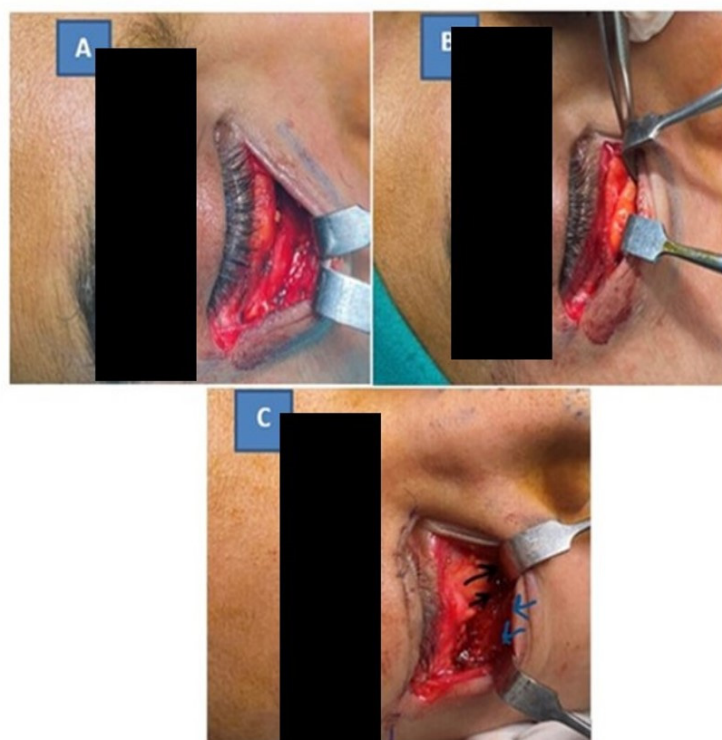


Figure 2. Complete dissection with redistribution of orbital fat and suspension of malar fat (A) Complete dissection down to infraorbital wall (B) Open the orbital septum with orbital fat herniation (C) redistribution of orbital fat to the medial half of inferior orbital wall marked direction by black arrow and suspension of malar fat to the lateral half of the infraorbital wall marked by blue arrow.

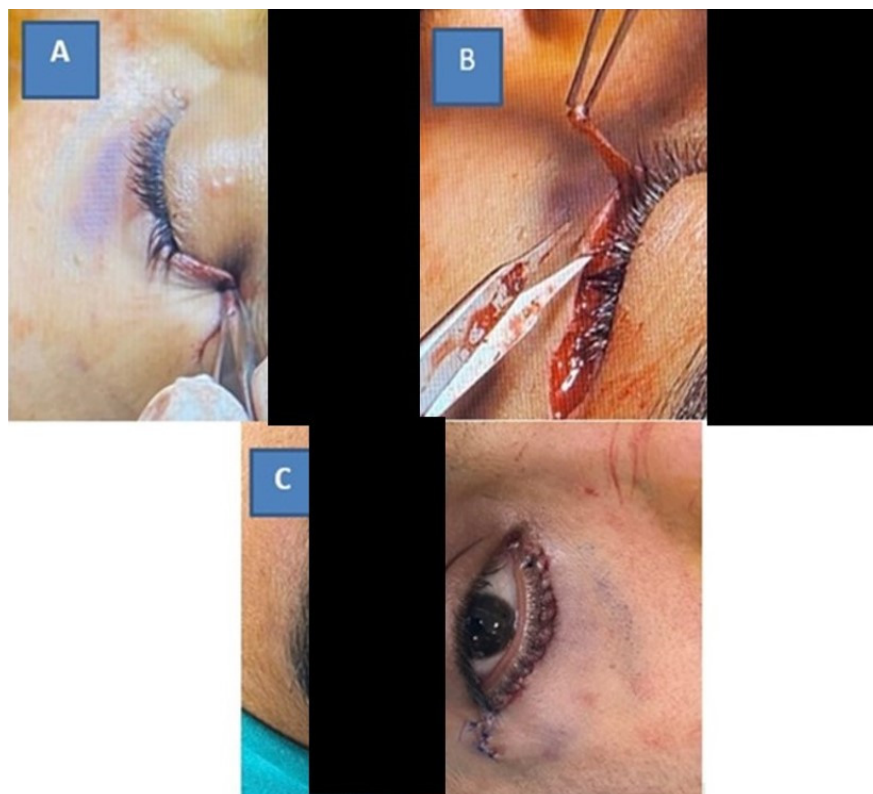


Figure 3. Excision of excess skin and closure (A) excision of the lateral triangle of excess skin direction of pull upwards and laterally (B) excision of skin at lower eyelid (C) closure of the skin with immediate postoperative result

section continues inferior to the infraorbital wall to the malar fat pad and then suspends the malar fat upward and laterally to the lateral half of the infraorbital wall by stitching the malar fat at the periosteum of the lateral half of the infraorbital fat by interrupted mattress suture this led to correction of malar ptosis and improved the nasolabial fold (mid face lift). The extra lower eyelid skin is excised leaving enough skin to prevent postoperative ectropion not exceeding 3mm and also excised excess triangle shape skin lateral to lateral canthus (Figure 3). This further elevates the cheek securing it in this position and eliminating downward pull on the lower eyelid margin, closing the skin by proline 5/0 continuous suture. Postoperatively the patients are nursed in a head-up position with cooling goggles placed above the surgical site.

Patient satisfaction was assessed subjectively by the patient on a 3-grade Likert scale (0 indicates dissatisfaction, one for neutral situation, and two for satisfaction). Patients with neutral situations were considered as dissatisfied for the purpose of statistical analysis.

Data analysis: The collected data was summarized by mean and standard deviation for continuous normally distributed data. On the other side, categorical data were summarized by the relative frequency (number) and percentages. Variables were analyzed by paired samples student test if continuous and Wilcoxon signed rank test for categorical data. P value < 0.05 was considered significant.

Results

This technique was performed for 15 patients between January 2020 and January 2022 (14 were female (93.3%),

and one patient was male (6.7%). The mean age was 42 (27-55) years. The mean operative time taken at one eye was 39 (35-45) minutes.

The average follow-up time was 12 months. All patients were satisfied with the aesthetic appearance. However, 14 (93.3%) patients were satisfied for early postoperative and one patient (6.7%) was satisfied for late (after 6 months) due to delayed resolve of oedema and ecchymosis for 2 months postoperatively.

There were no post-operative major complications (e.g., ectropion, lid retraction, scleral show, retrobulbar hematoma or infection). Minor complications were recorded for one patient (6.7%) in the form of persistent edema and ecchymosis for more than 2 months. This patient was managed conservatively by hot fomentation and massage and showed improvement and satisfaction. Figures 4 to 6 compared pre- to post-operative outcomes in some patients (with their permission).

Discussion

The current technique differs in many aspects from other available techniques used for lower blepharoplasty. We work to lift the mid-face, which works to improve the malar ptosis and improve deepens the nasolabial fold with enhanced malar prominence. It is suitable for better aesthetic outcomes for patients with malar hypoplastic eminence. The entire operation was performed using local anesthesia. This helps evaluate the position of the lower eyelid in relation to the lower limbus by constantly asking the patient during the operation to open and close the eyelids so that

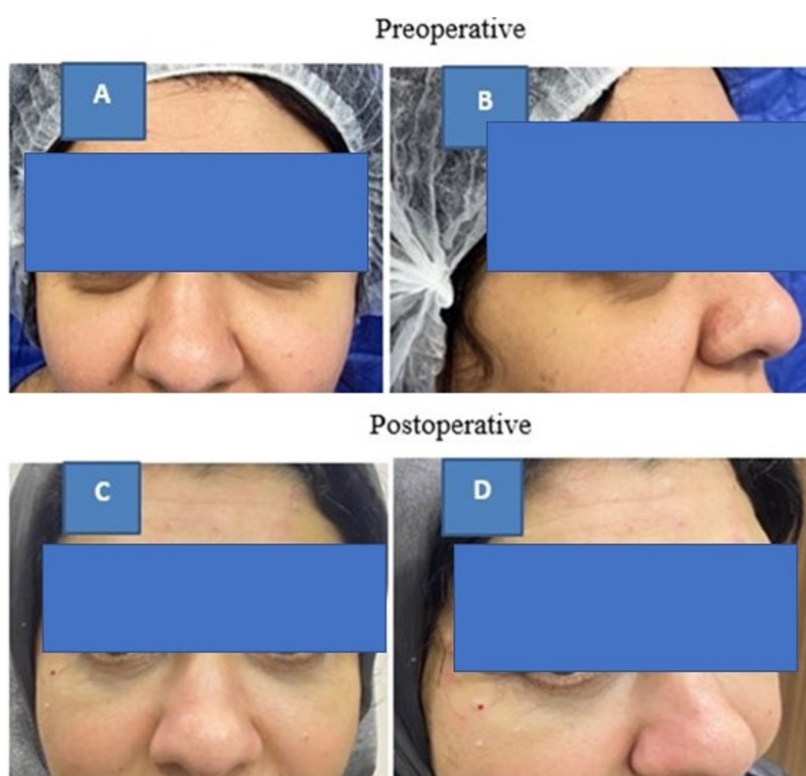


Figure 4. Pre-and post-operative outcome. (A and C) pre- and post-operative frontal view. (B and D) pre- and post-operative lateral view.

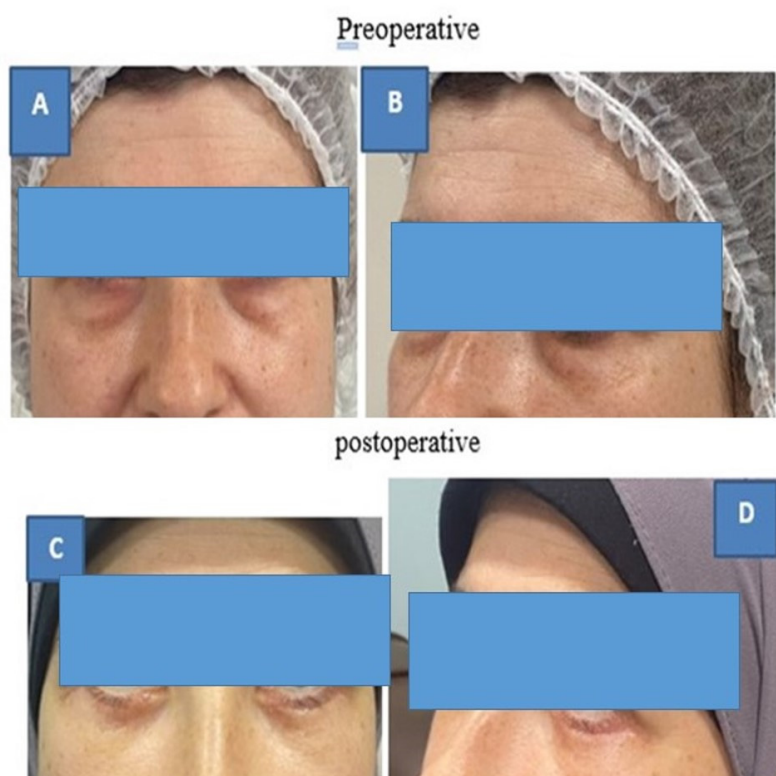

Figure 5. Pre- and post-operative outcome. (A and C) pre- and post-operative frontal view. (B and D) pre- and post-operative lateral view.

we can be assured that there will be no ectropion. In addition, using a local anesthetic protects from the risks of general anesthesia hazards that may occur, especially in elderly

patients who may suffer from chronic medical problems, especially since most of the patients who need this surgery are elderly.

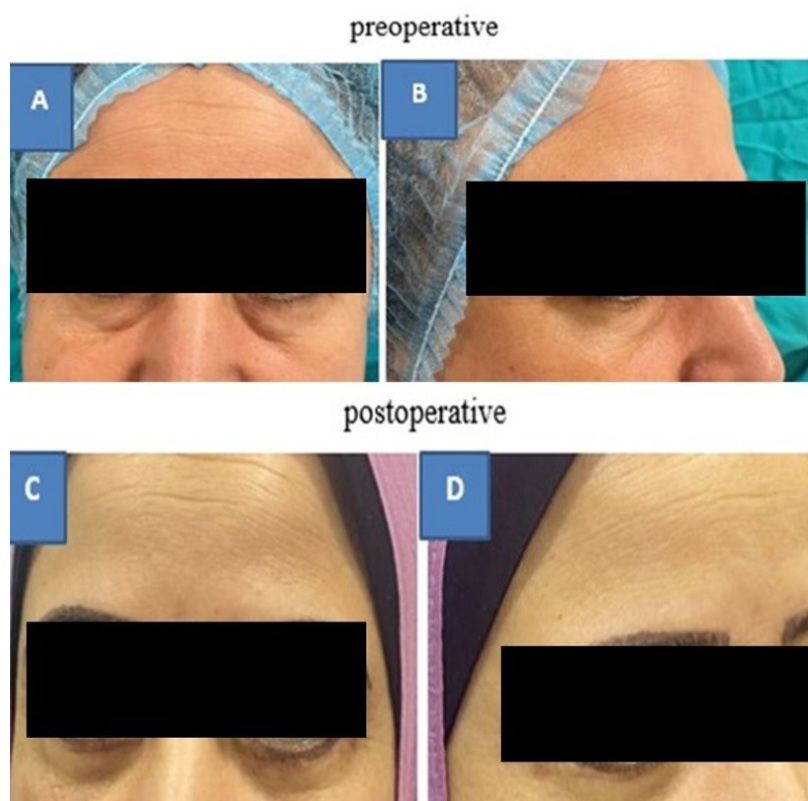


Figure 6. Pre- and post-operative outcome. (A and C) pre- and post-operative frontal view. (B and D) pre- and post-operative lateral view.

Interestingly, the surgical incision in the current work was a subciliary incision made at the level of the skin only. The skin flap was raised alone for 5 mm, and then the skin muscle flap was elevated. The muscle incision was 5mm inferior to the skin incision. This helps preserve the tarsal part of the orbicularis oculi muscle which gives support to the lower eyelid and guards against postoperative ectropion. In addition, the two incisions for the skin and the muscle were not at the same level so as not to increase the possibility of ectropion of the lower eyelid. Furthermore, dissection in the current technique extends to the infraorbital wall along with the release of the orbito-malar ligament, which is crucial for correcting tear-through deformities. In order to rectify the depression that was present in the tear trough deformity, we also opened the orbital septum and redistributed the herniated fat over the medial half of the infraorbital wall rather than excising it. So, we can rectify the tear trough deformity and make a smooth connection between the lower eyelid and cheek by releasing the orbito-malar ligament and redistributing herniated fat after opening the orbital septum on the medial side of the infraorbital wall. Also, in our technique, the midface was lifted via dissection that extended down to the infraorbital wall and reached the malar fat pad. From there, the malar fat pad was suspended upward and laterally to the lateral half of the periosteum of the infraorbital wall, correcting the malar ptosis and improving the nasolabial fold.

Additionally, the described method minimizes the amount of skin removed from the lower eyelid—just 3

mm—in order to prevent ectropion of the lower eyelid. Additionally, it removes excess triangle skin lateral to the lateral can, thus enhancing the elevation and lift of the mid-face without endangering the stability of the lower eyelid or resulting in ectropion.

Pepper and Baker (14) conducted a review of transcutaneous blepharoplasty of the lower lid with fat preservation to rejuvenate the aging lower lid. The authors stated that this technique is their preferred one, with technical refinements based on a conceptual framework developed in the last 20 years by several researchers. They added that the use of suspension flap of orbicularis oculi is a useful adjunct to the transcutaneous technique of lower lid blepharoplasty. In addition, Jacono (15) concluded that the lower eyelid transcutaneous blepharoplasty is a recommended and powerful rejuvenation technique when orbicularis oculi muscle is preserved and the eyelid is supported with additional suspensory methods, including canthopexy and muscle flap suspension sutures. In addition, the preservation of orbital fat or transposition of this fat and/or autologous fat grafting is associated with more complete results.

Guner (16) published his experience with percutaneous lower lid blepharoplasty for 297 patients who were performed over 10 years (from 2008 to 2018) with an average of 58.8 months follow-up period. He recorded satisfaction for all patients and only 1 patient had chemosis that subsided by steroid ointment. He concluded that his novel technique is simple, fast, had low complications, and had a good aesthetic outcome. In addition, it corrects the tear

trough deformity and avoids violation of lamellar structures. However, he – other than us – used removal of fat, but we preserved it.

Ramesh et al. (17), in an interesting study, compared the nasojugal fold depth and length of the lower eyelid in lower lid blepharoplasty and concluded that the excision of fat led to a shorter lower eyelid. However, fat transposition (preservation) led to a more effaced lid-cheek junction. They recommended that plastic surgeons must be able to balance fat excision with fat transposition to deliver the best aesthetic results.

Conclusion

The transcutaneous lower blepharoplasty with orbital fat transposition and malar fat suspension to the lateral part of the infraorbital wall technique could be considered as a safe and effective technique. It provided an improved aesthetic outcome. Thus, it can be advocated for patients with tear trough deformity and malar ptosis. However, due to the two limiting steps of the small number of patients and the retrospective nature of the study, the results must be treated with caution, and globalization of the results needs future studies.

Authors' Contributions

All authors Contributed equally to this work.

Ethical Considerations

Non Applicable (Retrospective Study).

Acknowledgment

None.

Conflict of Interests

The authors declare that they have no competing interests.

References

1. Fezza JP, Massry G. Lower Eyelid Length. *Plast Reconstr Surg*. 2015 Aug;136(2):152e-159e.
2. Lambros V. Discussion: Lower Eyelid Length. *Plast Reconstr Surg*. 2015 Aug;136(2):160e-161e.
3. Hirmand H. Anatomy and nonsurgical correction of the tear trough deformity. *Plast Reconstr Surg*. 2010 Feb;125(2):699-708.
4. Liew S, De Silva D. Tear Trough and Lid-Cheek Junction Anatomy: Current Understanding and Nonsurgical Treatment. *Facial Plast Surg*. 2022 Apr;38(2):143-151.
5. Sclafani AP, Dibelius G. Transpalpebral midface lift. *Facial Plast Surg Clin North Am*. 2015 May; 23(2):209-19.
- 6- Dibbs RP, Chamata E, Ferry AM, Friedman JD. Revision Facelift and Neck Lift. *Semin Plast Surg*. 2021 May;35(2):88-97.
7. Marten T, Elyassnia D. Male Facelift. *Clin Plast Surg*. 2022 Apr;49(2):221-256.
8. Shaw RB Jr, Katzel EB, Koltz PF, Yaremchuk MJ, Girotto JA, Kahn DM, Langstein HN. Aging of the facial skeleton: aesthetic implications and rejuvenation strategies. *Plast Reconstr Surg*. 2011 Jan;127(1): 374-383.
9. Mendelson B, Wong CH. Changes in the Facial Skeleton With Aging: Implications and Clinical Applications in Facial Rejuvenation. *Aesthetic Plast Surg*. 2020 Aug;44(4):1151-1158.
10. Seo YS, Song JK, Oh TS, Kwon SI, Tansatit T, Lee JH. Review of the Nomenclature of the Retaining Ligaments of the Cheek: Frequently Confused Terminology. *Arch Plast Surg*. 2017 Jul;44(4):266-275.
11. Quatela VC, Antunes MB. Transtemporal midface lifting to blend the lower eyelid-cheek junction. *Clin Plast Surg*. 2015 Jan;42(1):103-14.

12. Ugradar S, Kim JS, Massry G. A Review of Midface Aging. *Ophthalmic Plast Reconstr Surg*. 2023 Mar-Apr 01;39(2):123-131. doi: 10.1097/OPRS.0000000000001000.
13. Garcia RE, McCollough EG. Transcutaneous lower eyelid blepharoplasty with fat excision: a shift-resisting paradigm. *Arch Facial Plast Surg*. 2006 Nov-Dec;8(6):374-80.
14. Pepper J-P, Baker SR. Transcutaneous Lower Blepharoplasty with Fat Transposition. *Clin Plastic Surg*. 2015;42:57–62.
15. Jacono AA. Transcutaneous Blepharoplasty with Volume Preservation: Indications, Advantages, Technique, Contraindications, and Alternatives. *Facial Plast Surg Clin North Am*. 2021 May;29(2):209-228.
16. Guner H. Percutaneous Lower Blepharoplasty: A Novel Technique in Lower Eyelid Aesthetics. *J Craniofac Surg*. 2020 Mar/Apr;31(2):e140-e144.
17. Ramesh S, Goldberg RA, Wulc AE, Brackup AB. Objective Comparison of Nasojugal Fold Depth and Lower Eyelid Length After Fat Excision Versus Fat Transpositional Lower Blepharoplasty. *Aesthet Surg J*. 2019 Sep 13;39(10):1048-1054.