

## PREVENTIVE EFFECTS OF VITAMIN A AND ASPIRIN ON UV LIGHT-INDUCED RETINOPATHY IN AN ANIMAL MODEL

H.A. SHAHRIARI, M.D., AND A.M. SALARI, M.D.

*From the Dept. of Ophthalmology, Zahedan University of Medical Sciences, Zahedan, I.R. Iran.*

### ABSTRACT

In order to identify the effects of vitamin A and aspirin on reducing UV light-induced retinopathy, ERG waves were compared before and after UV light exposure in rabbits. 30 rabbits were divided into 3 groups: the first group received vitamin A, 50,000 units I.M., single dose, the second group received aspirin, 50 mg/kg/day PO and the third group did not receive any medication. All three groups were exposed to UV light generated by three 30 watt lamps for 14 days. Baseline ERGs were recorded for all rabbits prior to UV light exposure and the second ERG was taken 14 days after exposure.

The control group showed a 62.6% decrease in voltage amplitude from the baseline of photopic flicker 30 Hz ERG. This decrease was 28.6% for those who received vitamin A and only 8.8% for those who received aspirin. Regarding photopic single flash ERGs, the decrease in the voltage amplitude for control, vitamin A and aspirin groups was 49.02%, 26.14% and 24.83%, respectively.

It was therefore concluded that vitamin A and aspirin have a preventive role on the side effects of UV light in the rabbit eye retina.

Further studies are needed to elicit the appropriate dosage of aspirin and vitamin A in preventing the side effects of UV light in the human eye.

*MJIRI, Vol. 13, No. 2, 129-132, 1999*

### INTRODUCTION

Based on wave length, UV light can be divided into 3 forms:

- . UVA: 320-400  $\mu$
- . UVB: 280-320  $\mu$
- . UVC: less than 280  $\mu$

The ozone layer absorbs most of the UV sunlight. 5% of the sunlight that reaches the earth's surface is UV and from this 10% is UVB and almost 90% is UVC.

The major artificial sources of UV light are welding arcs, bactericide lamps and eximer lasers.<sup>1</sup> We know that depletion of the ozone layer results in an increase in the portion of UV light that reaches the earth's surface. Long term exposure to UV light can cause cataract and macular

degeneration.<sup>2</sup>

An epidemiologic study among jews showed that UV light might have a role in macular degeneration.<sup>3</sup> A single dose of 5 kJ/m<sup>2</sup> of UV light can cause a decrease in the amplitude of a and b components of the ERG which are observed after 2-7 days.<sup>4</sup> An exposure of 6.5 kJ/m<sup>2</sup>, five days a week for ten months in a group of rabbits showed photo-keratoconjunctivitis that disappeared after 3 weeks. At the end of the study, a and b wave amplitude decreased to 30% of normal value.<sup>5</sup>

Investigators have theorized that light may lead to the generation of activated forms of oxygen in the outer retina or choroid,<sup>6</sup> perhaps by photoactivation of protoporphyrin<sup>7</sup> (hemoglobin precursors found in erythrocytes passing through choroidal vessels).

The Chesapeake Bay Waterman Study showed no association between accumulative lifetime UV light exposure and any stage of AMD.<sup>8</sup> This study also found no association between cumulative visible light exposure and the development of the early stages of macular degeneration.<sup>8</sup>

The Beaver Dam Eye Study found a limited association between summer-time outdoor exposure and advanced AMD among male participants only.<sup>9</sup>

The Eye Disorder Case Control Study did not show a positive association between lifetime sunlight exposure and the neovascular form of macular degeneration.<sup>10</sup> But the Waterman Study did report significantly higher exposure to blue light or all wave lengths in the visible spectrum within the 20 years preceding their study participation among the eight individuals in the 900-participant study group who had geographic atrophy or neovascular AMD.<sup>11</sup>

### MATERIALS AND METHODS

In this experimental study we used 30 albino German type rabbits, each about 1300 grams in weight, purchased from Razi Institute of Tehran. They had been transported to Zahedan by air and kept in a special clean air conditioned room in Al-Zahra Eye Center, Zahedan. The site where these rabbits were kept was cleaned and disinfected every four days. Special care was taken for the protection of personnel by covering the windows by aluminium foil. The rabbits were fed special concentrated food which had been provided by Razi Institute, Tehran.

The rabbits were divided into 3 groups randomly and then grouped and numbered in a blind fashion. The drugs that they received and the numbering were controlled by a third person unbeknown to the researchers. All ERG recordings were performed by the same operator in the same room and by a Gansfield Epic 2000 device. There were five electrodes: the two corneal electrodes were jet type, and two of the other three were attached to the ears and the third one to the forehead over the nose of the rabbits. After shaving the area for good adhesion, methyl-cellulose gel was employed for a firm contact with the skin. Prior to ERG recording, all rabbits were kept in a dark room for 30 minutes and then scotopic ERG and afterwards photopic flicker (30 Hz) and photopic single flash ERGs were obtained.

### RESULTS

In this study UV light exposure retinopathy was shown as an obvious decrease in voltage amplitude before and after 2 weeks of radiation both by single flash photopic ERGs and flicker photopic ERGs (Figs. 1-4).

Although we could not use routine statistical methods such as Student's t-test and multivariate method, we have

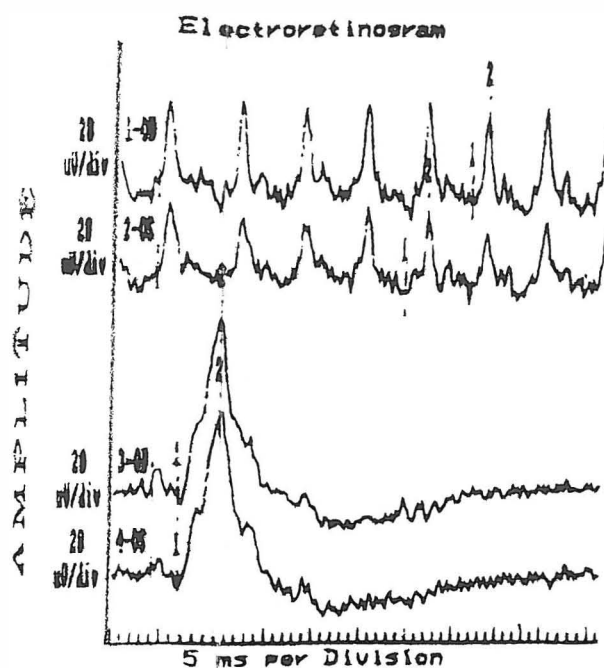


Fig. 1. Baseline ERG.

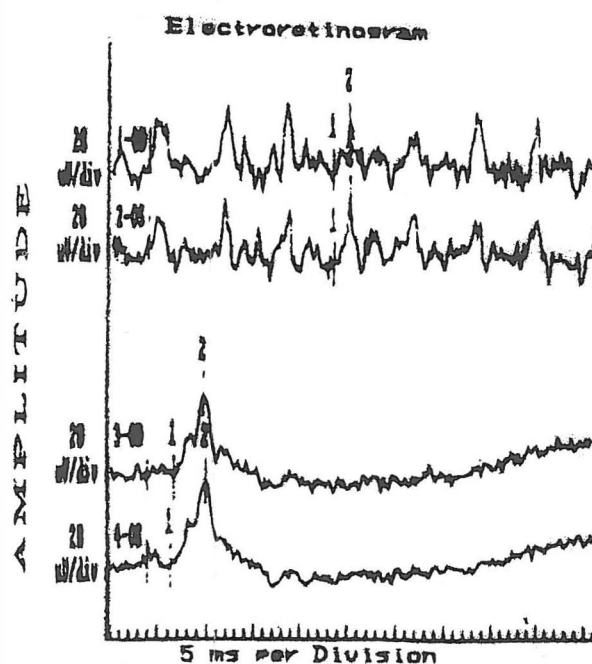


Fig. 2. Control group ERG 2 weeks post-radiation.

described mean of decrease in voltage amplitude of ERGs before and after 2 weeks of exposure to radiation for both types in all three groups. The maximum response (amplitude of b-wave minus amplitude of a-wave in microvolts) of one eye was added to the other eye and then divided by two to give the mean voltage of the rabbit's eye. Then the mean decrease in amplitude voltage before and after two weeks of radiation for both single flash and flicker 30 Hz ERGs

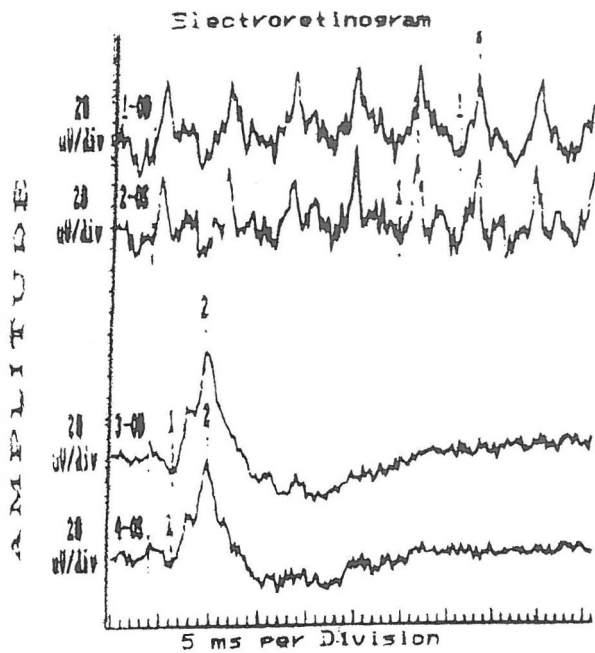


Fig. 3. Aspirin group ERG 2 weeks post-radiation.

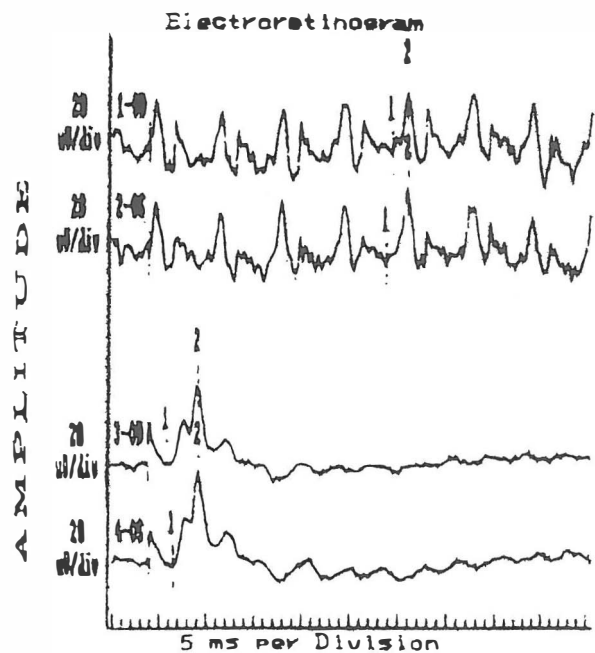


Fig. 4. Vit. A group ERG 2 weeks post-radiation.

in the voltage amplitude for the control group, vitamin A group and aspirin group was 49.02%, 26.14% and 24.83%, respectively. There was no change observed in the retina of all three groups of rabbits by indirect ophthalmoscopy.

### DISCUSSION

Previous studies concerning the effect of UV light on animal models were divided into two groups. The first group (for example the welding arc) used high intensity UV light in a single dose for a few hours, which causes keratitis. The second group used low intensity UV light and a long exposure period. An example for this group is natural UV light exposure. In our study we used an intermediate method, medium UV light intensity and medium exposure time. This method was selected because we were unable to keep the rabbits alive for a long period of time in our lab. A small brief study of oral zinc supplement in patients with drusen and/or atrophic RPE showed that during the study period of up to 2 years, zinc-treated patients lost less vision than those receiving placebo.<sup>12</sup>

Epidemiologic studies have shown that individuals with elevated blood antioxidant levels (vitamins C-E, carotenoids) are about half as likely to have AMD as individuals with relatively lower levels of blood antioxidants. There is a great deal of evidence from animal studies suggesting that UV and visible blue light may damage the retina. Since sunglasses can eliminate some degree of exposure to visible light, there appears to be no reason to discourage their use at this time.<sup>12</sup> Primate studies have shown that altered levels of dietary vitamin A or vitamin E can lead to retinal degeneration.<sup>13</sup>

Rats that receive dietary supplements of vitamin C are less vulnerable to experimentally induced retinal phototoxicity, such as loss of rhodopsin and photoreceptor nuclei compared with rats that do not receive vitamin C supplementation.<sup>14</sup>

The two studies of The Eye Disease Case Control Study Group in recent years showed a direct relation between the exudative form of ARMD and a decreased plasma level of lutein and zeaxanthin.<sup>15,16</sup> It was found that a diet rich in dark green leafy vegetables could decrease the risk of ARMD.<sup>16</sup> These data support the hypothesis that a higher intake of lutein and zeaxanthin can prevent this form of ARMD.

In one prospective, randomized clinical trial that has received significant attention, oral zinc supplementation was evaluated as a means of preventing progression of AMD.<sup>17</sup>

The Baltimore Longitudinal Study on Aging, a population based study performed at a geriatrics center in Baltimore, explored the potential connection between antioxidants and AMD in a cross-sectional study. Participants with the highest plasma levels of various

was calculated and compared. There were thus two means of decrease in voltage amplitude for each group. Our control group which was exposed to UV light alone showed a 62.6% decrease in voltage amplitude from the baseline amounts for the flicker photopic ERG. This decrease in the other two groups who received vitamin A and aspirin was 28.6% and 8.8%, respectively.

According to the photopic single flash ERGs the decrease

antioxidant substances (level of vitamins E and C and beta-carotene, as well as an antioxidant index, which was made up of all 3 micronutrients) were less likely to have any evidence of AMD when compared with participants with the lowest blood levels of the same substances, although dietary intake was not evaluated. There was no evidence that micronutrient supplements were protective against AMD.<sup>18</sup>

To date there has been no study on animal models concerning the possible preventive role of aspirin and vitamin A on UV light exposure retinopathy, but there is one report which states that vitamin C has a preventive role against the toxic effects of UV light by binding with free radicals.<sup>19</sup>

Our study shows that UV light has a pathological effect on the retina. Because the photopic part of ERGs had an obvious decrease in voltage amplitude, the cone cells are the site of the pathological effect. From this study we have concluded that the side effects of UV light on the retina can be reduced relatively by use of vitamin A or aspirin. It is known that one of the possible causes of ARMD, cataract and pterygium is long term exposure to the UV component of sunlight.

Further studies are needed to elicit the appropriate dosage of aspirin and vitamin A that could be beneficial in reducing the side effects of UV light as well as the applicability of these drugs and their effects on human beings.

### REFERENCES

1. Lerman S: Radiant energy and the eye. In: Optics, Refraction and Contact Lenses. San Francisco: American Academy of Ophthalmology, Se
2. Van Kurjk FJ: Effects of U.V. light on the eye: role of protective glasses. *Environ Health Perspect* 96: 177-84, 1991.
3. Miller D: Clinical light toxicity to the eye. In: Optics, Refraction and Contact Lenses. San Francisco: American Academy of Ophthalmology, Section 3, pp. 227-8, 1995.
4. Belousov VV, Gramenistskii Ag SO: The electroretinogram parameters and the state of cornea in the rabbit following acute exposure of the eye to U.V. radiation of different intensities. *Kosm Baol Aviakosm Med* 25(4): 38-40, 1991.
5. Belousov VM, Zaugolnikova LA, Kniazev VM, Strzhizhovskii AD SO: The effect of prolonged exposure to ultraviolet radiation in the state of the ocular media and on the parameters of the ERG in the rabbit. *Radiats Biol Radioecol* 34(2): 300-5, 1994.
6. Young RW: Solar radiation and age - related macular degeneration. *Surv Ophthalmol* 32: 252-69, 1988.
7. Gottsch JD, Byone LA, Harlan JB, et al: Light-induced deposits in Bruch's membrane of protoporphyric mice. *Arch Ophthalmol* 111: 126-9, 1998.
8. West SK, Bressler NM, Rosenthal FS, et al: Exposure to sunlight and other risk factors for age-related macular degeneration. *Arch Ophthalmol* 107: 875-79, 1989.
9. Cruickshanks KJ, Klein R, Klein BEK: Sunlight and age-related macular degeneration: The Beaver Dam Eye Study. *Arch Ophthalmol* 111: 514-18, 1993.
10. The Eye Disease Case-Control Study Group: Risk factors for neovascular age-related macular degeneration. *Arch Ophthalmol* 110: 1701-8, 1992.
11. Taylor HR, West S, Munoz B, et al: The long-term effects of visible light on the eye. *Arch Ophthalmol* 110: 99-104, 1992.
12. Bressler SB: Age related macular degeneration. In: Focal Points, Clinical Modules for Ophthalmologists. San Francisco: American Academy of Ophthalmology, Volume XIII, Module 2 (Section 2 of 3), p. 498, 1995.
13. Hayes KC: Retinal degeneration in monkeys induced by deficiencies of vitamin E or A. *Invest Ophthalmol* 13: 499-510, 1974.
14. Organisciak DT, Wang H, Livzy, Tso MOM: The protective effect of ascorbate in retinal light damage of rats. *Invest Ophthalmol Vis Sci* 26: 1580-88, 1985.
15. Eye Disease Case-Control Study Group: Antioxidant status and neovascular age-related macular degeneration. *Ophthalmol* 111: 104-9, 1993.
16. Seddon JM, Ajani UA, Sperduto RD, et al: Dietary carotenoid, vitamin A, C, and E, and advanced age-related macular degeneration. *Eye Disease Case-Control Study Group. JAMA* 272: 1413-20, 1994.
17. Newsome DA, Swartz M, Leone NC, et al: Oral zinc in macular degeneration. *Arch Ophthalmol* 106: 192-8, 1988.
18. West S, Vital S, Hallfrichsch J, et al: Are antioxidants or supplements protective for age-related macular degeneration? *Arch Ophthalmol* 112: 122-7, 1994.
19. Sebag J: The Vitreous, In: Hart WM Jr (ed.), *Adler's Physiology of the Eye, Clinical Application*. 9th ed., St. Louis: Mosby, p. 278, 1992.