

# Iatrogenic Vascular Injury During Reduction of Femoral Neck Fractures: A Cadaveric Study

Ali Yeganeh<sup>1</sup>, Amirhossein Shahbazi<sup>2</sup>, Mehdi Moghtadaei<sup>1</sup>, Mikael Hajializade<sup>3,4\*</sup> 

Received: 11 Feb 2025

Published: 25 Jun 2025

## Abstract

**Background:** The femoral head's blood supply, primarily provided by the medial circumflex femoral artery (MCFA), is vulnerable to mechanical interruptions caused by traumatic or iatrogenic events. Disruption of this blood flow is associated with an inherent risk of avascular necrosis (AVN), which significantly impairs the surgical outcomes. This study aimed to evaluate the impact of using the Bennett retractor on femoral head vascular integrity during simulated fracture reductions.

**Methods:** A descriptive cadaveric study was conducted on 10 specimens to assess vascular injury induced by the Bennett retractor. Methylene blue dye angiography was performed to visualize perfusion patterns after retractor application. The MCFA perfusion disruption was documented. The effect of MCFA location and anatomical variations in this disruption was also investigated. No statistical analysis was performed due to the small sample size and descriptive nature of the study.

**Results:** Vascular disruption was observed in 9 out of 10 cadaveric specimens (90%), as demonstrated by reduced MCFA perfusion in angiographic evaluation. In 1 case without MCFA compromise, the MCFA was located along the medial border of the femoral neck. Anatomical variations in the MCFA's origin (90% profunda femoris, 10% femoral artery) and position were noted, although these variations did not influence the incidence of injury incidence.

**Conclusion:** The Bennett retractor poses a significant risk of iatrogenic MCFA injury during femoral neck fracture reduction, emphasizing the need for alternative techniques or devices to minimize vascular compromise. Further research is required to explore the clinical implications of anatomical variations and develop strategies to mitigate AVN risk.

**Keywords:** Femoral Neck Fracture, Medial Circumflex Femoral Artery, Avascular Necrosis, Iatrogenic Injury, Bennett Retractor

**Conflicts of Interest:** None declared

**Funding:** None

*\*This work has been published under CC BY-NC-SA 4.0 license.*

Copyright© Iran University of Medical Sciences

**Cite this article as:** Yeganeh A, Shahbazi A, Moghtadaei M, Hajializade M. Iatrogenic Vascular Injury During Reduction of Femoral Neck Fractures: A Cadaveric Study. *Med J Islam Repub Iran.* 2025 (25 Jun);39:86. <https://doi.org/10.47176/mjiri.39.86>

## Introduction

The femoral head receives its primary blood supply from the medial circumflex femoral artery (MCFA), with smaller contributions from the lateral circumflex femoral artery (LCFA) and the artery of the ligamentum teres (1). The MCFA is the principal source, and its branches traverse the femoral neck to deliver essential oxygen and nutrients critical for maintaining the health and viability of the femoral head and surrounding bone structures (2). Any disruption to these vessels significantly increases the risk of avascular necrosis (AVN) (3, 4). Traumatic injuries to the femoral neck, such as fractures, are strongly associated

with AVN because displaced fracture fragments can tear these vessels against sharp bone edges, overstretch them beyond their tolerance, or compress them between misaligned fragments (3, 4). Persistent vascular compromise results in ischemia, leading to bone necrosis, structural collapse, joint dysfunction, and, eventually, secondary osteoarthritis (4). In severe cases, this complication often necessitates surgical intervention, such as total hip arthroplasty (THA) (5). Therefore, minimizing the risk of AVN in patients with femoral neck fractures is a critical aspect of their management.

**Corresponding author:** Dr Mikael Hajializade, [Michaelalizadeh@gmail.com](mailto:Michaelalizadeh@gmail.com)

1. Bone and Joint Reconstruction Research Center, Department of Orthopedics, School of Medicine, Iran University of Medical Sciences, Tehran, Iran

2. School of Medicine, Ilam University of Medical Sciences, Ilam, Iran

3. Sport Medicine and Knee Research Center, Milad Hospital, Tehran, Iran

4. Bone and Joint Reconstruction Research Center, Shafa Orthopedic Hospital, Iran University of Medical Sciences, Tehran, Iran

### ↑What is “already known” in this topic:

The medial circumflex femoral artery (MCFA) supplies the femoral head, and its injury during femoral neck fracture surgery increases the risk of avascular necrosis (AVN).

### →What this article adds:

This study shows that using the Bennett retractor disrupts MCFA blood flow in 90% of cases, emphasizing the need for safer surgical techniques.

In addition to the inherent risk of AVN associated with femoral neck injuries, surgical reduction and fixation of displaced fragments may also contribute to AVN induction (6, 7). Instruments such as the Bennett retractor, commonly used to reposition the femoral neck anatomically after a displaced fracture (8) can potentially disrupt the femoral head's critical blood supply, further increasing the risk of AVN. However, there is currently a lack of studies investigating the iatrogenic incidence of AVN in femoral neck fractures.

Unlike clinical case studies, which capture real-time patient responses, cadaveric models eliminate physiological variables such as vasospasm, inflammation, or collateral circulation, enabling a clearer assessment of mechanical vascular injuries (9). Unlike clinical case studies, which capture real-time patient responses, cadaveric models eliminate physiological variables such as vasospasm, inflammation, or collateral circulation, enabling a clearer assessment of mechanical vascular injuries (10).

In this study, we conducted a cadaveric analysis to investigate the impact of the Bennett retractor on femoral head blood supply during the reduction of femoral neck fracture. Using dye angiography, we evaluated vascular disruption caused by the application of the Bennett retractor in a series of 10 cadaveric specimens.

## Methods

### Study Design and Cadaveric Specimens

This was a descriptive cadaveric experimental study conducted to evaluate the impact of the Bennett retractor on femoral head blood supply during the reduction of femoral neck fractures. A total of 10 human cadaveric specimens were utilized, ensuring the absence of prior femoral or pelvic fractures, hip surgeries, or significant vascular pathologies. The study was approved by our institute's ethics committee. All cadaveric specimens were obtained through an accredited anatomical donation program, and this study complied with institutional and legal guidelines for the use of human tissue in research.

### Experimental Setup

Each cadaveric specimen was positioned supine on a surgical table to replicate the standard clinical setup for femoral neck fracture reduction. Out of respect, no fractures were created. Instead, we simulated the fracture reduction process using a wide Bennett retractor, which was placed on the anterior cortex of the femoral neck. The retractor was applied with enough force to mimic clinical fracture reduction practices effectively.

The Bennett retractor was applied manually with a standardized force approximating typical clinical fracture reduction, ensuring consistency across all specimens. While we did not use a force gauge, the pressure exerted was maintained within a controlled range based on common surgical practice. The same technique and positioning of the retractor were used for all cadaveric specimens to maintain methodological uniformity.

### Dye Angiography

The femur was incised at the appropriate location to expose the MCFA. The proximal and distal segments of the artery were ligated to ensure controlled perfusion. To evaluate vascular disruption, a methylene blue dye solution mixed with saline was injected into the femoral artery at a pressure approximating normal physiological arterial pressure (approximately 120 mmHg). Using a C-arm, the perfusion of the femoral artery was monitored during the application of the Bennett retractor to observe changes in vascular flow and perfusion patterns.

### Outcome Measures

The primary outcome was the presence and extent of vascular disruption caused by the Bennett retractor, as assessed by areas of absent or incomplete dye perfusion in the femoral head and neck. Secondary outcomes included the anatomical locations of disrupted vessels. Two independent observers evaluated documented vascular disruptions and the anatomic location of disrupted vessels. Disagreements were resolved by consensus. Photographic documentation of each dissection was performed to support visual assessment.

## Results

### Incidence of MCFA Injury

The MCFA was found on the femoral neck in seven cadaveric specimens, along the medial border of the femoral neck in two cadaveric specimens, and on the medial side of the femoral neck in one cadaver.

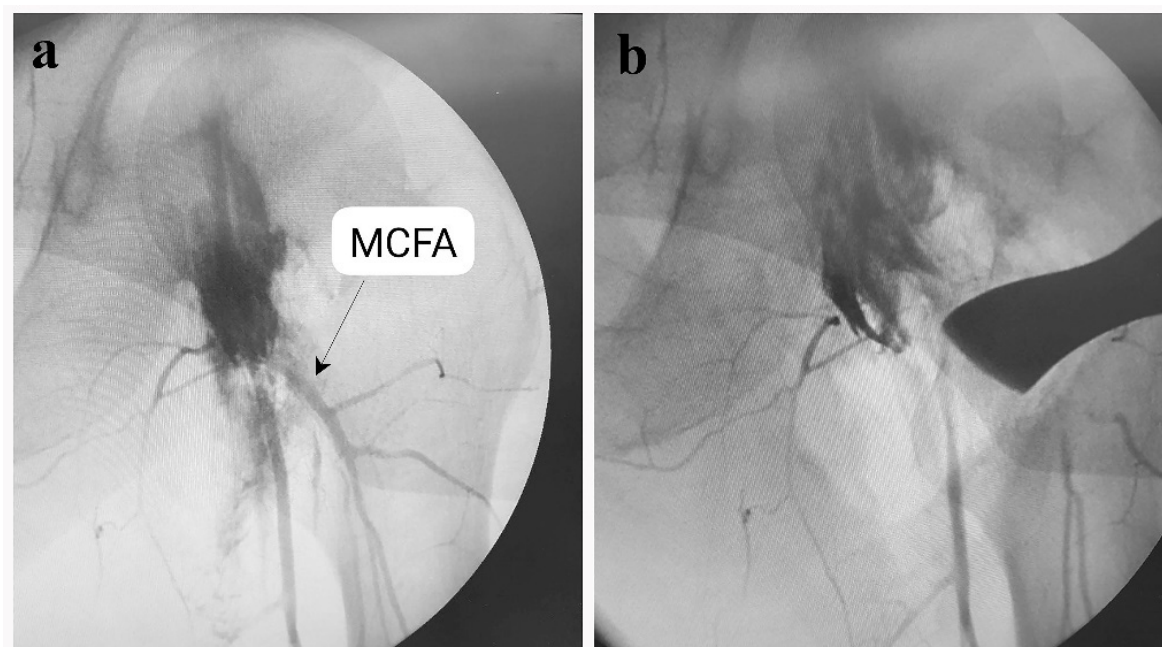
The incidence of MCFA injury was observed in 9 out of 10 cadaveric specimens during the application of the Bennett retractor. In this respect, perfusion was visibly reduced or disrupted in trials where the retractor was positioned directly on the femoral neck (Figure 1). In only 1 cadaveric specimen, the MCFA remained uninjured during the use of a wide Bennett retractor. Notably, in this cadaveric specimen, the MCFA was positioned along the medial border of the femoral neck. The presence of periarterial hematoma was noted in 1 case in which the MCFA was located on the femoral neck. The characteristic features of the MCFA and outcomes of the Bennett retractor simulation are demonstrated in Table 1.

### Anatomical Variations

In 9 cadaveric specimens, the MCFA originated from the deep femoral artery (profunda femoris), while in 1, it originated directly from the femoral artery. This anatomical variation did not appear to influence the incidence of vascular disruption during the application of the Bennett retractor, as vascular injury was observed in both origin types.

## Discussion

The MCFA, as the main artery supplying the femoral head blood, is critically important for maintaining the viability of the femoral head (11, 12). The results of this cadaveric study highlight the significant risk of vascular injury to the MCFA during the use of the Bennett retractor for the reduction of femoral neck fractures. Our findings



**Figure 1.** (a) Normal perfusion of MCFA before application of Bennett retractor; (b) disrupted perfusion of MCFA after the application of Bennett retractor.

**Table 1.** The Characteristics of the MCFA in 10 Cadavers and Outcomes of the Bennett Retractor Simulation

No	Location of MCFA	Anatomic variation	Periarterial hematoma	Vascular disruption
1	On the femoral neck	Originated from profunda femoris	NO	Yes
2	On the femoral neck	Originated from profunda femoris	Yes	Yes
3	On the femoral neck	Originated from profunda femoris	NO	Yes
4	At the medial border of the femoral neck	Originated from profunda femoris	NO	Yes
5	On the femoral neck	Originated from profunda femoris	NO	Yes
6	At the medial border of the femoral neck	Originated from profunda femoris	NO	No
7	On the femoral neck	Originated from profunda femoris	NO	Yes
8	On the medial side of the femoral neck	Originated from profunda femoris	NO	Yes
9	On the femoral neck	Originating from the femoral artery	NO	Yes
10	On the femoral neck	Originated from profunda femoris	NO	Yes

demonstrate that the placement and application of the Bennett retractor can disrupt MCFA perfusion in 90% of the cadaveric specimens evaluated.

The vulnerability of the femoral head's vascular supply to mechanical disruption during surgical intervention has been pointed out in several earlier studies. In the study by Whiteside et al, stripping the retinaculum or combining it with femoral head reaming led to complete devascularization of the femoral head in adult dogs (13). Furthermore, numerous studies have reported AVN incidence after femoral neck fracture surgeries, with dynamic hip screws (DHS) being associated with a notably high risk of AVN (14-17). The use of large implants for femoral neck fracture fixation has been associated with greater disruption of the femoral head's blood supply. Supporting this, a systematic review and meta-analysis by Xu et al reported significantly reduced vascularity in patients treated with DHS compared to those treated with cancellous screws (35% vs 11%) (18). In line with earlier studies, the present study shows that using a Bennett retractor for the reduction of femoral neck fracture can also significantly induce

femoral head AVN by disrupting MCFA perfusion. The incidence of vascular disruption observed in our study emphasizes the need for alternative surgical approaches or devices to mitigate iatrogenic injury to the femoral head blood supply. Additionally, modifications in retractor placement, such as positioning on the anterior inferior iliac spine rather than directly on the femoral neck, could help preserve vascular integrity (19). Similar technique adjustments, such as modifying graft harvesting sites, have been shown to improve cosmetic and functional outcomes in orthopedic procedures (20).

Anatomical variations are recognized as a risk factor for iatrogenic damage to the femoral head's blood supply (21-23). Understanding these variations is considered crucial in orthopedic procedures involving the hip to reduce the risk of compromising the femoral head's circulation (21, 24). Similarly, in spinal conditions, anatomical variations in spinopelvic alignment have been studied in relation to nonspecific low back pain, demonstrating the importance of individualized anatomical considerations in both spine and hip pathologies (25). The present study revealed nota-

ble anatomical variations in the MCFA's location and origin, but these variations did not significantly affect the likelihood of vascular disruption during the use of the Bennett retractor. In 1 cadaveric specimen, where the MCFA was located along the medial border of the femoral neck, vascular injury was avoided, potentially indicating that specific anatomical positions may provide relative protection against mechanical disruption. This hypothesis needs to be further elucidated in future large-scale studies. Advanced imaging techniques, such as 3D-CT, have been shown to enhance fracture classification accuracy compared to traditional radiography, suggesting that similar imaging advancements may improve vascular risk assessment in hip fracture surgeries (26).

Several limitations of this study should be acknowledged. The small number of cadaveric specimens could be regarded as the primary limitation of this study. The use of cadaveric specimens may limit the generalizability of the findings to live surgical scenarios, as factors such as vascular elasticity, blood flow dynamics, and tissue responses to injury are not replicable in cadaveric models. In addition, we used a wide Bennett retractor in all specimens. Therefore, the results may not be generalizable to other types of Bennett. Future studies incorporating live models or advanced imaging modalities could provide further insight into the dynamic aspects of vascular impairment.

### Conclusion

Using a Bennett retractor is associated with a significant risk of iatrogenic injury to the femoral head circulation, particularly MCFA perfusion. The development of alternative surgical instruments or techniques that reduce direct mechanical stress on the femoral neck arteries could play a pivotal role in minimizing the risk of iatrogenic AVN. Anatomic variations of MCFA may affect the risk of this iatrogenic injury. However, this needs to be further investigated in future studies on a larger scale.

### Authors' Contributions

A.Y.: Conceptualization, methodology, data collection, and manuscript drafting.

A.S. and M.H.: Data analysis, visualization, and manuscript editing.

M.M.: Supervision, critical revision, and final manuscript approval.

All authors have read and approved the final version of this manuscript.

### Ethical Considerations

This study was conducted in accordance with ethical guidelines for the use of cadaveric specimens in medical research. The specimens used in this study were obtained through a legally approved donation program, and informed consent for their use in research was provided by the donors before their passing.

As the study involved cadaveric specimens rather than living participants, formal consent for participation from living individuals was not required. All procedures adhered to ethical standards regarding the use of human remains, ensuring respect and confidentiality for the donors'

contributions to advancing medical knowledge.

### Acknowledgment

The authors thank the anatomical donation program for providing cadaveric specimens and appreciate the support of the surgical research department. They also acknowledge the contributions of experts in vascular anatomy.

### Conflict of Interests

The authors declare that they have no competing interests.

### References

1. Grose AW, Gardner MJ, Sussmann PS, Helfet DL, Lorch DG. The surgical anatomy of the blood supply to the femoral head: description of the anastomosis between the medial femoral circumflex and inferior gluteal arteries at the hip. *J Bone Joint Surg Br.* 2008;90(10):1298-303.
2. Liao Z, Bai Q, Ming B, Ma C, Wang Z, Gong T. Detection of vascularity of femoral head using sub-millimeter resolution steady-state magnetic resonance angiography-initial experience. *Int Orthop.* 2020;44(6):1115-21.
3. Hu Y, Yang Q, Zhang J, Peng Y, Guang Q, Li K. Methods to predict osteonecrosis of femoral head after femoral neck fracture: a systematic review of the literature. *J Orthop Surg Res.* 2023;18(1):377.
4. Konarski W, Poboży T, Śliwczynski A, Kotela I, Krakowiak J, Hordowicz M, et al. Avascular Necrosis of Femoral Head—Overview and Current State of the Art. *Int J Environ Res Public Health.* 2022;19(12).
5. Konarski W, Poboży T, Śliwczynski A, Kotela I, Krakowiak J, Hordowicz M, et al. Avascular Necrosis of Femoral Head—Overview and Current State of the Art. *International Journal of Environmental Research and Public Health* [Internet]. 2022;19(12).
6. Gore DR. Iatrogenic avascular necrosis of the hip in young children: a long-term follow-up. *J Pediatr Orthop.* 1999;19(5):635-40.
7. Pap K, Kiss S, Shisha T, Marton-Szücs G, Szöke G. The incidence of avascular necrosis of the healthy, contralateral femoral head at the end of the use of Pavlik harness in unilateral hip dysplasia. *Int Orthop.* 2006;30(5):348-51.
8. Dworkin ML. Tips of the trade #31. The use of a Charnley retractor for intertrochanteric hip fractures. *Orthop Rev.* 1990;19(12):1082-3.
9. Savastano LE, Chaudhary N, Murga-Zamalloa C, Wang M, Wang T, Thompson BG. Diagnostic and interventional optical angioscopy in ex vivo carotid arteries. *Operative Neurosurgery.* 2017;13(1):36-46.
10. Liu Y, Abbasi M, Larco JLA, Kadirvel R, Kallmes DF, Brinjikji W, et al. Preclinical testing platforms for mechanical thrombectomy in stroke: a review on phantoms, in vivo animal, and cadaveric models. *Journal of Neurointerventional Surgery.* 2021;13(9):816-22.
11. Tomaszewski KA, Henry BM, Vikse J, Roy J, Pękala PA, Svensen M, et al. The origin of the medial circumflex femoral artery: a meta-analysis and proposal of a new classification system. *Peer J.* 2016;4:e1726.
12. Chi Z, Wang S, Zhao D, Wang B. Evaluating the Blood Supply of the Femoral Head During Different Stages of Necrosis Using Digital Subtraction Angiography. *Orthopedics.* 2019;42(2):e210-e5.
13. Whiteside LA, Lange DR, Capello WR, Fraser B. The effects of surgical procedures on the blood supply to the femoral head. *J Bone Joint Surg Am.* 1983;65(8):1127-33.
14. Chen C, Yu L, Tang X, Liu MZ, Sun LZ, Liu C, et al. Dynamic hip system blade versus cannulated compression screw for the treatment of femoral neck fractures: a retrospective study. *Acta orthopaedica et traumatologica turca.* 2017;51(5):381-7.
15. Kim JW, Oh JK, Byun YS, Shon OJ, Park JH, Oh HK, et al. Incidence of Avascular Necrosis of the Femoral Head After



Intramedullary Nailing of Femoral Shaft Fractures: A Multicenter Retrospective Analysis of 542 Cases. *Medicine* (Baltimore). 2016;95(5):e2728.

16. Wang T, Sun JY, Zha GC, Jiang T, You ZJ, Yuan DJ. Analysis of risk factors for femoral head necrosis after internal fixation in femoral neck fractures. *Orthopedics*. 2014;37(12):e1117-23.

17. Fan W, Zhu L, Chen J, Guo C, Yan Z. Identifying Patients Who Will Most Benefit from Single Photon Emission Computerized Tomography and Computerized Tomography After Femoral Neck Fracture. *Med Sci Monit*. 2017;23:5669-74.

18. Xu JL, Liang ZR, Xiong BL, Zou QZ, Lin TY, Yang P, et al. Risk factors associated with osteonecrosis of femoral head after internal fixation of femoral neck fracture: a systematic review and meta-analysis. *BMC Musculoskeletal Disorders*. 2019;20:1-11.

19. Shubert D, Madoff S, Milillo R, Nandi S. Neurovascular structure proximity to acetabular retractors in total hip arthroplasty. *The Journal of Arthroplasty*. 2015;30(1):145-8.

20. Yeganeh A, Moghtadaei M, Farahini H, Amiri S, Mahmoudi M, Hamidpour Y, et al. Improving the cosmetic outcome of Salter osteotomy through the modification of iliac crest graft harvesting site: a pilot clinical study. *Current Orthopaedic Practice*. 2022;33(6):553-8.

21. Sreekanth C, Ravindranath G, Venkataramana C. A study of anomalous origin of medial circumflex femoral artery and its significance. *Journal of Clinical and Scientific Research*. 2019;8(2).

22. Gradev A, Iliev V, Jelev L. High Origin of the Medial Circumflex Femoral Artery From the External Iliac Artery in Common Trunk With the Inferior Epigastric Artery. *Cureus*. 2024;16(8):e66508.

23. Elizabeth Priyadarisini S, Chithra S. A study on the anatomical variations of the medial circumflex femoral artery. *Int J Anat Res*. 2017;5(2.3):3934-7.

24. Vuksanović-Božarić A, Abramović M, Vučković L, Golubović M, Vukčević B, Radunović M. Clinical significance of understanding lateral and medial circumflex femoral artery origin variability. *Anatomical Science International*. 2018;93(4):449-55.

25. Mirzashahi B, Hajializade M, Kordkandi SA, Farahini H, Moghtadaei M, Yeganeh A, et al. Spinopelvic parameters as risk factors of nonspecific low back Pain: a case-control study. *Medical Journal of the Islamic Republic of Iran*. 2023;37.

26. Tazeabadi SA, Noroozi SG, Salehzadeh M, Bahardoust M, Farahini H, Hajializade M, et al. Evaluation of Judet view radiographs accuracy in classification of acetabular fractures compared with three-dimensional computerized tomographic scan: a retrospective study. *BMC Musculoskelet Disord*. 2020;21(1):405.