

Intrabiliary rupture of hydatid cyst in a patient with cirrhosis

Seyed Hamid Moosavy, MD.¹, H. Froutan, MD.², M. Habibi, MD.³, N. Aghazadeh, MD.⁴,
Yasir Andrabi, MD.⁵

Department of gastroenterologist shahid mohammadi hospital bandarabbas, Iran.

Abstract

A case of 48-year-old male, hepatitis B cirrhosis, hepatic hydatid cyst, jaundice, fever, chills suffered from severe abdominal pain in the right upper quadrant. He was suffered from acute cholangitis and spontaneous bacterial peritonitis, and received intravenous antibiotics but his condition rapidly deteriorated to sepsis and severe hepatic failure. The presence of dilated Common Bile Duct (CBD) containing small cystic lesions suggesting daughter cysts on ultrasonography, which was further verified by Endoscopic Retrograde Cholangiopancreatography (ERCP), along with significant eosinophilia and positive serology test for hydatid cyst, made the diagnosis of intrabiliary rupture of hydatid cyst definite. We performed a delayed endoscopic sphincterotomy which resulted in complete resolution of the clinical picture. The patient was treated with Albendazol and Lamivudin and was referred for surgery.

Keywords

hydatid cyst, cirrhosis,

Introduction

Hydatid disease, although endemic in areas where livestock is raised in association with dogs such as the Middle east and the Mediterranean region, remains a public health issue worldwide [1]. One of the most common and very serious complications of hepatic hydatid cyst is frank intrabiliary rupture [2] occurring in 3-17% of the patients with hydatid cyst [3], causing obstructive jaundice, cholangitis or septicemia, creating difficulty with the diagnosis and treatment [4]. Diagnosis of intrabiliary rupture of hydatid cyst is challenging. Different imaging modalities and diagnostic criterias has been introduced including ultrasonography, CT-scan, MRI, MRCP and ERCP [2,5]. US may

suggest the diagnosis in most of the cases showing the criterias of dilated CBD, echogenic material in the CBD, loss of continuity of the cyst wall or a multivesicular, septated appearance of the cyst [6]. Endoscopic treatment has proven to be an alternative treatment for patients with biliary hydatid disease with a success rate of 90-100% in patients without a history of surgery [1,7]. In case of a cystobiliary fistula a surgical cure of the cyst is mandatory [2]. The most common types of surgery are: partial cystectomy with primary closure or with drainage, cystotomy with drainage, hepatic resection (atypic, segmental or lobar) and omentoplasty [8,9,10].

In this research we describe a case of frank intrabiliary rupture of hydatid cyst in a patient from an endemic area, with pre-existing chronic hepatitis B cirrhosis. Reviewing the litera-

1. **Corresponding author**, Associate Professor of HUMS Gastroenterology Dept. Shahid Mohammadi Hospital Bandarabbas, Iran. Email: seyedhamid_moosavy@yahoo.com, Cell Phone: +98917 7635854.

2. Professor of TUMS Gastroenterologist Imam Khomini Hospital
3-5. Intern of GI Ward Imam Khomini Hospital TUMS

ture, the concurrence of the two mentioned diseases has not been reported. The rapid deterioration of cholangitis to severe sepsis accompanied by significant hepatic decompensation created various clinical challenges that made the management of this case problematic. The rapid and complete resolution of clinical picture along with the improvement in biochemical tests after performing endoscopic sphincterotomy, reinforces the fact that endoscopic retrograde cholangiography with sphincterotomy has been successful as the sole and definitive means of treatment of intrabiliary ruptured hydatid cysts [1].

Case presentation

A 48-year-old male, known case of chronic hepatitis B, was admitted to the emergency room of Imam hospital for severe abdominal pain in the right upper quadrant, jaundice, fever and chills. He had an eight-year history of vague intermittent pain in the upper abdomen for which, he had been evaluated in his hometown, and diagnosed with hepatic hydatid cyst but refused the prescribed treatment of Albendazol and surgery. He was never evaluated or treated for hepatitis B. He was otherwise asymptomatic, until twenty days before admission, when he noticed dark discoloration of urine and pale stool leading to overt jaundice within 10 days, followed by a constant pain in the right upper quadrant, mild abdominal distension, fever and chills for two days prior to admission.

The social history revealed him as a 48-year-old married farmer, father of three, who was born and lived in the city of Gonbad, Golestan province. He consumed alcohol occasionally, did not smoke and denied use of any medications or illicit drugs. His family history was unremarkable.

Investigation

Physical Examination at admission showed a fully conscious middle-aged male with an oral

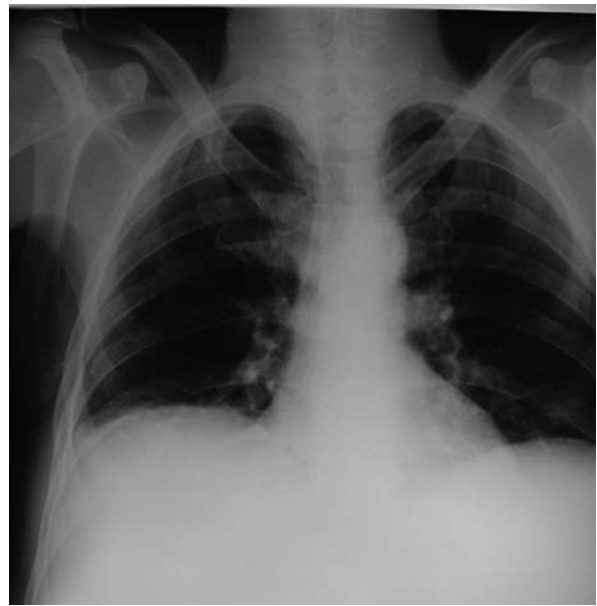

Fig.1. CXR no evidence of lung cyst

temperature of 38.9 ° C, a pulse rate of 120 per minute, and blood pressure of 110/70 mmHg. The conjunctiva appeared pale and the face and trunk were icteric. Multiple spider hemangiomas of varying sizes were found on the upper chest and back. The abdomen was mildly distended with moderate tenderness on palpation of the right upper quadrant. The spleen was palpable about 4 centimeters below the left costal margin. The liver span measured about 7 centimeters on percussion. Other physical examinations were normal.

Laboratory findings indicated anemia (Hb: 10.5, MCV:87), marked leukocytosis (WBC: 20300/mm³, 75% PMNs) and thrombocytopenia (68000). Liver function tests were abnormal with elevated alkaline phosphatase (545), mildly elevated Aspartate and Alanine transaminase (49.3 and 51 respectively), conjugated hyperbilirubinemia (total bilirubin: 13.7 and direct bilirubin: 8.19), prolonged prothrombin time (19, INR: 1.9) and hypoalbuminemia (2.7). Ultrasonography performed in the emergency room showed decreased liver size, with dilated CBD (14mm). The gallbladder had normal wall

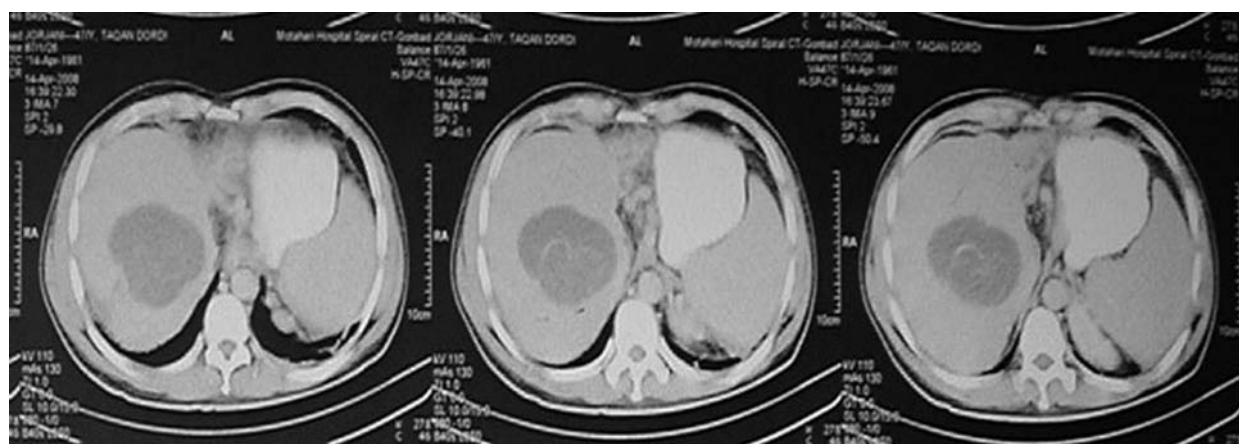


Fig. 2. Cyst in the liver with daughter cyst.

thickness and contained no stones. A cystic mass with mixed echogenicity was noted in the right liver lobe, measured 73.58mm which was highly suggestive of hydatid cyst. Spleen had a diameter of 20 cm. Minimal ascites fluid was present in the pelvis. The ascites fluid was drained and the result of laboratory examinations was indicative of spontaneous bacterial peritonitis with white blood cell count of 700 (50% PMN), total protein of 3 gr/dl, negative smear and culture for bacterial infection.

Differential diagnosis

HepatoCellular Carcinoma, because the patient was cirrhotic but AFP was normal and cystic mass.

Treatment

Due to acute suppurative cholangitis and spontaneous bacterial peritonitis, intravenously antibiotic regimen of Ceftriaxon and Metronidazole was administered. 48-hours after initiation of treatment, the clinical picture and test results deteriorated toward overt sepsis and decompensated cirrhosis. The patient was slightly lethargic, remained febrile (oral temperature: 39.2 °C), and developed massive tense ascites leading to abnormal breathing with generalized abdominal tenderness. Biochemical tests showed leukocytosis (WBC: 36800, PMN:

80%) and eosinophilia(15%), total and direct levels of bilirubin reached 30.6 and 12.5 respectively. The patient was then transferred to the gastroenterology department of Imam hospital. The ultrasonography was repeated which revealed the following data. Liver appeared smaller than normal, with increased echogenicity and nodular surface. A cystic lesion with an echogenic center, containing multiple small cysts was noted in the right liver lobe, measuring 62.58 mms, which was strongly suggestive of hydatid cyst. The Common bile duct (CBD) was dilated (14mm), and multiple echogenic centers without posterior shadow were noted in the common bile duct suggestive of biliary

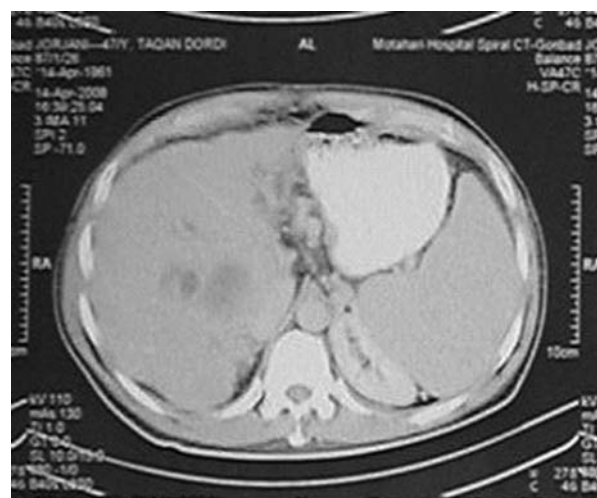

Fig.3. Reaction around the cyst suggested rupture.

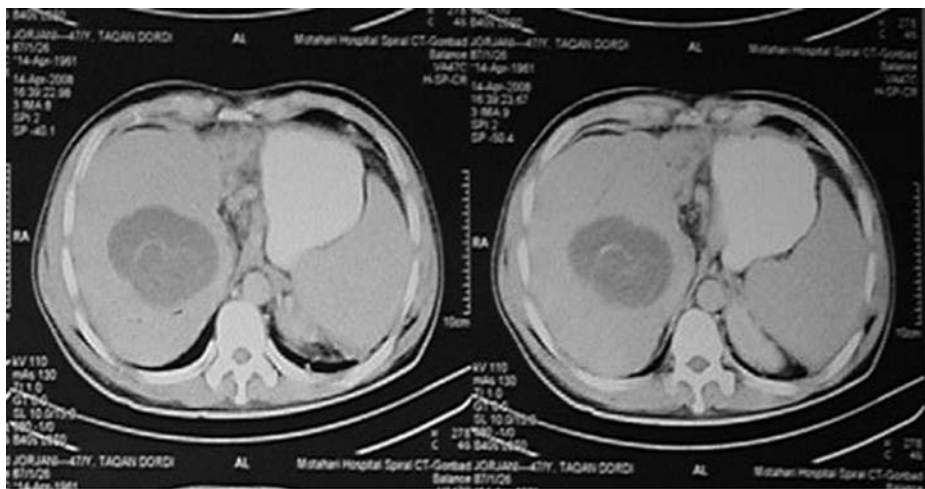


Fig. 4. Cyst in the liver with daughter cyst.

sludge. The spleen was measured 187 mm, and abundant ascites fluid presented in the pelvis and abdomen. The ascites fluid was drained therapeutically and the result of ascites fluid analysis persistently met the criteria of peritonitis (WBC count: 1200, PMN:80%) with negative bacterial smear and culture. Therefore, in the absence of clinical and laboratory improvement, the intravenous antibiotic regimen was changed to Imipenem and Vancomycin. An emergent endoscopic retrograde cholangiopancreatography (ERCP) was scheduled and then cancelled due to prolonged prothrombin time (INR: 2.9). We performed endoscopic ultrasonography (EUS), while the patient received fresh frozen plasma to correct the coagulation status. The EUS results showed a

dilated CBD (13mm), containing sludge debris and multiple cystic images without acoustic shadow, which may represent daughter cysts. In addition, the serology test for hydatid cyst antibody (IgG) was positive. These findings raised a very high suspicion of frank intrabiliary rupture of hydatid cyst, which was ignored. When INR reached 1.4, ERCP and sphincterotomy were done and the findings showed multiple irregularly-shaped filling defects in the CBD and a round cystic lesion which was may communicated with the biliary system, with mild distal stricture and dilatation of intrahepatic ducts. The comprehensive information provided by ERCP, presented conclusive evidence of the presence of daughter cysts in the CBD, demonstrated the cystobiliary fistula and above all,

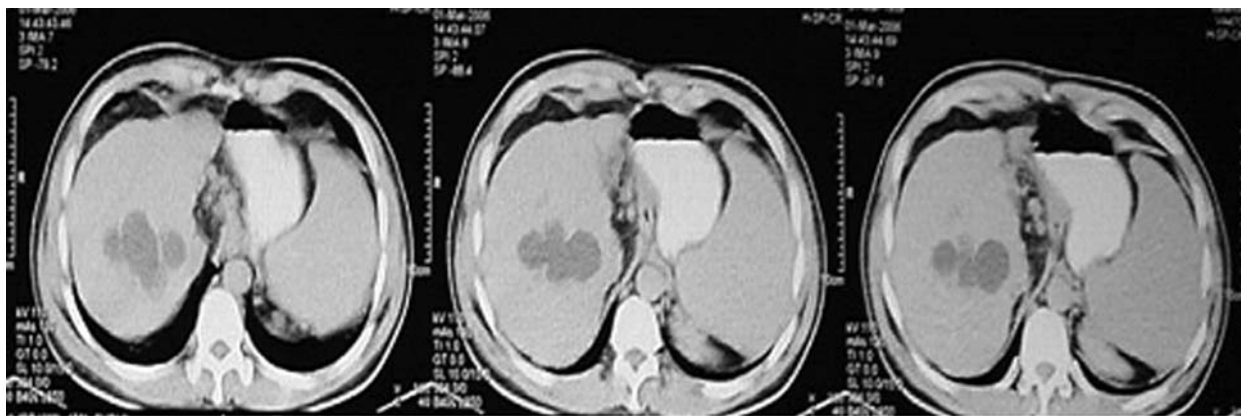

Fig.5. Cyst in liver with reaction around the cyst suggested rupture.

served as an excellent therapeutic modality. Within 24 hours after ERCP, the patient became afebrile and his general condition improved significantly. Due to a hepatitis B viral load of more than 100 and decompensated cirrhosis, we started Lamivudin treatment. A surgery consult was done and the patient chose to have the surgery in a hospital in his hometown. Therefore with the existing Albendazol treatment, the patient was referred to a surgery centre and then discharged him based on his personal consent.

Discussion

Although hydatidosis is a benign disease, it can produce serious complications as portal hypertension in countries where the disease is endemic. Portal hypertension has been reported secondary to obstruction of inferior vena cava and hepatic outflow tract or extrahepatic presinusoidal portal hypertension caused by extrinsic compression of the liver by an hydatid cyst. Hydatosis in the previously cirrhotic patients is rare because liver parenchyma is fibrotic and growing cyst within the liver is difficult although if infection occurred may be severe due to several factors including: impaired humoral and cellular immune responses to the organism, nutritional deficiency and decompensation of cirrhosis [3].

In this case intrabiliary rupture of large hydatid cyst in cirrhotic liver was occurred which is a rare complication. The endoscopic sphincterotomy is the procedure of choice that resolves biliary obstruction and cholangitis. The cholangitis treated by liver transplantation might produce a good long-term outcome since the patient was child c but yet presented a technical challenge related to mortality and risk of procedure. Other challenge in prescribing albendazole for cirrhotic patients with hydatosis elevated aminotransferase levels and leucopenia, may required discontinuing albendazole.

In review of published cases no case of hydatid cyst in previously cirrhotic patient was reported

Learning points

"Frank intrabiliary rupture of hydatid cyst is a relatively rare, but very serious cause of obstructive jaundice and/or cholangitis and must be among differential diagnosis especially in endemic areas or in proper clinical settings.

"The diagnosis of intrabiliary rupture of hydatid cyst, may be challenging. Ultrasonography may suggest the diagnosis of a frank intrabiliary rupture in many of the cases. As evidenced in our patient, the dilatation of the biliary tree and the presence of small cystic images in CBD which may represented daughter cyst, a very specific sign of rupture, but not sensitive. Nonshadowing material in the CBD is more often seen and most probably with the expression of hydatid sand; however is not very specific being present in case of biliary sludge, blood clot or inflammatory sludge. The CT-scan, MRI, MRCP, EUS and ERCP provide more comprehensive information for patients with biliary hydatid cyst.

"Endoscopic sphincterotomy has proven to be an excellent alternative treatment for patients with biliary hydatid cyst, especially if risk of surgery is high.

"The optimal treatment, especially in the presence of a cystobiliary fistula, is surgery.

References

1. Manouras A, Genetzakis M, Antonakis P.T, et al. Endoscopic management of a relapsing hepatic hydatid cyst with intrabiliary rupture: A case report and review of the literature. *Canadian Journal of Gastroenterology* 2007; 21 (4):249-53.
2. Sparchez Z, Osian G, Onica A, et al. Ruptured hydatid cyst of the liver with biliary obstruction: presentation of a case and review of the literature. *Romanian Journal of Gastroenterology* 2004;13(3):245-50.
3. Atli m, Kama NA, Yusek YN, et al. Intrabiliary rupture of a hepatic hydatid cyst: associated clinical factors and proper management. *Archive of Surgery*

2001;136:1249-55.

4. Hamamci EO, Besim h, Sonisik M, et al. Occult Intrabiliary Rupture of Hydatid Cysts in the Liver. *World Journal of Surgery* 2005;29:224-6.

5. Lewall DB, McCorkell SJ. Rupture of echinococcal cysts: diagnosis, classification and clinical implications. *American Journal of Radiology* 1986;146:391-4.

6. Marti-Bonmati L, Menor Serrano F. Complications of hepatic hydatid cysts: ultrasound, computed tomography and magnetic resonance diagnosis. *Gastrointestinal Radiology* 1990;15:119-25.

7. Bilsel Y, Bulut T, Yamaner S. ERCP in the diagnosis and management of complications after surgery for hepatic echinococcosis. *Gastrointestinal Endoscopy* 2003;57(2):210-13.

8. Bedirli A, Sakrak O, Sozeur EM, et al. Surgical management of spontaneous intrabiliary rupture of hydatid liver cysts. *Surgery Today* 2002;32:594-7.

9. Chautems R, Bu?hler LH, Gold B, et al. Surgical management and long-term outcome of complicated liver hydatid cysts caused by *Echinococcus granulosus* 2005;137:312-316.

10. Oazaslan E, Bayraktar Y. Endoscopic therapy in the management of hepatobiliary hydatid disease. *Journal of Clinical Gastroenterology* 2002;35(2):160-74.