


## Long Segment Midaortic Stenosis in Williams Syndrome: Report of a Very Rare Presentation

Hamzeh Al-Momani<sup>1</sup>, Yazan Al-Mashakbeh<sup>2\*</sup> , Majd Zidan<sup>2</sup>, Yasmeen Jum'ah<sup>2</sup>

Received: 10 Apr 2025

Published: 15 Jul 2025

### Abstract

**Background:** Midaortic syndrome (MAS) is a rare medical condition characterized by thoracoabdominal aortic stenosis or occlusion, resulting in decreased blood supply to the organs and tissues in the lower half of the body. We report a very rare presentation of MAS in a 14-year-old female that was found to have severe stenosis extending from the descending aorta to the level above the bifurcation.

**Case Presentation:** A 14-year-old female with Williams syndrome presented with complaints of headache and chest discomfort on mild exertion. Examination revealed dysmorphic features of William syndrome and different blood pressure between the upper and lower limbs with weak femoral pulses. An ECG showed sinus rhythm with left ventricular hypertrophy. 2-D color flow Doppler echocardiogram revealed mild central mitral regurgitation, minimal aortic regurgitation, and concentric left ventricular hypertrophy. CT angiogram revealed a hypoplastic descending thoracic aorta, an aberrant right subclavian artery, and an arterio-venous fistula communicating between the bronchial artery and the left brachiocephalic vein. The patient was started on two antihypertensive medications, and vascular surgery was consulted for possible future intervention.

**Conclusion:** Management of midaortic syndrome necessitates a holistic approach customized to the specific patient's requirements and risk assessment. Early detection and intervention are critical in averting severe complications and enhancing long-term prognoses. Continuous investigation and advancement of novel therapies may present supplementary possibilities for addressing this complex and rare ailment.

**Keywords:** Midaortic Coarctation, Williams Syndrome, Endovascular Repair

**Conflicts of Interest:** None declared

**Funding:** None

*\*This work has been published under CC BY-NC-SA 4.0 license.*

Copyright© Iran University of Medical Sciences

**Cite this article as:** Al-Momani H, Al-Mashakbeh Y, Zidan M, Jum'ah Y. Long Segment Midaortic Stenosis in Williams Syndrome: Report of a Very Rare Presentation. *Med J Islam Repub Iran.* 2025 (15 Jul);39:94. <https://doi.org/10.47176/mjiri.39.94>

### Introduction

Midaortic syndrome (MAS) is a rare condition characterized by narrowing or blockage of the thoracic and/or abdominal aorta, leading to decreased blood flow to the organs and tissues of the lower body (1). Although it was first described by Schlessinger in 1835, Sen et al. first coined the term “Midaortic Syndrome” in 1963 (1). The prevalence of this condition is between 0.5% to 2% among all aortic coarctations (2).

It can present in both children and adults and can be associated with a range of underlying conditions. Aside from idiopathic etiologies, which account for the majority of cases (61%), other causes of MAS include Takayasu arteritis, Fibromuscular Dysplasia, and Williams' Syndrome (3, 4).

Williams syndrome is a rare genetic disorder caused by a deletion of the elastin gene on the long arm of chromo-

**Corresponding author:** Dr Yazan Al-Mashakbeh, [almashakbeh.yazan@gmail.com](mailto:almashakbeh.yazan@gmail.com)

<sup>1</sup> Department of Pediatrics, Faculty of Medicine, The Hashemite University, Zarqa 13133, Jordan

<sup>2</sup> Department of Pediatrics, New Zarqa Governmental Hospital, Zarqa, Jordan

#### ↑What is “already known” in this topic:

Midaortic syndrome is a rare condition of narrowing of certain parts of the aorta. Since it's rare, the treatment is often complex and no guidelines are obvious to treat this condition.

#### →What this article adds:

this article reports this rare condition to help establish a clear guidelines in regards to diagnosing and treating this condition.

some 7 (5, 6). This disorder affects many parts of the body, including the cardiovascular system, the musculo-skeletal system, and the nervous system. Individuals with Williams syndrome often exhibit distinctive facial features, including a small, upturned nose, a wide mouth with full lips, and a small chin (6).

Cardiovascular issues are a significant concern for individuals with Williams syndrome. Approximately 75% of individuals with this condition have some form of cardiovascular abnormalities, including supralvalvular aortic stenosis (SVAS) (7).

According to a study published in the International Heart Journal in 2021, the incidence of midaortic syndrome in individuals with Williams syndrome is estimated to be approximately 2 % (4).

We report a case of a 14-year-old female with Williams' syndrome, who was found to have a long-segment midaortic syndrome extending from the descending thoracic aorta to the level above the common iliac artery bifurcation.

### Case Presentation

A 14-year-old female known to have William syndrome, that was confirmed by genetic testing at infancy, presented with complaints of headache and chest discomfort with exertion; the patient reported some sort of intermittent claudication upon running and jogging only, she didn't complain of palpitation, syncope, or shortness of

breath, and she hadn't taken any medications. On examination, she was conscious, alert, and comfortable. Dysmorphic features of William syndrome, weight, height:, , vital signs showed different Blood pressure between upper and lower limbs with BP of 140/95 in the upper limbs and of 120/80 mmHg in the lower limbs with weak femoral pulses, heart rate was 90/min, JVP not elevated, heart auscultation showed normal s1 and s2 with a grade II ejection systolic murmur at the left mid-sternal border, no heave, and no added sounds, lung auscultation was normal, no abdominal bruit was auscultated, no organomegaly, and there was no lower limb edema.

An ECG was done and showed sinus rhythm with left ventricular hypertrophy.

2-D color flow Doppler echocardiogram showed the following findings: Situs solitus, levocardia, normal inferior vena cava diameter and collapsibility with respiration, pulsatile abdominal aorta, normal systemic and pulmonary venous flow, normal atrioventricular and ventriculoarterial concordance, normal tri-leaflet aortic valve, mild central mitral regurgitation, minimal aortic regurgitation with central jet, mild tricuspid regurgitation from which estimated pulmonary pressure is normal, normal volumes of right and left atriums, normal interatrial septum and interventricular septum, concentric left ventricular hypertrophy, interventricular septum at end diastole: 10-12 mm, pw diameter at end diastole:10-12 mm, Normal biventric-

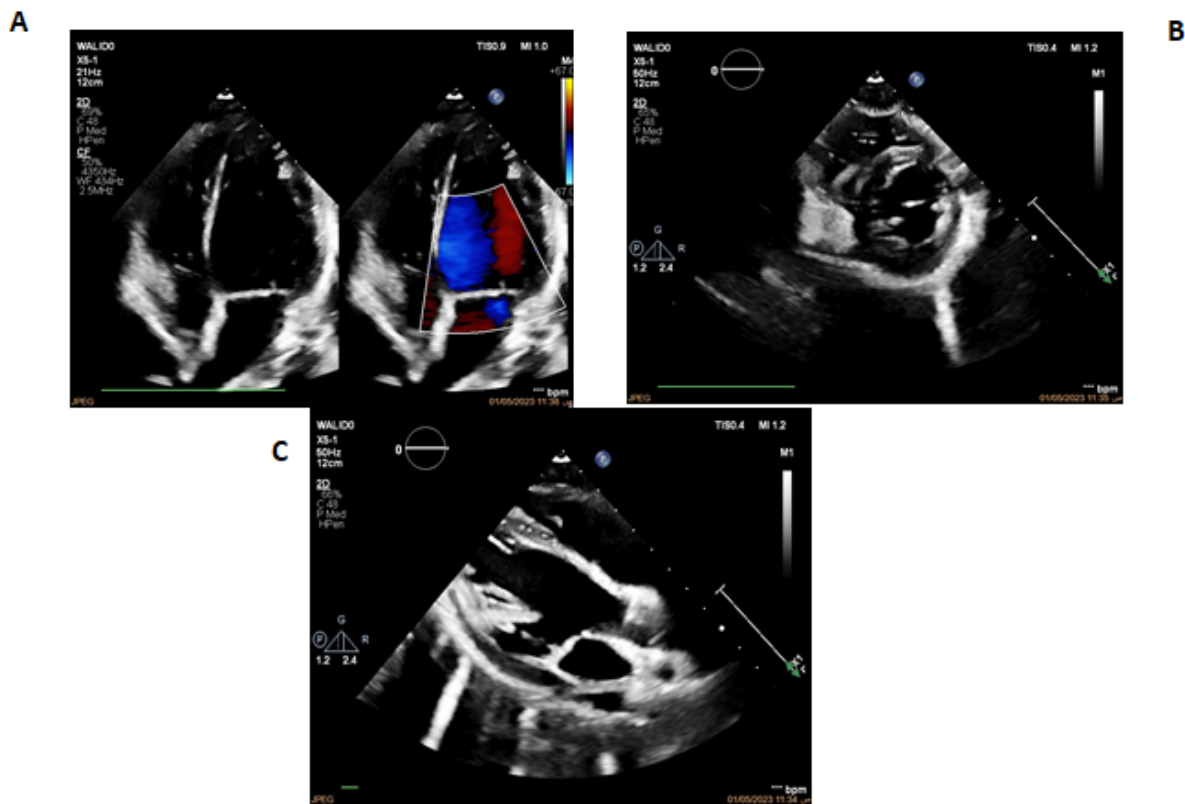


Figure 1. A: a 4-chamber 2-D echocardiogram with color Doppler view showed mild mitral regurgitation. B+C: short axis and long axis 2-D echocardiogram views showed mild left ventricular hypertrophy.

ular systolic function, normal left ventricular outflow tract, normal right ventricular outflow tract, and a left-sided aortic arch with an isthmic gradient of approximately 7 mmHg and a caliber of 8 mm. The abdominal flow was weakly pulsatile, with diastolic run-off and calibers ranging from 4 to 7 mm in the entire abdominal aorta, normal coronary artery origin, no pericardial effusion, and no patent ductus arteriosus (Figures 1 and 2).

A CT angiogram of the ascending aorta, aortic arch, and descending aorta revealed that the ascending aorta is normal in caliber, the descending thoracic aorta from the isthmic segment through the abdominal aorta is diffusely hypoplastic with a diameter of 6 mm, the transfer aortic arch measures 14 mm, there is an aberrant right subclavian artery that passes posterior to the esophagus, and there is an arterio-venous fistula communicating between the bronchial artery and the left brachiocephalic vein (Figure 3).

Laboratory tests showed a normal complete blood count, normal thyroid function test, normal lipid profile, normal kidney function test, and electrolytes.

She started on two antihypertensive medications: bisoprolol (2.5 mg twice daily) and amlodipine (5 mg twice daily), with a partially controlled systemic blood pressure that decreased to 125-130/85 mmHg in the upper limbs. She was asymptomatic for a few months before she started

to have gingival hypertrophy, so amlodipine was replaced with candesartan (4 mg twice daily). Now she is asymptomatic with almost controlled systemic blood pressure (120/85 mmHg in the upper limbs).

Vascular surgery was consulted about the case and explained that the case was very complex and needed, at this moment, medical therapy with a possible surgical plan in the future.

## Discussion

Midaortic syndrome is a rare condition that affects the aorta, causing narrowing or obstruction of the vessel. This can lead to a decrease in blood flow to the organs and tissues supplied by the aorta, such as the kidneys, liver, and intestines (1, 2).

Previous research has indicated the link between MAS and Williams' syndrome is that the absence of elastin in the walls of blood vessels can lead to the narrowing of the vessel lumen and arterial stenosis due to vascular smooth muscle hyperplasia. Nonetheless, recent studies have proposed that the deficiency of elastin leads to abnormal circumferential expansion of arteries, rather than an increase in the number of vascular smooth muscle cells (9, 10).

The Diagnosis of MAS can be challenging, and sometimes, can be misdiagnosed as Takayasu Arteritis (4, 11). Diagnostic workup for MAS usually involves Computed

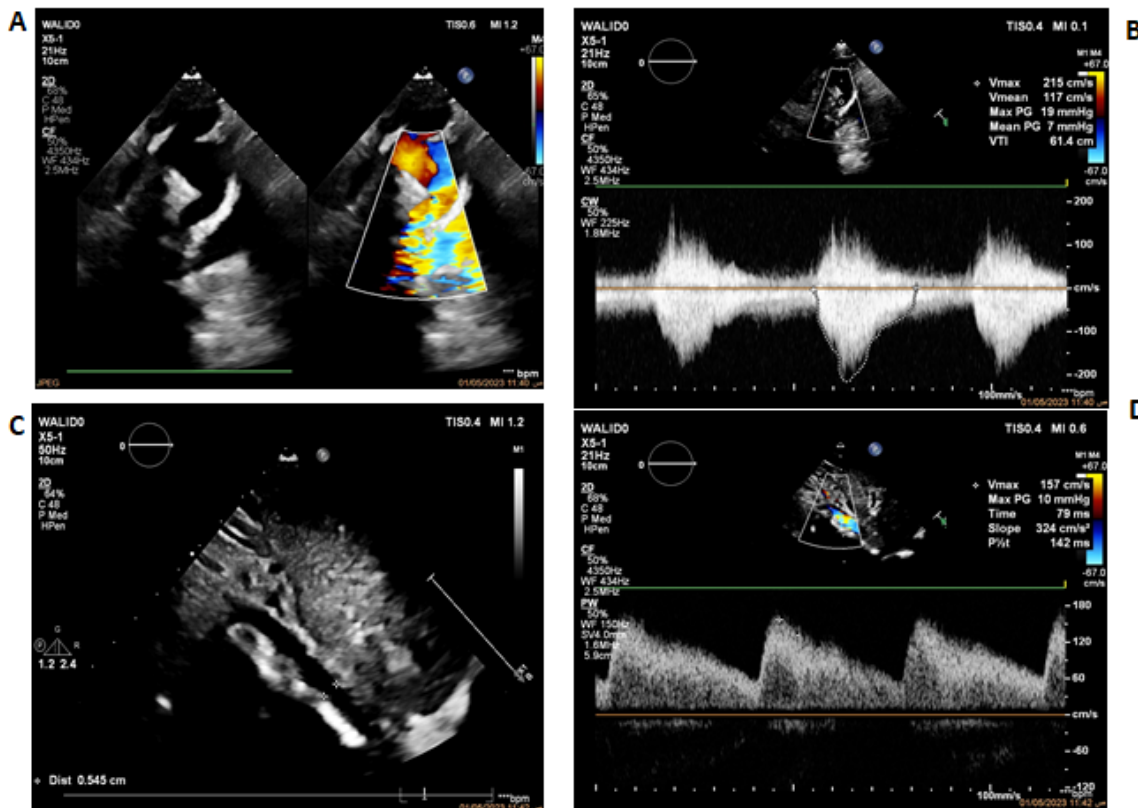


Figure 2. A+B: suprasternal aortic arch 2-D echocardiogram with color flow Doppler: a left-sided aortic arch with an isthmic gradient of approximately 7 mmHg and a caliber of 8 mm., C+D: abdominal 2-D echocardiogram: weakly pulsatile abdominal aorta with diastolic run-off and calibers ranging from 4 to 7 mm in the entire abdominal aorta.

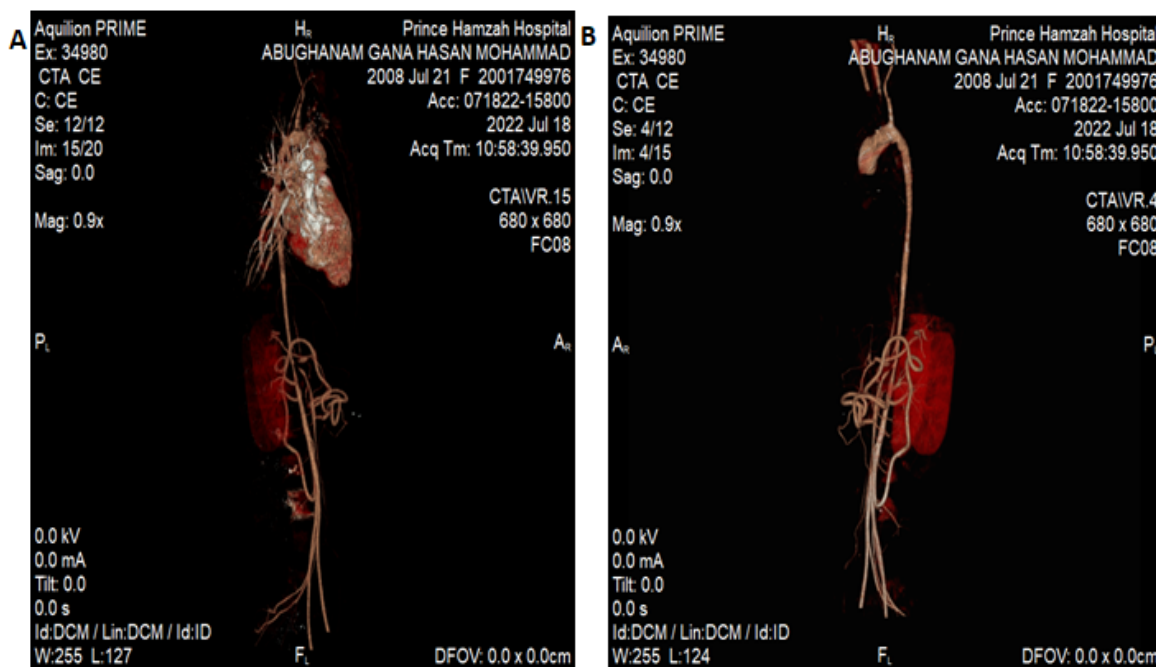


Figure 3. CT angiogram of the aorta, A+B, showed that the descending thoracic aorta from the isthmic segment through the abdominal aorta is diffusely hypoplastic with a diameter of 6 mm.

Tomography (CT) Angiography and Magnetic Resonance Imaging (MRI) (8). If results were inconclusive,  $^{18}\text{F}$ -fluoro-2-deoxy-d-glucose (FDG) positron emission tomography combined with anatomical computed tomography angiography (PET/CTA) imaging can be used to confirm MAS (11).

The unique finding in our case that was detected by CT angiography is a hypoplastic aorta that extends from the descending thoracic and throughout the whole abdominal aorta to end just above the bifurcation. This was never reported in the literature, and it signifies the severity of our case.

Management of midaortic syndrome is challenging and requires a multidisciplinary approach involving specialists in vascular surgery, interventional radiology, cardiology, and nephrology (8).

In mild cases of midaortic syndrome, conservative management with blood pressure control and regular monitoring of renal function may be sufficient. However, in more severe cases with significant stenosis or occlusion of the aorta, surgical or endovascular intervention may be necessary to restore blood flow and prevent organ damage (12, 13).

In recent years, novel therapies such as renin-angiotensin-aldosterone system (RAAS) inhibitors and endothelin receptor antagonists (ERAs) are being investigated for the treatment of midaortic syndrome. These medications have been shown to improve blood pressure control and renal function in some cases, but their long-term efficacy and safety in midaortic syndrome are not yet established (14, 15).

Surgical options for midaortic syndrome include bypass grafting, aortic replacement, or a combination of both.

Endovascular techniques such as balloon angioplasty or stent placement may also be used in selected cases. However, these interventions carry a risk of complications such as bleeding, infection, or thrombosis, and require careful patient selection and follow-up (13, 16).

Our patient commenced on anti-hypertensive medications, bisoprolol and candesartan, with almost controlled systemic blood pressure that decreased to 120/85 mmHg in the upper limbs. She is currently stable, and her renal function test is within normal limits.

The case was deemed highly intricate by the vascular surgery team who were consulted, and they recommended medical treatment at present, with the potential for a surgical strategy in the future.

### Conclusion

In summary, management of midaortic syndrome requires a comprehensive approach tailored to the individual patient's needs and risk profile. Early diagnosis and intervention are crucial to prevent serious complications and improve long-term outcomes. Ongoing research and development of new therapies may offer additional options for the management of this rare but challenging condition.

### Authors' Contributions

Hamzeh Al-Momani: Study design, data collection and analysis, drafting, reviewing, and writing the final version of the paper; Yazan Al-Mashakbeh: data collection and analysis, drafting, reviewing, and writing the final version of the paper; Majd Zidan: data collection and analysis, drafting, reviewing, and writing the final version of the paper; and Yasmeen Jum'ah: data collection and analysis,

drafting, reviewing, and writing the final version of the paper.

Kimmenade. RRJ. *Eur J Vasc Endovasc Surg* 2023;65:120-30.

### Ethical Considerations

Not applicable.

### Acknowledgment

Not applicable.

### Conflict of Interests

The authors declare that they have no competing interests.

### References

1. Forman N, Sinsky J, Shalabi A. A Review of Middle Aortic Syndromes in Pediatric Patients. *J Cardiothorac Vasc Anesth*. 2020 Apr;34(4):1042-1050.
2. Cortenbach KRG, Yosofi B, Rodwell L, Meek J, Patel R, Prakash SK, Riksen NP, Jenniskens SFM, Dirven M, DeRuiter MC, van Kimmenade RRJ. Editor's Choice - Therapeutic Options and Outcomes in Midaortic Syndrome: A Systematic Review and Meta-analysis. *Eur J Vasc Endovasc Surg*. 2023 Jan;65(1):120-130.
3. Phan TN, Luong LH, Nguyen TH, Nguyen HD, Nguyen TT. ELN missense variant in patient with mid-aortic syndrome case report. *BMC Cardiovasc Disord*. 2022 Dec 3;22(1):520.
4. Byoun JT, Cho JY, Yun KH, Rhee SJ, Yu ST, Oh SJ. Mid-Aortic Syndrome in Williams-Beuren Syndrome with an Atypical Small-Sized Deletion of Chromosome 7q11.23 Misdiagnosed as Takayasu Arteritis. *Int Heart J*. 2021 Jan 30;62(1):207-210.
5. Lowery MC, Morris CA, Ewart A, Brothman LJ, Zhu XL, Leonard CO, Carey JC, Keating M, Brothman AR. Strong correlation of elastin deletions, detected by FISH, with Williams syndrome: evaluation of 235 patients. *Am J Hum Genet*. 1995 Jul;57(1):49-53.
6. Pober BR. Williams-Beuren syndrome. *New England Journal of Medicine*. 2010;362(3):239-52.
7. Morris CA, Mervis CB. Williams syndrome. In: Adam MP, Ardinger HH, Pagon RA, et al., editors. *GeneReviews*. University of Washington, Seattle; 1993. Available from: <https://www.ncbi.nlm.nih.gov/books/NBK1249/>
8. Durgin JM, Slatnick BL, Vakili K, Kim HB, Cuenca AG. Midaortic syndrome and renovascular hypertension. *Semin Pediatr Surg*. 2021 Dec;30(6):151124.
9. Twite MD, Stenquist S, Ing RJ. Williams syndrome. *Pediatr Anesth*. 2019;29:483-490.
10. Jiao Y, Li G, Korneva A, et al. Deficient circumferential growth is the primary determinant of aortic obstruction attributable to partial elastin deficiency. *Arterioscler Thromb Vasc Biol*. 2017;37:930-941.
11. Opoka-Winiarska, V., Tomaszek, M.B., Sobiesiak, A. et al. The importance of FDG PET/CT in the diagnostic process of the middle aortic syndrome in a 15-year-old boy patient with suspected systemic vasculitis and final diagnosis of Williams-Beuren syndrome. *Rheumatol Int*. 2020;40:1309-1316.
12. Patel RS, Nguyen S, Lee MT, Price MD, Krause H, Truong VTT, Sandhu HK, Charlton-Ouw KM, LeMaire SA, Coselli JS, Prakash SK. Clinical Characteristics and Long-Term Outcomes of Midaortic Syndrome. *Ann Vasc Surg*. 2020 Jul;66:318-325.
13. Vakili K, Fullington NM, Turner CG, Cauley RP, Potanos KM, Lee S, Ferguson M, Lock JE, Kim HB. Aorto-mesenteric and renal allograft transplant: a novel treatment for midaortic syndrome. *Am J Transplant*. 2013 Apr;13(4):1088-1092.
14. Burnier M. Update on Endothelin Receptor Antagonists in Hypertension. *Curr Hypertens Rep*. 2018 May 19;20(6):51.
15. Ames MK, Atkins CE, Pitt B. The renin-angiotensin-aldosterone system and its suppression. *J Vet Intern Med*. 2019 Mar;33(2):363-382.
16. Cortenbach KRG, Yosofi B, Rodwell L, Meek J, Patel R, Prakash SK, Riksen NP, Jenniskens SFM, Dirven M, DeRuiter MC, van