

## DIFFERENTIATION BETWEEN PROSTATIC CARCINOMA AND BENIGN PROSTATIC HYPERPLASIA BY AgNOR STAINING

SIMIN TORABI-NEZHAD, M.D., AND PARVIN KHERADMAND,  
M.D.

*From the Department of Pathology, Shiraz Medical School, Shiraz University of Medical Sciences,  
Shiraz, I.R. Iran.*

### ABSTRACT

Thirty cases of benign prostatic hyperplasia and 30 cases of prostatic adenocarcinoma were selected and stained by AgNOR (argyrophilic staining of the nucleolar organizer region) method.

Specimens were obtained by either prostatectomy (open/TUR) or needle biopsy of the prostate.

In this study, the sections of prostatic adenocarcinoma were reviewed. 6 cases were diagnosed as well-differentiated, 12 cases as moderately-differentiated and 12 cases as poorly differentiated adenocarcinoma.

The method of AgNOR staining was applied to see if it would be useful in the distinction between benign and malignant lesions. In benign lesions, the mean number of AgNOR count was 2.5 and in malignant specimens was 7.4. Prostatic hyperplasia (benign) specimens showed two or three well-defined NORs, but in malignant tumors, there were many irregular small NORs. AgNOR stain can be used for differentiation between benign and malignant lesions of the prostate, but this stain should not be used as a reliable index for grading prostatic adenocarcinoma, because overlapping was seen in some cases.

*MJIRI, Vol. 12, No. 4, 333-338, 1999*

**Keywords:** AgNOR staining, Prostatic carcinoma, Benign prostatic hyperplasia.

### INTRODUCTION

Nucleolar organizer regions (NORs) are loops of DNA that are responsible for ribosomal RNA (rRNA) transcription. They are located in the nucleoli of cells and on the short arms of chromosomes 13, 14, 15, 21 and 22 in

association with proteins.<sup>8,20</sup> As rRNA molecules are the main sites of protein synthesis, it has been suggested that the numbers of NORs may reflect nuclear and cellular activity.<sup>8,12,20</sup>

NORs are argyrophilic because their associated acidic proteins (i.e., C23, B23 and possibly RNA polymerase 1) contain abundant sulfhydryl and carboxy groups which precipitate silver ions.<sup>8</sup> So NORs can be visualized as intranuclear black dots by histochemical staining with colloid silver solution.<sup>20</sup> For the first time, Ploton et al. modified the AgNOR technique for paraffin-embedded formalin-fixed tissues.<sup>8</sup> Then Crocher and his colleagues reported application of the AgNOR technique for diagnostic

#### Correspondence:

Dr. Torabi-Nezhad,  
Department of Pathology,  
Shiraz Medical School,  
Shiraz University of Medical Sciences,  
Shiraz, I.R. Iran.

Table I. Mean and range of AgNOR count in benign and malignant lesions of the prostate.

Number of Specimens	Diagnosis	Mean AgNOR Count	Range of AgNOR Count
30	BPH	2.5	2-3
6	Well-differentiated adenocarcinoma	6.5	5.2-7.3
12	Moderately-differentiated adenocarcinoma	7.6	6.4-9.7
12	Poorly-differentiated adenocarcinoma	9.1	7.4-10.9

tumor pathology.<sup>3,8</sup> This method has been used for many types of lesions including breast,<sup>20</sup> colon,<sup>22</sup> cervix,<sup>4</sup> endometrium,<sup>3</sup> melanocytic skin lesions,<sup>12</sup> non-Hodgkin's lymphoma,<sup>15</sup> acute leukemia<sup>16</sup> and chordoma.<sup>19</sup>

In some studies, NOR was found to be diagnostically useful, but the role of NOR in estimating prognosis is controversial.<sup>1,6,8,10</sup>

#### MATERIALS AND METHODS

Sixty prostatectomy (open/TUR) and needle biopsy specimens, including 30 benign prostatic hyperplasia and 30 prostatic adenocarcinoma specimens from the Pathology Department of Faghihi Hospital, affiliated to Shiraz University of Medical Sciences were recovered. The slides were reviewed, and 6 cases of well-differentiated, 12 cases of moderately-differentiated and 12 cases of poorly-differentiated adenocarcinoma were identified.

Routine sections were taken, stained by AgNOR method, and the mean number of AgNOR dots was calculated. Materials required for AgNOR staining include silver nitrate, gelatin, formic acid, and distilled water.

The method of AgNOR staining is as follows.

- 1) 3-4 micron thick sections of paraffin-embedded tissue are taken.
- 2) Sections are dewaxed in xylene and hydrated through ethanol to water solutions.
- 3) Then they are incubated in freshly prepared solution for 45 minutes at room temperature, washed in distilled water for 1 minute, and dehydrated and mounted.

After this treatment, NORs are visualized as distinct black intranuclear dots that stain orange to brown.

In each specimen, 50 nuclei were examined using a 100× oil immersion lens and the mean number of AgNOR dots per cell was calculated. Only the nuclei of prostatic glands were examined and cells were selected randomly.

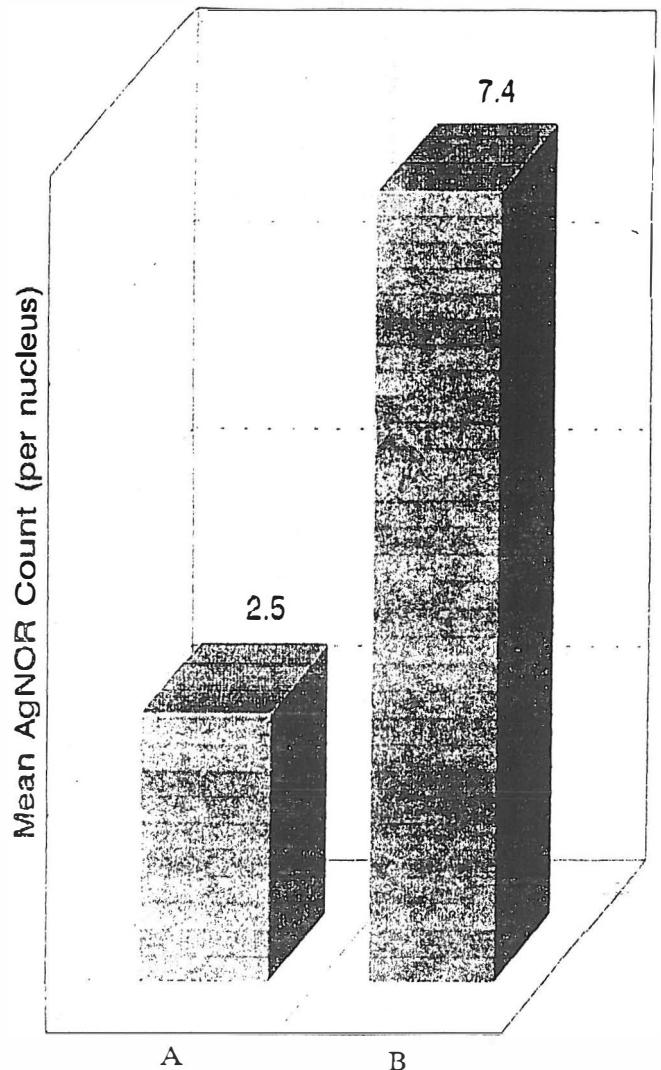


Fig. 1. Mean AgNOR counts in benign and malignant prostatic lesions.

A) Benign prostatic hyperplasia

B) Prostatic adenocarcinoma (regardless of differentiation).

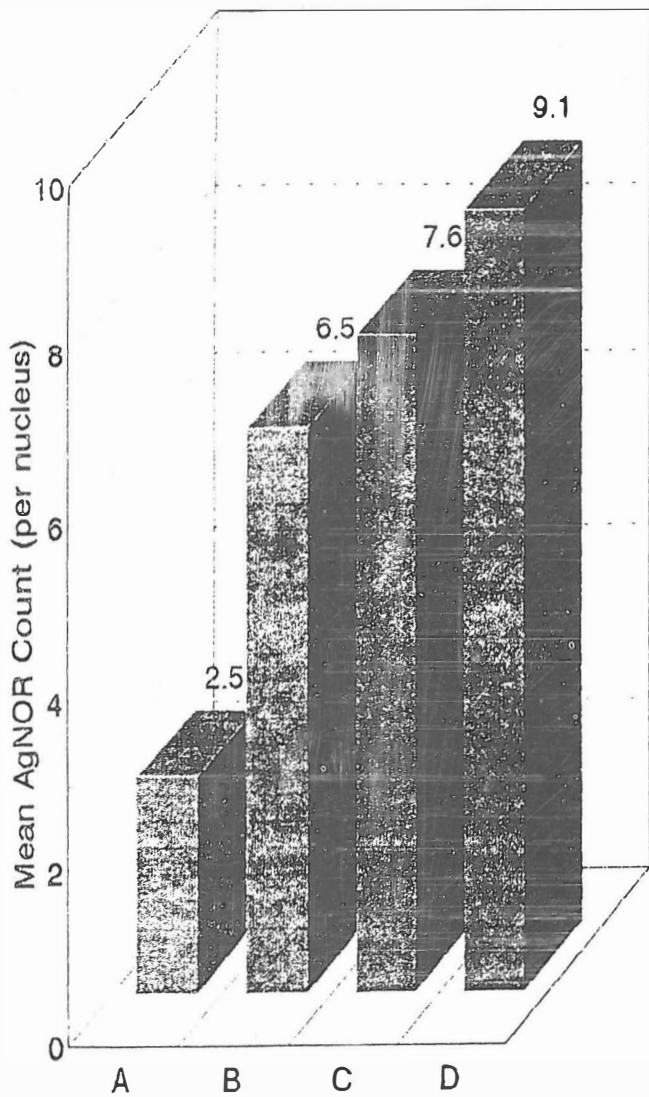


Fig. 2. Mean AgNOR counts in benign prostatic hyperplasia and prostatic adenocarcinoma.

- A) Benign prostatic hyperplasia (BPH)
- B) Well-differentiated adenocarcinoma
- C) Moderately-differentiated adenocarcinoma
- D) Poorly-differentiated adenocarcinoma.

The smears were carefully screened for correct counting of all AgNORs in each nucleus. A fine background precipitate of silver was seen in some sections but was easily distinguished from AgNORs by its random distribution and smaller size.

### RESULTS

The mean AgNOR counts per nucleus in different lesions was as follows (Table I):

- BPH: 2.5/nucleus (range: 2-3) (Fig. 4).
- Well-differentiated adenocarcinoma: 6.5/nucleus




Fig. 3. Range of AgNOR counts in BPH and three groups of prostatic adenocarcinoma.

- A) Benign prostatic hyperplasia (BPH)
- B) Well-differentiated adenocarcinoma
- C) Moderately-differentiated adenocarcinoma
- D) Poorly-differentiated adenocarcinoma

\* Note the overlapping of the range of AgNOR counts between the three adenocarcinoma groups.

(range: 5.2-7.3) (Fig. 5).

-Moderately-differentiated adenocarcinoma: 7.6/nucleus (range: 6.4-9.7) (Fig. 6).

-Poorly-differentiated adenocarcinoma: 9.1/nucleus (range: 7.4-10.9) (Fig. 7).

-Adenocarcinoma of the prostate regardless of differentiation: 7.4/nucleus.

There was no overlap of mean AgNOR counts per lesion between carcinoma and prostatic hyperplasia (Figs. 1,2) but the range of AgNOR counts in the three groups of carcinoma showed overlapping (Fig. 3).

### DISCUSSION

Prostatic cancer is one of the most common malignancies in males. As the population grows older, the rate of cancer of the prostate and prostatic hyperplasia increases. In prostatectomy specimens submitted as prostatic

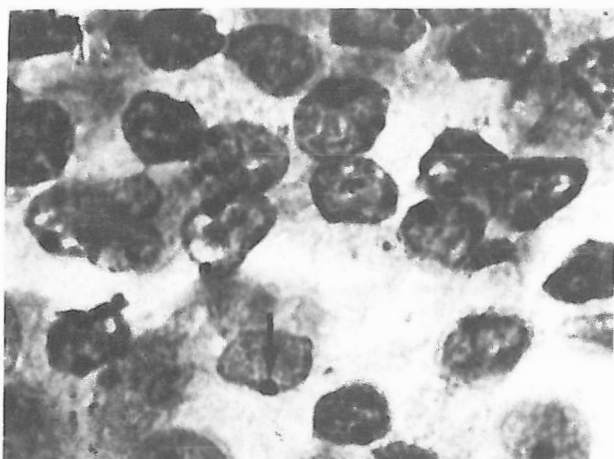


Fig. 4. BPH, AgNOR stain ( $\times 900$ ). The AgNORs are single, well defined, black intranucleolar dots (arrow).

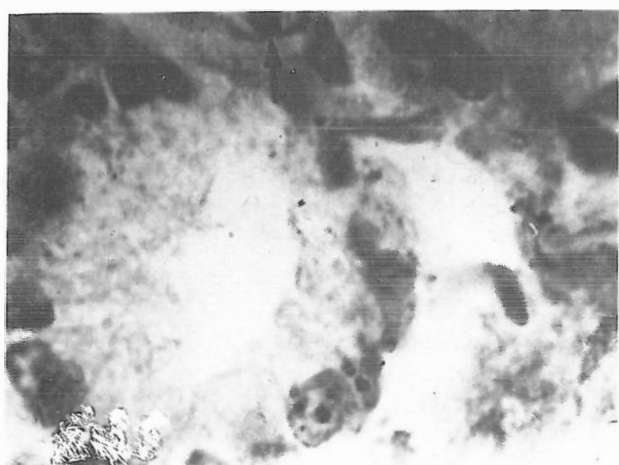

Fig. 5. Well-differentiated adenocarcinoma. AgNOR stain ( $\times 900$ ). The AgNOR dots are few, well defined and small (arrow).

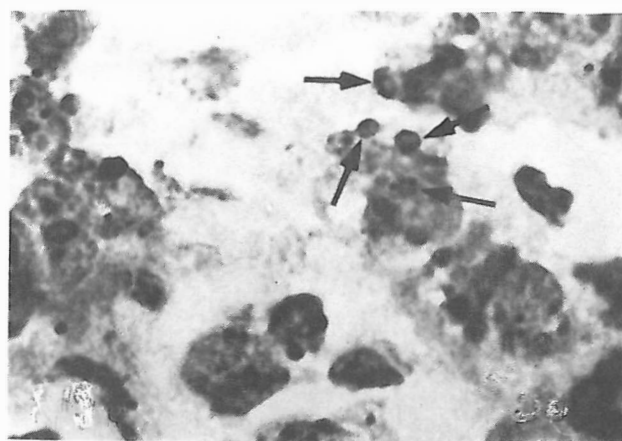


Fig. 6. Moderately-differentiated adenocarcinoma. AgNOR stain ( $\times 900$ ). The AgNOR dots are multiple, small and irregular (arrows).

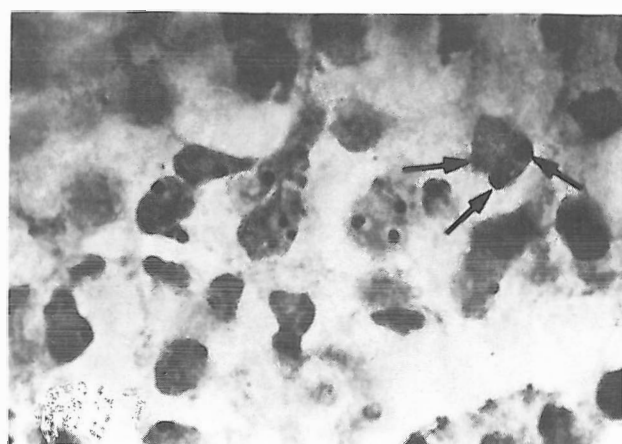


Fig. 7. Poorly differentiated adenocarcinoma. AgNOR stain ( $\times 900$ ). The AgNOR dots are multiple, small and irregular (arrows).

hyperplasia, microscopic foci of prostatic cancer are sometimes incidentally discovered. Sometimes it becomes difficult to distinguish prostatic hyperplasia from prostatic adenocarcinoma, especially well-differentiated forms. Therefore, diagnostic tools are necessary for early detection of prostatic carcinoma and differentiation between malignant and benign prostate lesions.

Silver staining of nucleolar organizer regions (AgNOR) is one of these techniques that can help to diagnose prostatic cancer and be useful to distinguish between benign and malignant prostatic lesions.<sup>6,8,10</sup>

NORs are DNA loops encoding ribosomal RNA production. AgNOR numbers correlate with growth fraction and may have diagnostic utility in human tumors.<sup>8</sup> AgNOR will be visualized as black satellites within the cell nucleus.

The number of detectable AgNOR within a nucleus depends upon:

1) the level of transcriptional activity,

2) the number of AgNOR bearing chromosomes, and  
3) the stage of cell cycle (the nucleolus disperses before mitotic division and is reorganized afterwards).<sup>8</sup>

However, AgNOR in normal cells are usually tightly aggregated within one or two nucleoli, making individual AgNOR indiscernible. An increase in the mean AgNOR count of a cell population could take place if:

1) cell proliferation is so active that nucleolar disaggregation is present in many cells, increasing individual AgNOR detection;

2) there is a defect of nucleolar association resulting in AgNOR dispersion;

3) cell ploidy increases, resulting in a real increase of AgNOR bearing chromosomes; or

4) transcriptional activity increases, resulting in prominence of otherwise inconspicuous AgNOR.<sup>8</sup>

Theoretically, neoplastic cell populations could show any or all of the above defects and therefore demonstrate

increased AgNOR counts.<sup>8</sup>

The studies on many types of malignancies confirmed this theory. For example, studies on breast cancer suggest that AgNOR not only helps diagnose breast cancer, but also can be a useful tool for predicting the prognosis; the higher the numbers and the more bizarre the morphology of AgNOR in the primary tumor, the more extensive the nodal disease and the worse the prognosis.<sup>20</sup> This method has also been used for differentiating benign from malignant lesions, for example malignant melanoma from melanocytic nevi,<sup>12</sup> hyperplastic endometrium from neoplastic endometrium,<sup>3</sup> and benign lesions from malignant tumors of the colon.<sup>22</sup> All of these studies showed that AgNOR numbers were much greater in malignant lesions than benign lesions.<sup>3,12,22</sup>

Studies on prostatic lesions showed a significant difference in AgNOR numbers between prostatic hyperplasia and prostatic cancer and confirmed the role of this method in diagnosis of these two groups.

One study on prostate cytology suggested that AgNOR analysis improves the differentiation between malignant and benign prostatic cells,<sup>2</sup> but a few papers have shown that there is considerable overlap in AgNOR counting and therefore AgNOR counts are not useful for diagnosis of hyperplastic and neoplastic prostatic lesions.<sup>1,5,9,14,18</sup>

AgNOR stain is also used for distinction between highly malignant and less malignant forms of prostatic carcinoma. Some researchers have found that AgNOR counts correlate significantly with the tumor's Gleason score, and have concluded that the AgNOR count may be used as a marker of tumor differentiation.<sup>13,17</sup>

The role of AgNOR in prognosis of prostatic carcinoma is controversial. Some studies showed that AgNOR may be useful for determining the prognosis of prostatic carcinoma,<sup>2,8,10,11,17</sup> while others report no prognostic value.<sup>1,6,7,9,19</sup>

One report has shown a decrease in the AgNOR number in prostatic cancer of experimental animals after treatment.<sup>21</sup> In our study, the AgNOR counts in prostatic adenocarcinoma were much greater than prostatic hyperplasia (Fig. 1). Also, the mean AgNOR count in poorly differentiated adenocarcinoma of the prostate was higher than moderate and well-differentiated forms (Fig. 2). These were compatible with the results of other studies.

The range of AgNOR count in the three groups of prostatic adenocarcinoma showed overlapping in our study (Fig. 3). This overlap has also been shown in a few other studies.<sup>5,14,18</sup>

The role of AgNOR counts in the prognosis of prostatic adenocarcinoma was not evaluated in our study, because there was no follow-up examination of the patients.

As mentioned earlier, AgNOR numbers correlate with growth fraction and may be a potential indicator of cellular proliferation and possibly a marker for tumor differentiation.

Studies on prostatic lesions and other tumors have

confirmed this. Therefore, the AgNOR method may be a simple and inexpensive technique for distinguishing between benign and malignant lesions of the prostate and for determining the grade of differentiation of prostatic adenocarcinoma.

## REFERENCES

1. Ahiskali R, Alican Y, Ekicioglu G, Cevik L, Kullu S, Akdas A: Evaluation of three different AgNOR counting methods in advanced carcinoma of prostate. *Prostate* 26 (2): 105-10, 1995.
2. Bittinger A, Von-keitz A, Ruschoff J, Melekos M: Silver staining nucleolar organizer region in prostate cytology. *Zentralbl-Pathology* 140 (1): 103-6, 1994.
3. Brustmann H, Riss P, Naude S: Nucleolar organizer regions as markers of endometrial proliferation: a study of normal, hyperplastic and neoplastic tissue. *Human Pathology* 26 (6): 664-7, 1995.
4. Bharucha H, McCluggage G, Lee J, Bannister W, Wilhelm F, Nelson A: Grading cervical dysplasia with AgNORs using a semiautomated image analysis system. *Analytical and Quantitative Cytology and Histology* 15 (5): 323-8, 1993.
5. Cheville JC, Clamon GH, Robinson RA: Silver-stained nucleolar organizer regions in the differentiation of prostatic hyperplasia, intraepithelial neoplasia and adenocarcinoma. *Modern Pathology* 3 (5): 596-8, 1990.
6. Contractor H, Ruschoff J, Hanisch T, Ulshofer B, Neumann K, Schultze-Seemann W, Thomas C: Silver-stained structures in prostatic carcinoma: evaluation of diagnostic and prognostic relevance by automated image analysis. *Urologia Internationalis* 46 (1): 9-14, 1991.
7. Cohen RJ, Glezeron G, Haffeeje Z, Afrika D: Prostatic carcinoma: histological and immunological factors affecting prognosis. *British Journal of Urology* 66: 405-10, 1990.
8. Deschenes J, Weidner N: Nucleolar organizer regions (NOR) in hyperplastic and neoplastic prostatic disease. *The American Journal of Surgical Pathology* 14 (12): 1148-55, 1990.
9. Hansen AB, Ostergard B: Nucleolar organizer regions in hyperplastic and neoplastic prostatic tissue. *Virchows Archives-A Pathological Anatomy and Histopathology* 417 (1): 9-13, 1990.
10. Kawase N, Shiokawa A, Ota H, Saitoh T, Yoshida H, Kazama K: Nucleolar organizer regions and PCNA expression in prostatic cancer. *Pathology International* 44 (3): 213-22, 1994.
11. Lardennois B, Vazenx H, Menu G, Visseaux B, Ploton D, Adent JJ: Nucleolar organizers: NOR. New prognostic factors in prostatic cancer. Preliminary results in 20 cases. *Annales D Urologie-Paris* 24 (5): 400-7, 1990.
12. Leong ASY, Gilham P: Silver staining of nucleolar

- organizer regions in malignant melanoma and melanocytic nevi. *Human Pathology* 20 (3): 257-62, 1989.
13. Lundgren R: Cytogenetic studies of prostatic cancers. *Scandinavian Journal of Urology and Nephrology* 136 (suppl): 1-35, 1991.
  14. Mamaeva S, Lundgren R, Elfving P, Limon J, Mondahl N, Mamaeva N, Henrikson H, Heim S, Mitelman F: AgNOR staining in benign hyperplasia and carcinoma of prostate. *Prostate* 18 (2): 155-62, 1991.
  15. Manakata S, Hendricks JB: Morphometric analysis of AgNORs in imprints and sections from non-Hodgkin's lymphoma. An approach to standardization. *Analytical and Quantitative Cytology and Histology* 15 (5): 329-34, 1993.
  16. Nakamura S, Takeda Y, Okabe Y, Yoshida T, Ohtake S, Kobayashi K, Kanno M, Matasuda T: Argyrophilic proteins of the nucleolar organizer region in acute leukemia: its relation to the S phase fraction of leukemia cells. *Acta Haematologica* 87: 6-10, 1992.
  17. Sakr WA, Sarkar FH, Sreepathi P, Drozdowicz S, Crissman JD: Measurement of cellular proliferation in human prostate by AgNOR, PCNA and SPF. *Prostate* 22(2): 147-54, 1993.
  18. Schneid AR: Nucleolar organizer regions as discriminators for the diagnosis of well differentiated adenocarcinoma of prostate. *Archives of Pathology and Laboratory Medicine* 117 (10): 1000-4, 1993.
  19. Schoedel KE, Martinez AJ, Mahoney TM, Contis L, Becich MJ: Chordomas, pathological features, ploidy and silver nucleolar organizer region analysis. A study of 36 cases. *Acta Neurologica Berlin* 89 (2): 132-43, 1995.
  20. Sivtidis E, Sims B: Nucleolar organizer regions : new prognostic variable in breast carcinomas. *Journal of Clinical Pathology* 43: 390-92, 1990.
  21. Szepeshazi K, Korkut E, Schally AV: Decrease in the AgNOR number in Dunning R3327 prostate cancer after treatment with an agonist and antagonist of luteinizing hormone-releasing hormone. *American Journal of Pathology* 138 (5): 1273-7, 1991.
  22. Yang P, Huang GC, Zhu XS: Role of nucleolar organizer regions in differentiation of malignant from benign tumors of the colon. *Journal of Clinical Pathology* 43: 235-38, 1990.