

EVALUATION OF A NEW TECHNIQUE OF ANASTOMOSIS IN THE MODIFIED DUHAMEL- MARTIN OPERATION FOR HIRSCHSPRUNG'S DISEASE

R. MOOSAVI, M.D. AND A. KALANTAR MOTAMEDI, M.D.

*From the Department of General and Vascular Surgery and Traumatology, Shohada Medical Center,
Shaheed Beheshti University of Medical Sciences, Tehran, I.R. Iran.*

ABSTRACT

Hirschsprung's disease, also known as congenital aganglionic megacolon, is a congenital disorder which develops due to an absence of neural ganglia in a segment of large bowel. Most commonly, the rectum or rectosigmoid, and rarely other areas or the entire colon are involved.

In this disease, all three neural plexi, i.e., the myenteric (Auerbach's) plexus, the superficial submucosal (Meissner's) plexus and the deep submucosal (Henle's) plexus are affected, therefore peristaltic waves do not occur in involved portions of the bowel. This causes a relative stenosis in involved areas and dilatation of the pre-stenotic bowel with resulting chronic constipation, recurrent diarrhea, and multiple episodes of enterocolitis. This series of events eventually leads to severe weakness, failure to thrive, abdominal distention and death.

The only correct and effective form of therapy for this disorder is surgery. Surgical treatment can be performed by various methods, such as that proposed by Swenson et al,¹¹ Soave,⁹ Duhamel,² and Rehbein and Martin.⁴ Studies have shown that Martin's method has several advantages compared to other forms of surgical therapy. These are:

- 1/ Sensation is spared throughout the entire rectum.
- 2/ No dissection is performed anteriorly.
- 3/ Intraoperative bleeding is less.
- 4/ No catheter is required postoperatively.

The modified Duhamel-Martin procedure which is the subject of this study has some practical benefits and less complications compared to the traditional Martin operation and is therefore our recommended technique for the treatment of Hirschsprung's disease.

MJIRI, Vol. 12, No. 3, 225-228, 1998

INTRODUCTION

Hirschsprung's disease is a congenital disorder which involves mainly the terminal colon and rectum and causes

delayed passage of meconium in the newborn period.

The prevalence of this disorder is 1 per 5000 live births and the male to female ratio is 3.9 to 1.^{8,12} Current therapy, after diagnosis of the disease with biopsy in the newborn

period, includes construction of a colostomy, followed one year later (or 3-6 months later in older children) by a definitive pull-through procedure.⁶ In recent years some researchers have performed the pull-through procedure in infants without performing a prior colostomy.^{1,3,10}

Each of the above mentioned methods have different complications, such as:

1. Postoperative enterocolitis, the risk of which is greatest following Soave's procedure.
2. Obstruction of the portion of bowel distal to the performed anastomosis in Swenson's procedure, due to sparing of a small portion of the aganglionic rectum.⁵
3. Accumulation of fecal material in the aganglionic portion of bowel immediately proximal to the anastomosis in Duhamel's operation.

In order to prevent such complications, several actions have been proposed. For example in Martin's procedure, in order to prevent the above mentioned complication concerning Duhamel's operation, anterior and posterior walls are anastomosed via a perineal approach with a stapler. In our recommended method, staplers are not used, a perineal approach is not undertaken, and a longitudinal incision is applied instead of a transverse incision. We have named such an operation the "modified Duhamel-Martin procedure". The disadvantages of this operation include technical difficulties in the pelvic area, especially in one year old infants, concerning visibility, applying ligatures, and the risk of anastomotic leak.

In order to decrease the risk of such complications, several safety measures are undertaken which will be discussed later.

In this study, children with Hirschsprung's disease referring to the Shohada Medical Center, Tehran were treated according to the modified Martin-Duhamel procedure, and results and complications will be reported.

PATIENTS AND METHODS

In this study, all patients referring to the Shohada Medical Center with a definite diagnosis of Hirschsprung's disease during an eight year period (1987-1994) were included. A total of 20 patients were evaluated in this quasi-experimental study. Among newborn infants, cases would be diagnosed following failure to pass meconium or delayed passage after 24-48 hours, abdominal distention and a rectal exam revealing an empty rectal ampulla followed by minimal passage of gas or meconium upon withdrawal of the examining finger.

The disorder would be diagnosed in infants and older children with abdominal distention, chronic constipation, and an empty rectal ampulla upon rectal examination.

In newborns the first measure was to perform a transverse loop colostomy. Afterwards parents were

instructed to return one year later for definitive surgery (pull-through procedure) if their pathology results reported the presence of Hirschsprung's disease. In infants and older children, if the above mentioned manifestations were present, a barium enema was performed. If the results suggested Hirschsprung's disease, a full thickness rectal biopsy was obtained 1.5-2 cm above the dentate line. A pathology report indicating an absence of neural ganglia in the biopsy specimen would confirm the diagnosis and a loop colostomy would be performed. In such patients a pull-through operation was performed 3-6 months after colostomy construction.

Operative technique

All patients had a colostomy constructed. The area and length of the colon which was exteriorized depended on the location of aganglionic bowel. Ideally, the colostomy must be positioned such that the main operation can be easily performed at a later date without requiring to close the colostomy at that time. If the aganglionic segment was short a right transverse colostomy would be constructed. If the aganglionic segment was radiographically determined to reside in the region of the splenic flexure, the colostomy would be situated immediately proximal to the transitional zone.

After the required time period had elapsed the patients would undergo bowel preparation and a Foley catheter would be inserted. Via a lower midline incision the abdomen would be explored and the colon and rectum evaluated. A small portion of bowel proximal to the transitional zone would be marked and a biopsy specimen sent to the pathology laboratory in order to determine the presence or absence of neural ganglia. If the biopsy report revealed the presence of sufficient numbers of ganglion cells, the pull-through procedure would be performed accordingly.

In the initial part of the operation, the posterior rectum is mobilized from the presacral fascia until the perineum is reached. At this stage the proximal colon which harbors a sufficient number of neural ganglia is evaluated to see whether its blood supply is adequate, and the rectum is transected at the peritoneal reflection. The aganglionic bowel is transected at this level and removed. Next, a vertical incision is made through the length of the rectum beginning from above the dentate line and in the posterior aspect. The rectum can now be opened similar to an open book.

The ganglion-containing proximal end of the colon is now cut obliquely and fashioned to resemble the tip of a fountain pen. An anastomosis is now performed with 3/0 silk in a one-layer Gambee method between the proximal colon and the posterior rectum using the parachute technique (Fig. 1, A-C).

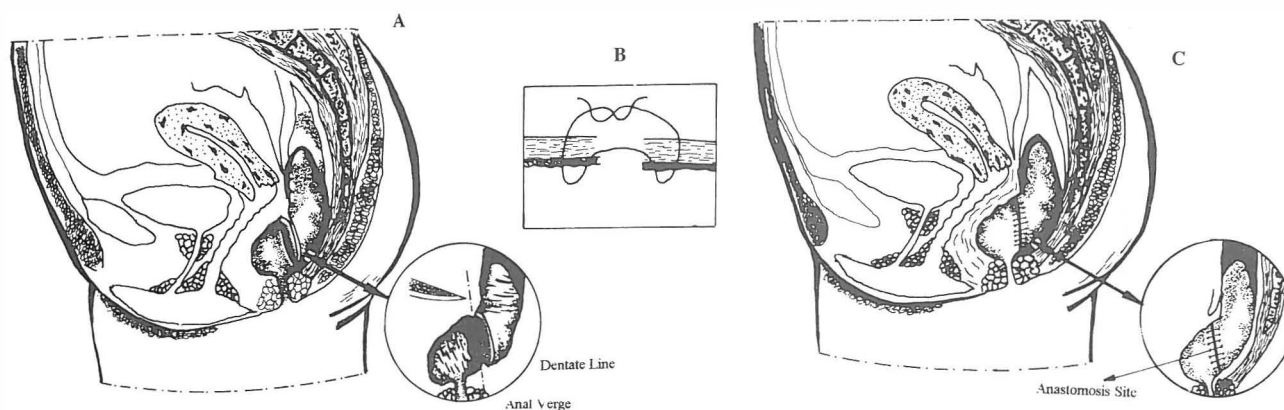


Fig. 1. A. Level of distal (aganglionic rectum) and proximal (ganglionic colon) anastomosis. B. Gambee method. C. The completed anastomosis.

Follow up

The mean period of hospitalization postoperatively was one week. Closure of the colostomy was performed 1.5 to 2 months after the pull-through operation in all patients.

Patients were followed for 1-12 months (mean 3.5 months) after colostomy closure, and all follow up examinations and evaluations were performed by the chief resident of surgery at that time. Factors which were evaluated during this period included correction of bowel habit and pattern, and correction of constipation, malnutrition and failure to thrive.

RESULTS

This study was performed on 20 patients, 15 male (75%) and 5 female (25%). Four patients were less than 1 year old, 5 were between 5-11 years of age and 5 patients were above 11 years of age.

Clinical manifestations such as abdominal distention and constipation were present in one-half of cases, and diarrhea, restlessness, malaise, lethargy, anorexia and bilious vomiting was seen in 25% of patients. Two patients (10%) had enterocolitis. Concerning the area of involvement, the rectosigmoid was involved in 60%, a short segment in 20% and a long segment in 15% of patients.

Patients were followed for a mean period of 3.5 months, and results were positive in 88% of cases, i.e., bowel habits normalized while constipation, diarrhea, and fecal incontinence were seen in only 12% of cases. Early infectious complications such as wound infection and pelvic abscess formation were seen in 12% of patients. Other early complications including bowel obstruction and wound dehiscence in the area of colostomy closure were again seen in 12% of patients and, concerning late complications, we had one case of anastomotic stricture

which caused fecal soiling. We had no mortality due to operation.

DISCUSSION

Swenson and co-workers performed a large scale study on 483 patients with Hirschsprung's disease in the United States and reported a male/female ratio of 3/1. In a study performed on 65 such patients during 1951-1981, Crom et al. reported a M/F ratio of 1.8 to 1. A further study by Rowshan-Zamir et al. in Medical Centers affiliated to the Shaheed Beheshti University of Medical Sciences reported 73% of patients to be male and 27% as female, which is in accordance with the afore-mentioned 3 to 1 ratio.

In our study, abdominal distention and chronic constipation was present in 100% of patients. These symptoms are reported in all textbooks as constant findings of this disorder. Failure to thrive was seen in one-half of the study group. This has also been reported to be a constant finding.⁷ Diarrhea, restlessness, anorexia and bilious vomiting were seen in 25% of our patients; these findings are usually categorized as mild symptoms.¹³ Two patients (10%) presented with enterocolitis, a complication which Weitzman reported in 17%, Swenson reported in 16.4% and Martin reported in 20% of their patients.⁴ Our study revealed a correction of bowel pattern/habits in 88% of patients, a value which is in accordance to that reported by Swenson (90%). Weitzman, after treating his group of patients with Swenson's procedure, also reported a 90% value of normal bowel habits postoperatively. In 1985 Martin compared the results of various pull-through procedures and found no statistically significant difference concerning results and/or complications. 12% of patients in our study suffered from early complications, such as wound infection and pelvic abscess. Such complications were reported in 16% of patients in another study performed

in a different medical center after Swenson's procedure.

Considering the above and after comparing our modified approach with other conventional pull-through procedures, our approach appears to have the following advantages:

1. By deleting the perineal approach, the patient only undergoes a laparotomy.

2. This procedure can be performed in situations in which a stapler is not at hand or is inaccessible.

3. Complications which are commonly seen in Martin's procedure—such as bleeding from the transected edges cut by the stapler—are thus prevented.

In general, all of the advantages of Martin's procedure pertain to our method as well. These include, A) retained rectal sensation (which is due to preservation of the anterior rectal wall which makes up one-half of the newly formed rectum), B) Prevention of tissue dissection anterior to the rectum, thus preventing damage to the bladder's nerve supply and the ejaculatory ducts in males, C) Intraoperative bleeding is as slight as possible, thus preventing blood transfusion and its attendant side effects, and D) The number of ganglion cells present in half of the newly devised rectum are sufficient for defecation, and catheter placement is rarely required in this method of operation.

REFERENCES

1. Carcassone M, Guis J, et al: Management of Hirschsprung's disease: curative surgery before three months of age. *J Pediatric Surg* 24: 1032, 1989.
2. Duhamel B: Retrorectal and trans-anal pull-through procedure for the treatment of Hirschsprung's disease. *Dis Colon Rectum* 7: 455, 1964.
3. Boley SJ, Lafer DJ, et al: Endorectal pull-through procedure for Hirschsprung's disease with and without primary anastomosis. *J Pediatric Surgery* 3: 258, 1968.
4. Martin LW: Hirschsprung's disease. *The Surgical Clinics of North America*, October 1985.
5. Eichelberger MR, Salzberg AM, Randolph JG: Hirschsprung's Disease. In: Greenfield LJ (ed.), *Complications in Surgery and Trauma*. Philadelphia: J.B. Lippincott Co., pp. 533-4, 1990.
6. Guzzetta PC, Anderson KD, et al: Hirschsprung's Disease. In: Schwartz SI, Shires GT, Spencer FC, (eds.), *Principles of Surgery*. Sixth ed, New York: McGraw-Hill Co., p. 1702, 1994.
7. Fonkalsrud EW: Hirschsprung's Disease. In: Zinner MJ, Schwartz SI, Ellis H, (eds.), *Maingot's Abdominal Operations*. Tenth ed, London: Prentice Hall International, pp. 2097-2105, 1997.
8. Sherman JO, Snyder ME, et al: A 40 year multinational retrospective study of 880 Swenson procedures. *J Pediatr Surg* 24: 833, 1989.
9. Soave F: Hirschsprung's disease: clinical evaluation and details of a personal technique. *Z Kinderchir (suppl)* 3: 66, 1966.
10. So HB, Schwartz DL, Bocker JM, et al: Endorectal pull-through without preliminary colostomy in neonates with Hirschsprung's disease. *J Pediatric Surg* 15: 470, 1980.
11. Swenson O, Sherman JO, Fisher JH, et al: The treatment of postoperative complications of congenital megacolon: a 25 year follow-up. *Ann Surg* 182: 266, 1975.
12. Swenson O, Sherman JO, Fisher JH: Diagnosis of congenital megacolon: an analysis of 501 patients. *J Pediatric Surg* 8: 587, 1973.